A 51-year-old woman comes to the office due to progressively worsening fatigue, weight gain, and constipation for the past 6 months. The patient has had difficulty performing daily activities due to fatigue. She has no significant medical history and takes no medications. The patient has no drug allergies and does not use tobacco, alcohol, or illicit drugs. Blood pressure is 110/80 mm Hg and pulse is 55/min. Physical examination shows mild, diffuse enlargement of the thyroid gland. Cardiopulmonary and abdominal examinations are normal. Biopsy of this patient's thyroid is most likely to show which of the following findings?

A. Branching papillae with cells containing empty-appearing nuclei

B. Dense fibrous tissue extending beyond the thyroid capsule

C. Follicular hyperplasia with tall cells projecting into the follicular lumen

D. Intense lymphoplasmacytic infiltrate with active germinal centers

E. Widespread inflammatory infiltrates, giant cells, and disrupted follicles

Submit

A 51-year-old woman comes to the office due to progressively worsening fatigue, weight gain, and constipation for the past 6 months. The patient has had difficulty performing daily activities due to fatigue. She has no significant medical history and takes no medications. The patient has no drug allergies and does not use tobacco, alcohol, or illicit drugs. Blood pressure is 110/80 mm Hg and pulse is 55/min. Physical examination shows mild, diffuse enlargement of the thyroid gland. Cardiopulmonary and abdominal examinations are normal. Biopsy of this patient's thyroid is most likely to show which of the following findings?

- A. Branching papillae with cells containing empty-appearing nuclei (6%)
- B. Dense fibrous tissue extending beyond the thyroid capsule (5%)
- C. Follicular hyperplasia with tall cells projecting into the follicular lumen (10%)
- ✓ D. Intense lymphoplasmacytic infiltrate with active germinal centers (52%)
- E. Widespread inflammatory infiltrates, giant cells, and disrupted follicles (24%)

Omitted
Correct answer
D

52%
Answered correctly

05 secs
Time Spent

03/16/2020
Last Updated

Explanation

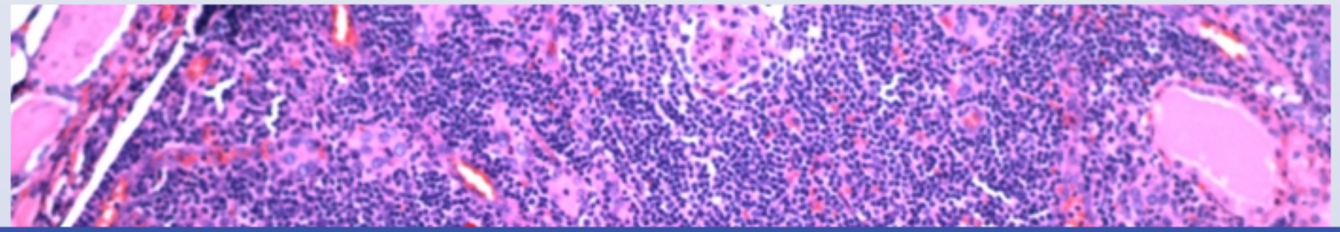

1
2
3
4
5
6
7
8
9
10
11
12
13
14
15
16
17
18
19
20
21
22
23
24
25
26
27
28
29
30
31

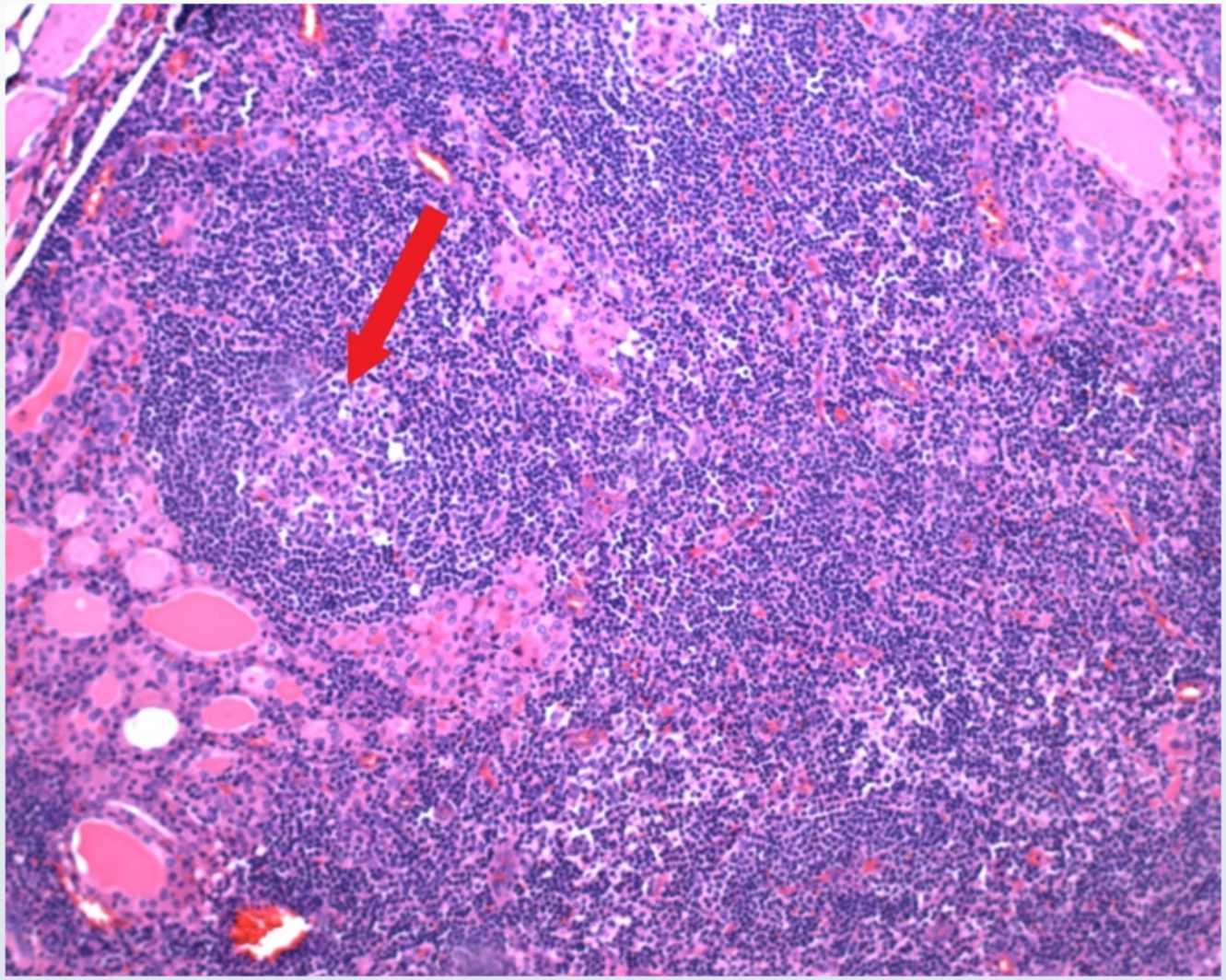

This patient has progressive symptoms of hypothyroidism (eg, fatigue, weight gain, constipation) and a diffuse goiter, consistent with **chronic lymphocytic (Hashimoto) thyroiditis**. This disease occurs predominately in women, with a peak incidence at age 45-65, and is the most common cause of hypothyroidism in iodine-sufficient regions such as the United States.

This patient has progressive symptoms of hypothyroidism (eg, fatigue, weight gain, constipation) and a diffuse goiter, consistent with **chronic lymphocytic (Hashimoto) thyroiditis**. This disease occurs predominately in women, with a peak incidence at age 45-65, and is the most common cause of hypothyroidism in iodine-sufficient regions such as the United States.

As with all forms of primary hypothyroidism, laboratory studies show low serum thyroxine (T4) levels and an elevated TSH. Elevated antithyroid peroxidase antibody levels can confirm the diagnosis. If the diagnosis is uncertain (eg, thyroid nodularity), a biopsy can be performed to rule out malignancy. Characteristic findings of Hashimoto thyroiditis include an intense **mononuclear infiltrate** consisting of **lymphocytes** and plasma cells, often with **germinal centers** (arrow in image above). Residual follicles are often surrounded by **Hürthle cells** (large oxyphilic cells filled with granular cytoplasm) that represent follicular epithelial cells that have undergone metaplastic change in response to inflammation.

**(Choice A)** Histopathology in papillary thyroid cancer shows branching papillary structures with concentric calcifications (psammoma bodies) and ground-glass or empty-appearing nuclei ("Orphan Annie eye" nuclei). However, papillary thyroid cancer typically presents as an enlarging nodule in a clinically euthyroid patient.

**(Choice B)** Riedel thyroiditis is characterized by extensive fibrosis of the thyroid gland extending into the surrounding structures. The fibrotic thyroid gland in Riedel thyroiditis is typically hard and fixed to surrounding structures, often resembling a malignancy.

**(Choice C)** Graves disease presents with a diffusely enlarged thyroid gland associated with hyperthyroidism, exophthalmos, and pretibial myxedema. The thyroid follicular epithelium is tall and crowded with hyperactive reabsorption, causing scalloping around the edges of the colloid. Follicular hyperplasia with elongated epithelial cells is also seen in the tall-cell variant of papillary thyroid cancer, typically presenting in older adults as an enlarging thyroid mass.

**(Choice E)** Subacute granulomatous (de Quervain) thyroiditis is characterized by disruption of follicles and a mixed cellular infiltrate with occasional multinuclear giant cells. Patients typically present after a viral upper respiratory infection with fever and a painful, tender thyroid gland.

**Educational objective:**
Chronic lymphocytic (Hashimoto) thyroiditis is the most common cause of hypothyroidism. Histopathology characteristically shows an intense lymphocytic infiltrate, often with germinal centers. Residual follicles may be surrounded by Hürthle cells (large oxyphilic cells filled with granular cytoplasm).

**References**

1
2
3
4
5
6
7
8
9
10
11
12
13
14
15
16
17
18
19
20
21
22
23
24
25
26
27
28
29
30
31

This patient has progressive symptoms of hypothyroidism (eg, fatigue, weight gain, constipation) and a diffuse goiter, consistent with **chronic**

Exhibit Display

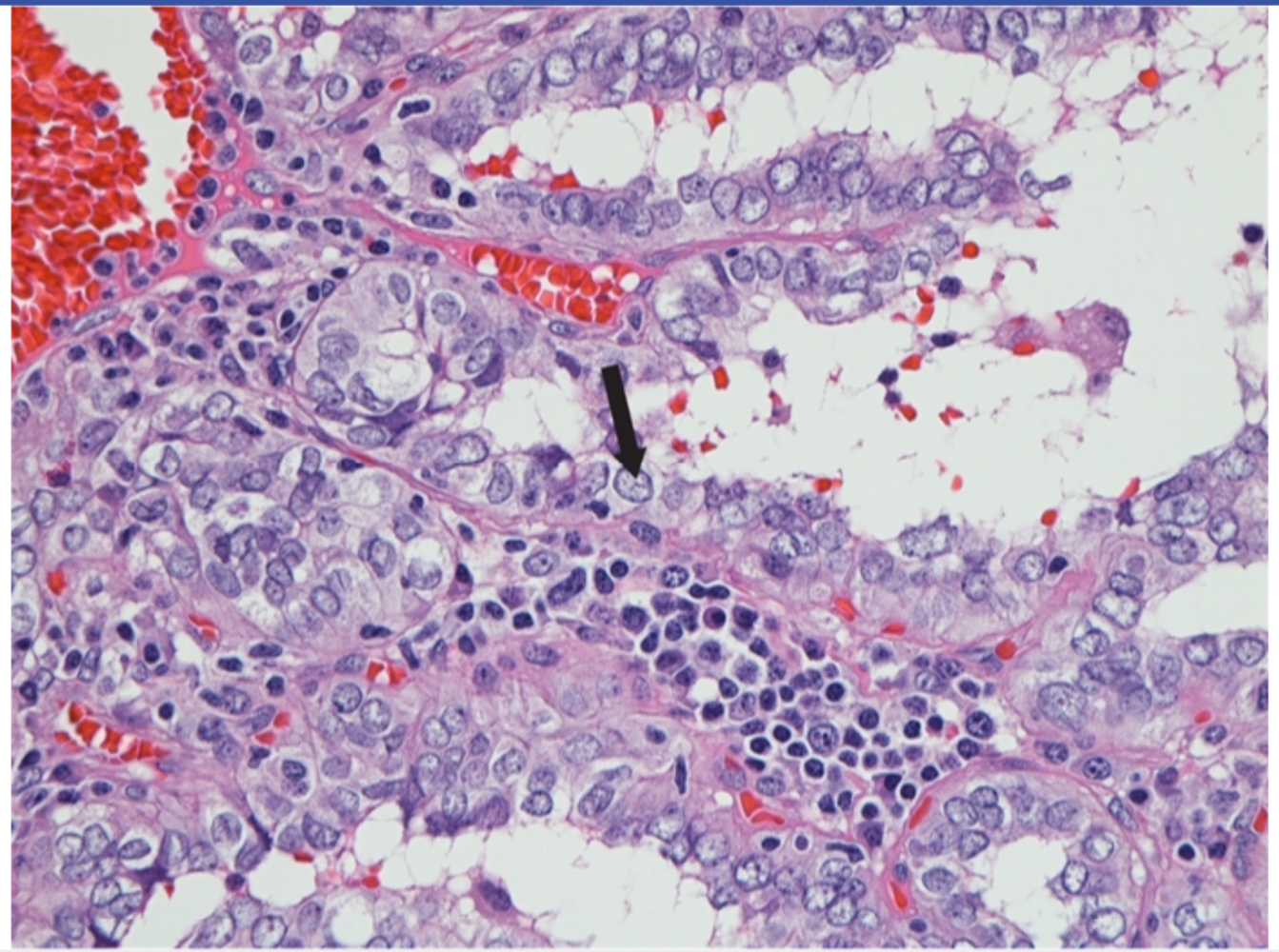

Zoom In | Zoom Out | Reset | Add To New Card | Existing Card

References

1
2
3
4
5
6
7
8
9
10
11
12
13
14
15
16
17
18
19
20
21
22
23
24
25
26
27
28
29
30
31

Exhibit Display

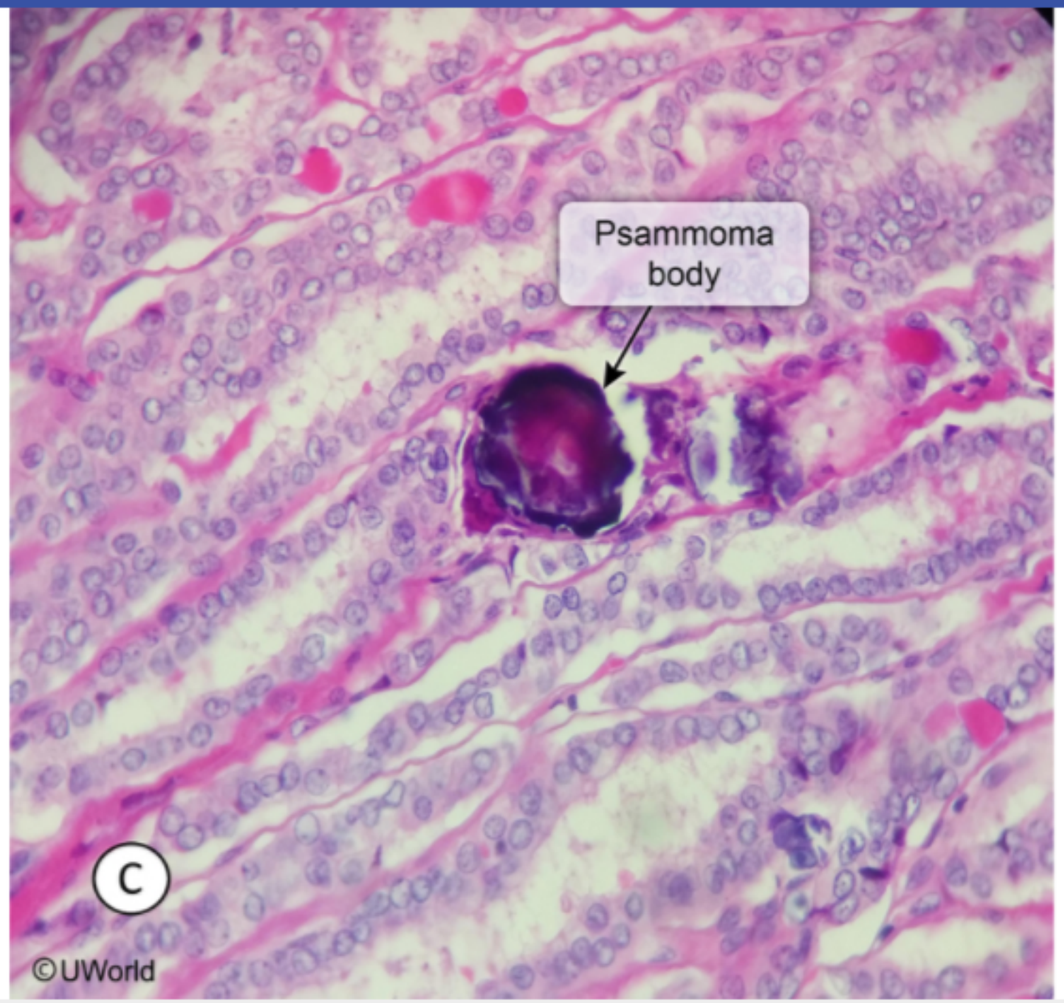


Zoom In | Zoom Out | Reset | Add To New Card | Existing Card

References

1
2
3
4
5
6
7
8
9
10
11
12
13
14
15
16
17
18
19
20
21
22
23
24
25
26
27
28
29
30
31

Exhibit Display

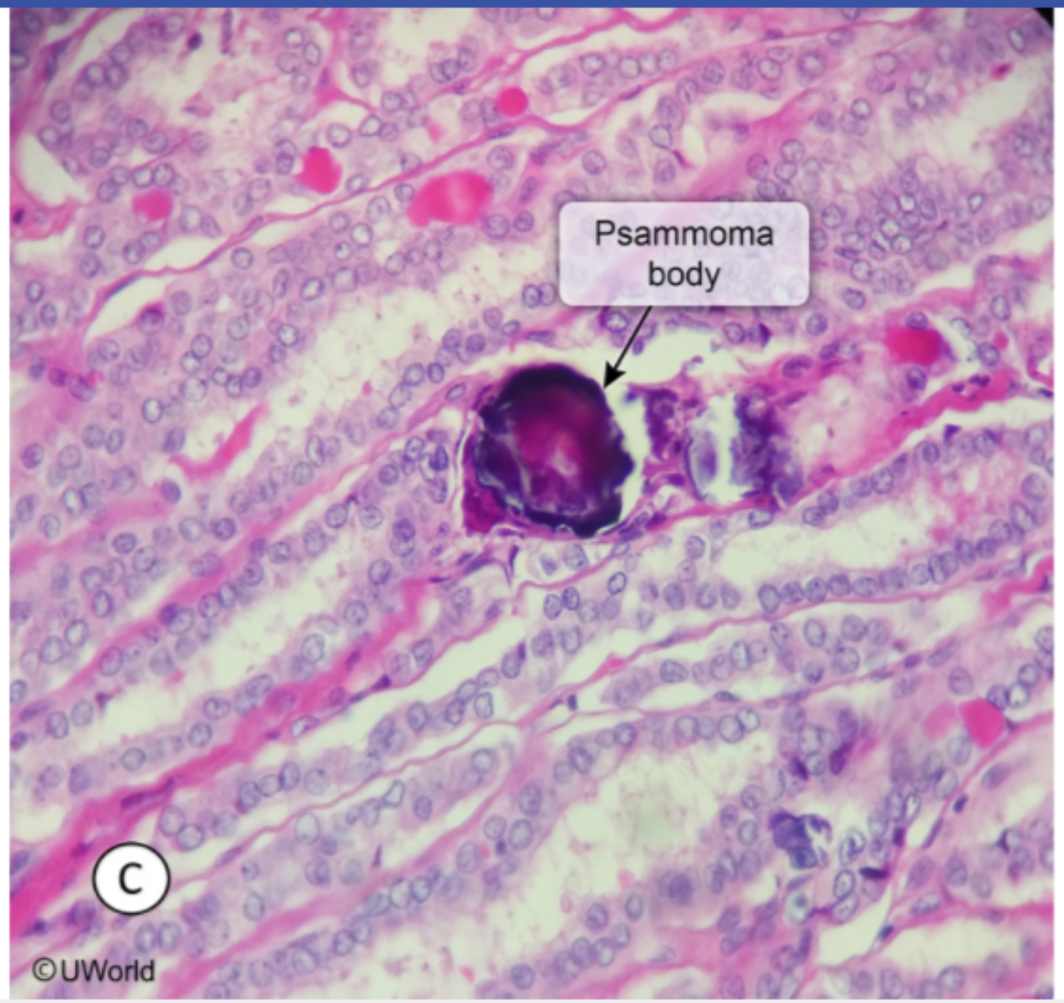


Zoom In | Zoom Out | Reset | Add To New Card | Existing Card

References

1
2
3
4
5
6
7
8
9
10
11
12
13
14
15
16
17
18
19
20
21
22
23
24
25
26
27
28
29
30
31

This patient has progressive symptoms of hypothyroidism (eg, fatigue, weight gain, constipation) and a diffuse goiter, consistent with **chronic**

Exhibit Display

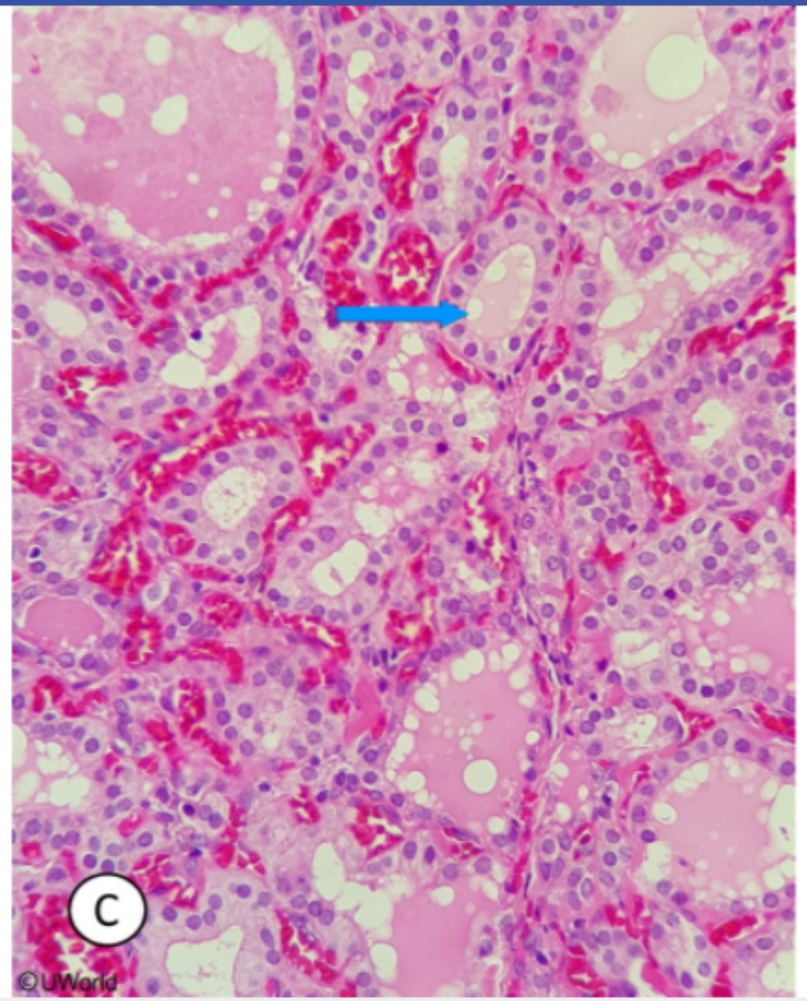


Zoom In | Zoom Out | Reset | Add To New Card | Existing Card

References

A 65-year-old man comes to the physician because of a non-healing ulcer on his right foot. His past medical history is significant for recurrent high blood glucose readings for the last several years, because he has failed to comply with appropriate treatment. His BMI is 37 kg/m$^2$. Physical examination is significant for a bilateral symmetric decrease in vibration sensation over the feet and ankles. Which of the following is most likely to be associated with this patient's condition?

A. Pancreatic islet infiltration with leukocytes

B. Pancreatic islet amyloid deposition

C. Circulating anti-islet antibodies

D. Strong linkage with HLA class II gene makeup

E. Episodic ketoacidosis that requires insulin therapy

Submit

A 65-year-old man comes to the physician because of a non-healing ulcer on his right foot. His past medical history is significant for recurrent high blood glucose readings for the last several years, because he has failed to comply with appropriate treatment. His BMI is 37 kg/m$^2$. Physical examination is significant for a bilateral symmetric decrease in vibration sensation over the feet and ankles. Which of the following is most likely to be associated with this patient's condition?

- A. Pancreatic islet infiltration with leukocytes (4%)
- ✓ B. Pancreatic islet amyloid deposition (67%)
- C. Circulating anti-islet antibodies (3%)
- D. Strong linkage with HLA class II gene makeup (16%)
- E. Episodic ketoacidosis that requires insulin therapy (7%)

Omitted
Correct answer
B

67%
Answered correctly

02 secs
Time Spent

05/04/2020
Last Updated

## Explanation

The patient described in this vignette has type 2 diabetes mellitus (advanced age, obesity, prolonged non-compliance with treatment without immediate life-threatening consequences). The two cardinal defects involved in the pathophysiology of type 2 diabetes mellitus are increased insulin resistance and defective insulin secretion. Although still controversial, many researchers believe that increased insulin resistance is the primary abnormality in type 2 diabetes mellitus. Early in the pathogenesis of type 2 diabetes, glucose tolerance is thought to remain normal because of a compensatory increase in insulin secretion from beta cells. This compensatory insulin response by beta cells ultimately fails, causing poor glucose tolerance. A number of genetic and acquired factors are implicated in the beta-cell dysregulation of type 2 diabetes. Islet

The patient described in this vignette has type 2 diabetes mellitus (advanced age, obesity, prolonged non-compliance with treatment without immediate life-threatening consequences). The two cardinal defects involved in the pathophysiology of type 2 diabetes mellitus are increased insulin resistance and defective insulin secretion. Although still controversial, many researchers believe that increased insulin resistance is the primary abnormality in type 2 diabetes mellitus. Early in the pathogenesis of type 2 diabetes, glucose tolerance is thought to remain normal because of a compensatory increase in insulin secretion from beta cells. This compensatory insulin response by beta cells ultimately fails, causing poor glucose tolerance. A number of genetic and acquired factors are implicated in the beta-cell dysregulation of type 2 diabetes. Islet amyloid polypeptide (amylin) is one factor thought to be responsible for this beta cell dysfunction. Amylin is stored in insulin secretory granules and is co-secreted with insulin from pancreatic beta cells. Deposits of amylin are universally seen in the pancreatic islets of patients with type 2 diabetes mellitus. Amylin may play a causative role in beta cell apoptosis and defective insulin secretion; however, this theory is still controversial.

Type 1 and type 2 diabetes mellitus have very strong genetic components. Twin studies have shown a concordance rate of 50% in identical twins for diabetes mellitus type 1, and around 80% for diabetes mellitus type 2. The genes involved in the pathogenesis of diabetes mellitus type 2 remain largely unknown. Gene polymorphism within the major histocompatibility complex contributes to type 1 diabetes mellitus disease in humans. HLA-DQ and -DR are the most important determinants of type 1 diabetes mellitus. In the general population, DR3 and DR4 are seen in approximately 40% of subjects; however, in patients with type 1 diabetes mellitus, DR3 and DR4 haplotypes are seen in more than 90% of subjects.

**(Choices A, C, D & E)** These are features of type 1 diabetes mellitus. Type 1 diabetes occurs when an autoimmune response is triggered by an environmental insult in genetically susceptible individuals. Patients with type 2 diabetes retain at least some beta cell function, but patients with type 1 diabetes mellitus develop absolute deficiency of insulin secondary to immune destruction of pancreatic beta cells. These patients need insulin for survival. Discontinuation of insulin treatment results in ketoacidosis.

**Educational objective:**

Pancreatic islet amyloid deposition is characteristic of type 2 diabetes mellitus. A strong linkage with HLA class II gene makeup, pancreatic islet infiltration with leukocytes (insulitis), and antibodies against islet antigens are frequently seen in type 1 diabetes.

**References**

- Evidence for proteotoxicity in beta cells in type 2 diabetes: toxic islet amyloid polypeptide oligomers form intracellularly in the secretory pathway.

because of a compensatory increase in insulin secretion from beta cells. This compensatory insulin response by beta cells ultimately fails, causing poor glucose tolerance. A number of genetic and acquired factors are implicated in the beta-cell dysregulation of type 2 diabetes. Islet amyloid polypeptide (amylin) is one factor thought to be responsible for this beta cell dysfunction. Amylin is stored in insulin secretory granules and is co-secreted with insulin from pancreatic beta cells. Deposits of amylin are universally seen in the pancreatic islets of patients with type 2 diabetes mellitus. Amylin may play a causative role in beta cell apoptosis and defective insulin secretion; however, this theory is still controversial.

Type 1 and type 2 diabetes mellitus have very strong genetic components. Twin studies have shown a concordance rate of 50% in identical twins for diabetes mellitus type 1, and around 80% for diabetes mellitus type 2. The genes involved in the pathogenesis of diabetes mellitus type 2 remain largely unknown. Gene polymorphism within the major histocompatibility complex contributes to type 1 diabetes mellitus disease in humans. HLA-DQ and -DR are the most important determinants of type 1 diabetes mellitus. In the general population, DR3 and DR4 are seen in approximately 40% of subjects; however, in patients with type 1 diabetes mellitus, DR3 and DR4 haplotypes are seen in more than 90% of subjects.

**(Choices A, C, D & E)** These are features of type 1 diabetes mellitus. Type 1 diabetes occurs when an autoimmune response is triggered by an environmental insult in genetically susceptible individuals. Patients with type 2 diabetes retain at least some beta cell function, but patients with type 1 diabetes mellitus develop absolute deficiency of insulin secondary to immune destruction of pancreatic beta cells. These patients need insulin for survival. Discontinuation of insulin treatment results in ketoacidosis.

**Educational objective:**
Pancreatic islet amyloid deposition is characteristic of type 2 diabetes mellitus. A strong linkage with HLA class II gene makeup, pancreatic islet infiltration with leukocytes (insulitis), and antibodies against islet antigens are frequently seen in type 1 diabetes.

**References**

- Evidence for proteotoxicity in beta cells in type 2 diabetes: toxic islet amyloid polypeptide oligomers form intracellularly in the secretory pathway.

| Pathology | Endocrine, Diabetes & Metabolism | Diabetes mellitus |
|---|---|---|
| Subject | System | Topic |

Copyright © UWorld. All rights reserved.

A 55-year-old man comes to the office to establish care after relocating to the area. The patient has a 6-year history of type 2 diabetes mellitus for which he takes metformin monotherapy. He feels well and has no other medical conditions. The patient does not use tobacco or alcohol. He consumes a balanced diet and jogs for 40 minutes every morning. Review of his blood glucose journal over the last few months shows fasting glucose levels of 150-180 mg/dL. Laboratory analysis shows a hemoglobin A1c level of 4%. Further evaluation with hemoglobin electrophoresis shows a hemoglobin A2 level of 7.5% (normal: 1.5%-3.5%). Which of the following is the most likely explanation for this patient's lower-than-expected hemoglobin A1c level?

- A. Beta-thalassemia minor
- B. Folate deficiency
- C. Iron deficiency
- D. Low erythropoietin
- E. Poor glycemic control
- F. Sickle cell trait

Submit

A 55-year-old man comes to the office to establish care after relocating to the area. The patient has a 6-year history of type 2 diabetes mellitus for which he takes metformin monotherapy. He feels well and has no other medical conditions. The patient does not use tobacco or alcohol. He consumes a balanced diet and jogs for 40 minutes every morning. Review of his blood glucose journal over the last few months shows fasting glucose levels of 150-180 mg/dL. Laboratory analysis shows a hemoglobin A1c level of 4%. Further evaluation with hemoglobin electrophoresis shows a hemoglobin A2 level of 7.5% (normal: 1.5%-3.5%). Which of the following is the most likely explanation for this patient's lower-than-expected hemoglobin A1c level?

- ✓ A. Beta-thalassemia minor (76%)
- B. Folate deficiency (1%)
- C. Iron deficiency (2%)
- D. Low erythropoietin (4%)
- E. Poor glycemic control (1%)
- F. Sickle cell trait (12%)

Omitted
Correct answer
A

76%
Answered correctly

02 secs
Time Spent

05/24/2020
Last Updated

Explanation

Hemoglobin A1c is produced by irreversible nonenzymatic glycosylation of the N-terminal of the hemoglobin molecule. The degree of glycosylation (ie, hemoglobin A1c level) directly correlates with average blood glucose levels over the life span of circulating erythrocytes, which is normally approximately 3 months. **Higher glucose levels** and **increased exposure time** of red cells to glucose **increase hemoglobin A1c**

Hemoglobin A1c is produced by irreversible nonenzymatic glycosylation of the N-terminal of the hemoglobin molecule. The degree of glycosylation (ie, hemoglobin A1c level) directly correlates with average blood glucose levels over the life span of circulating erythrocytes, which is normally approximately 3 months. **Higher glucose levels** and **increased exposure time** of red cells to glucose **increase hemoglobin A1c** values. As such, conditions that alter red blood cell survival time also affect hemoglobin A1c levels.

This patient has an elevated hemoglobin A2, which suggests comorbid **beta-thalassemia minor**. Hemoglobin A2 is elevated in beta-thalassemia to compensate for beta-globin–chain underproduction, but results in microcytic red cells that are prone to hemolysis. **Increased erythrocyte turnover** results in a **misleadingly low hemoglobin A1c level**. In such cases, measurement of glycated serum proteins (ie, fructosamine) is sometimes used to estimate glycemic control.

**(Choices B and C)** Deficiencies of iron, folate, and vitamin $B_{12}$ can reduce production of new red cells, leading to a preponderance of older erythrocytes and falsely elevated hemoglobin A1c. In contrast, treatment of vitamin deficiencies causes young red cells to be rapidly released into circulation, falsely lowering hemoglobin A1c.

**(Choice D)** Advanced diabetic nephropathy may cause reduced erythropoietin production. The resulting decrease in production of new red cells may lead to falsely high hemoglobin A1c (similar to nutrient deficiencies).

**(Choice E)** Chronically elevated blood glucose (ie, poor glycemic control) is the primary cause of increased hemoglobin A1c in patients with diabetes.

**(Choice F)** Sickle cell trait is characterized by heterozygous carriage of hemoglobin S. Some patients with sickle cell trait can have slightly reduced hemoglobin A1c level due to increased red cell turnover (homozygous individuals with sickle cell disease have rapid red cell turnover and very low A1c). However, hemoglobin A2 percentage remains near normal in patients with sickle cell mutations.

**Educational objective:**
Hemoglobin A1c is produced by nonenzymatic glycosylation of the hemoglobin molecule. A hemoglobin A1c assay provides an estimate of chronic glycemic control over the life span of circulating erythrocytes (~3 months). However, rapid erythrocyte turnover (eg, hemolytic anemia) can give a misleadingly low hemoglobin A1c in relation to glycemic status.

**References**

- Limitations of A1c interpretation.

Hemoglobin A1c is produced by irreversible nonenzymatic glycosylation of the N-terminal of the hemoglobin molecule. The degree of glycosylation (ie, hemoglo h is normally approximately 3 values. As such, conditio

This patient has an elevat mia to compensate for beta-gl **turnover** results in a **misl** sometimes used to estima

**(Choices B and C)** Defic erythrocytes and falsely el into circulation, falsely lowerin

**(Choice D)** Advanced dia ells may lead to falsely high h

**(Choice E)** Chronically el diabetes.

**(Choice F)** Sickle cell trai reduced hemoglobin A1c and very low A1c). However,

**Educational objective:**
Hemoglobin A1c is produc chronic glycemic control o can give a misleadingly low he

**References**

- Limitations of A1c interpretation.

**Exhibit Display**

| Hemoglobin electrophoresis patterns in sickle cell & beta-thalassemia | | | | |
|---|---|---|---|---|
| **Condition** | **Hemoglobin A** | **Hemoglobin A2** | **Hemoglobin F** | **Hemoglobin S** |
| **Normal** | 95%-98% | ~2.5% | <1% | Absent |
| **Beta-thalassemia minor** | ↓ | ↑ | Near normal | Absent |
| **Beta-thalassemia major** | Absent | ↑↑ | ↑↑ | Absent |
| **Sickle cell trait** | ↓↓ | Near normal | Near normal | ↑ |
| **Sickle cell disease** | Absent | Near normal | ↑↑ | ↑↑ |

Add To New Card | Existing Card

1
2
3
4
5
6
7
8
9
10
11
12
13
14
15
16
17
18
19
20
21
22
23
24
25
26
27
28
29
30
31

This patient has an elevated hemoglobin A2, which suggests comorbid **beta-thalassemia minor**. Hemoglobin A2 is elevated in beta-thalassemia to compensate for beta-globin–chain underproduction, but results in microcytic red cells that are prone to hemolysis. **Increased erythrocyte turnover** results in a **misleadingly low hemoglobin A1c level**. In such cases, measurement of glycated serum proteins (ie, fructosamine) is sometimes used to estimate glycemic control.

**(Choices B and C)** Deficiencies of iron, folate, and vitamin $B_{12}$ can reduce production of new red cells, leading to a preponderance of older erythrocytes and falsely elevated hemoglobin A1c. In contrast, treatment of vitamin deficiencies causes young red cells to be rapidly released into circulation, falsely lowering hemoglobin A1c.

**(Choice D)** Advanced diabetic nephropathy may cause reduced erythropoietin production. The resulting decrease in production of new red cells may lead to falsely high hemoglobin A1c (similar to nutrient deficiencies).

**(Choice E)** Chronically elevated blood glucose (ie, poor glycemic control) is the primary cause of increased hemoglobin A1c in patients with diabetes.

**(Choice F)** Sickle cell trait is characterized by heterozygous carriage of hemoglobin S. Some patients with sickle cell trait can have slightly reduced hemoglobin A1c level due to increased red cell turnover (homozygous individuals with sickle cell disease have rapid red cell turnover and very low A1c). However, hemoglobin A2 percentage remains near normal in patients with sickle cell mutations.

**Educational objective:**
Hemoglobin A1c is produced by nonenzymatic glycosylation of the hemoglobin molecule. A hemoglobin A1c assay provides an estimate of chronic glycemic control over the life span of circulating erythrocytes (~3 months). However, rapid erythrocyte turnover (eg, hemolytic anemia) can give a misleadingly low hemoglobin A1c in relation to glycemic status.

**References**

- Limitations of A1c interpretation.

| Pathology | Endocrine, Diabetes & Metabolism | Diabetes mellitus |
|---|---|---|
| Subject | System | Topic |

Copyright © UWorld. All rights reserved.

A 34-year-old woman comes to the office due to a 1 week history of mood swings, difficulty concentrating, and hand tremors. She also has pain at the front of her neck that radiates to her ears and is worse with swallowing. The patient initially attributed her symptoms to a flu-like illness that she had a few weeks earlier. She has no other medical conditions and takes no medications. Blood pressure is 140/80 mm Hg and pulse is 105/min. The thyroid gland is very tender on palpation. After initial laboratory testing, a thyroid scan is performed and reveals diffusely decreased radioiodine uptake. Erythrocyte sedimentation rate is 105 mm/hr. Which of the following pathological changes would be most likely on biopsy of this patient's thyroid gland?

A. Branching papillary structures with interspersed calcified bodies

B. Extensive stromal fibrosis extending beyond the thyroid capsule

C. Follicular hyperplasia with tall cells forming intrafollicular papillary projections

D. Mixed, cellular infiltration with occasional multinucleated giant cells

E. Mononuclear, parenchymal infiltration with well-developed germinal centers

Submit

A 34-year-old woman comes to the office due to a 1 week history of mood swings, difficulty concentrating, and hand tremors. She also has pain at the front of her neck that radiates to her ears and is worse with swallowing. The patient initially attributed her symptoms to a flu-like illness that she had a few weeks earlier. She has no other medical conditions and takes no medications. Blood pressure is 140/80 mm Hg and pulse is 105/min. The thyroid gland is very tender on palpation. After initial laboratory testing, a thyroid scan is performed and reveals diffusely decreased radioiodine uptake. Erythrocyte sedimentation rate is 105 mm/hr. Which of the following pathological changes would be most likely on biopsy of this patient's thyroid gland?

- A. Branching papillary structures with interspersed calcified bodies (4%)
- B. Extensive stromal fibrosis extending beyond the thyroid capsule (9%)
- C. Follicular hyperplasia with tall cells forming intrafollicular papillary projections (10%)
- ✓ D. Mixed, cellular infiltration with occasional multinucleated giant cells (58%)
- E. Mononuclear, parenchymal infiltration with well-developed germinal centers (17%)

Omitted
Correct answer
D

58%
Answered correctly

02 secs
Time Spent

03/16/2020
Last Updated

Explanation

| Important causes of thyroiditis | | |
|---|---|---|
| | **Subacute granulomatous thyroiditis** | **Hashimoto thyroiditis** |
| | • Onset following a **viral illness** | • **Autoimmune** etiology |

| Important causes of thyroiditis | | |
|---|---|---|
| | **Subacute granulomatous thyroiditis** | **Hashimoto thyroiditis** |
| **Clinical features** | • Onset following a **viral illness**<br>• **Painful** thyroid enlargement<br>• Transient **hyperthyroid** symptoms | • **Autoimmune** etiology<br>• **Painless** thyroid enlargement<br>• Predominant **hypothyroid** features |
| **Diagnostic testing** | • ↑ ESR & CRP<br>• ↓ Radioiodine uptake | • Positive **TPO antibody**<br>• Variable radioiodine uptake |
| **Pathology** | • Inflammatory infiltrate with macrophages & **giant cells** | • Lymphocytic infiltrate with well-developed **germinal centers**<br>• **Hürthle cells** (eosinophilic epithelial cells) |

CRP = C-reactive protein; ESR = erythrocyte sedimentation rate; TPO = thyroid peroxidase.

This patient with **painful** enlargement of the thyroid gland has **subacute granulomatous thyroiditis** (SGT), also called de Quervain thyroiditis. SGT typically follows an acute **viral illness** and is thought to be due to a cross-reacting immune response against viral proteins or tissue antigens released during cellular injury. Patients may experience a **transient hyperthyroid phase** (elevated thyroxine [T4], suppressed TSH) due to release of stored thyroid hormone. Radioiodine uptake is decreased in SGT as the low TSH levels suppress synthesis of new thyroid hormone. The disease is self-limited and resolves in <6 weeks, although patients may have a brief hypothyroid phase before returning to a euthyroid state.

SGT is initially characterized by a neutrophilic infiltrate with microabscess formation, which, as the disease progresses, is replaced by a more generalized inflammatory infiltrate with macrophages and **multinucleated giant cells**. The inflammatory process is reflected by elevated serum acute-phase markers (eg, C-reactive protein, erythrocyte sedimentation rate).

**(Choices A and C)** Papillary thyroid cancer is characterized by branching papillary structures with concentric calcifications (psammoma bodies). The tall-cell variant of papillary thyroid cancer is characterized by follicular hyperplasia lined by tall epithelial cells. These malignancies would typically present with nodular enlargement rather than acute pain and tenderness. Graves disease can also cause tall cells with follicular

SGT typically follows an acute **viral illness** and is thought to be due to a cross-reacting immune response against viral proteins or tissue antigens released during cellular injury. Patients may experience a **transient hyperthyroid phase** (elevated thyroxine [T4], suppressed TSH) due to release of stored thyroid hormone. Radioiodine uptake is decreased in SGT as the low TSH levels suppress synthesis of new thyroid hormone. The disease is self-limited and resolves in <6 weeks, although patients may have a brief hypothyroid phase before returning to a euthyroid state.

SGT is initially characterized by a neutrophilic infiltrate with microabscess formation, which, as the disease progresses, is replaced by a more generalized inflammatory infiltrate with macrophages and **multinucleated giant cells**. The inflammatory process is reflected by elevated serum acute-phase markers (eg, C-reactive protein, erythrocyte sedimentation rate).

**(Choices A and C)** Papillary thyroid cancer is characterized by branching papillary structures with concentric calcifications (psammoma bodies). The tall-cell variant of papillary thyroid cancer is characterized by follicular hyperplasia lined by tall epithelial cells. These malignancies would typically present with nodular enlargement rather than acute pain and tenderness. Graves disease can also cause tall cells with follicular hyperplasia, but radioiodine uptake is increased due to excessive TSH receptor stimulation.

**(Choice B)** Riedel thyroiditis is characterized by extensive fibrosis of the thyroid gland that extends into surrounding tissues. The thyroid gland is hard and nontender.

**(Choice E)** Chronic lymphocytic (Hashimoto) thyroiditis is characterized by diffuse, painless thyroid enlargement, often with symptoms of hypothyroidism (eg, fatigue, cold intolerance). Biopsy reveals diffuse lymphocytic infiltration with formation of germinal centers.

**Educational objective:**
Subacute granulomatous (de Quervain) thyroiditis is characterized by painful thyroid enlargement and usually follows a viral illness. Biopsy shows a mixed inflammatory infiltrate with macrophages and multinucleated giant cells.

**References**

- Subacute granulomatous (De Quervain's) thyroiditis: Fine-needle aspiration cytology and ultrasonographic characteristics of 21 cases.

| Pathology | Endocrine, Diabetes & Metabolism | Subacute thyroiditis |
|---|---|---|
| Subject | System | Topic |

Copyright © UWorld. All rights reserved.

SGT typically follows an acute **viral illness** and is thought to be due to a cross-reacting immune response against viral proteins or tissue antigens

**Exhibit Display**

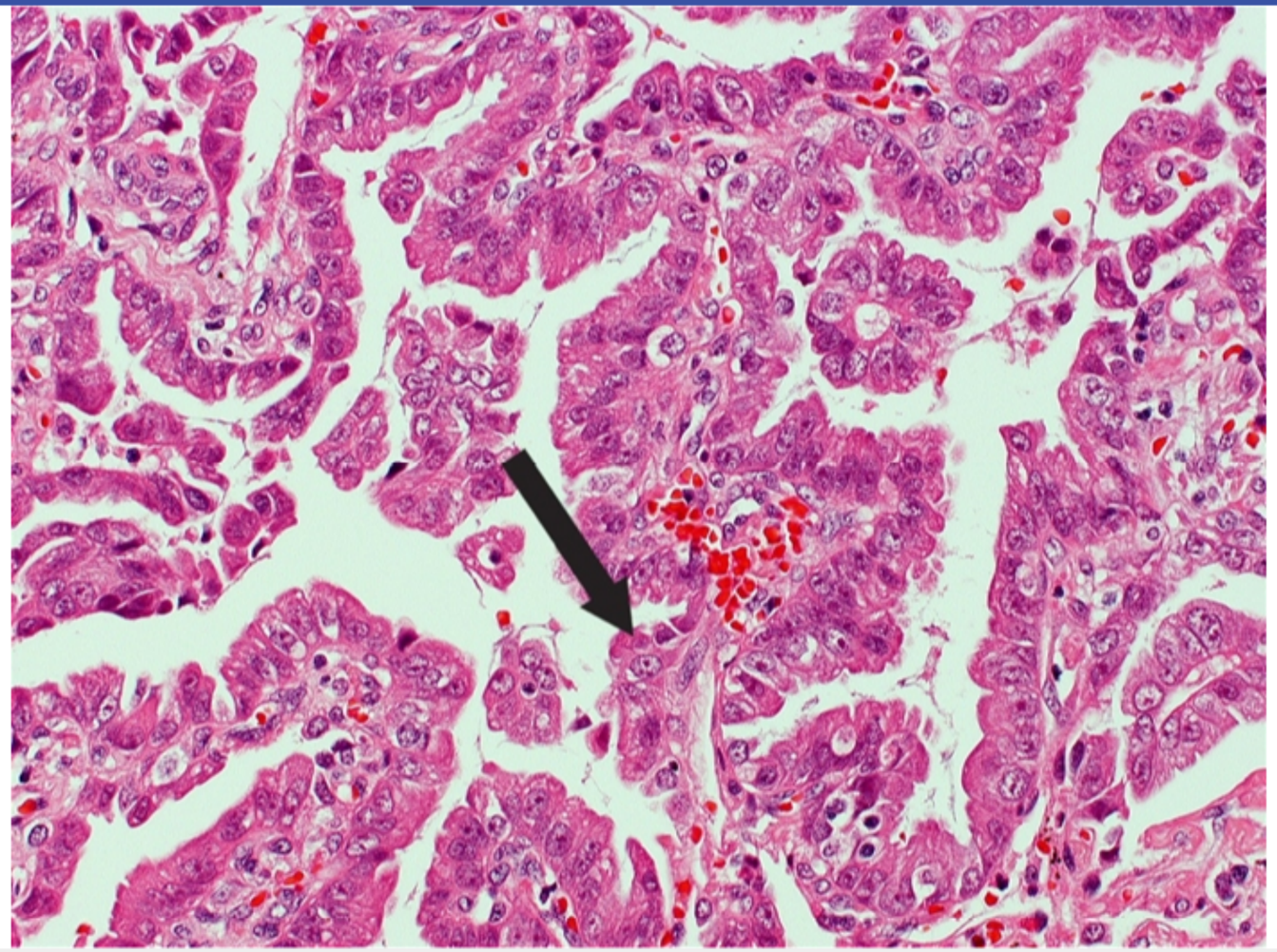

Zoom In | Zoom Out | Reset | Add To New Card | Existing Card

SGT typically follows an acute **viral illness** and is thought to be due to a cross-reacting immune response against viral proteins or tissue antigens

**Exhibit Display**

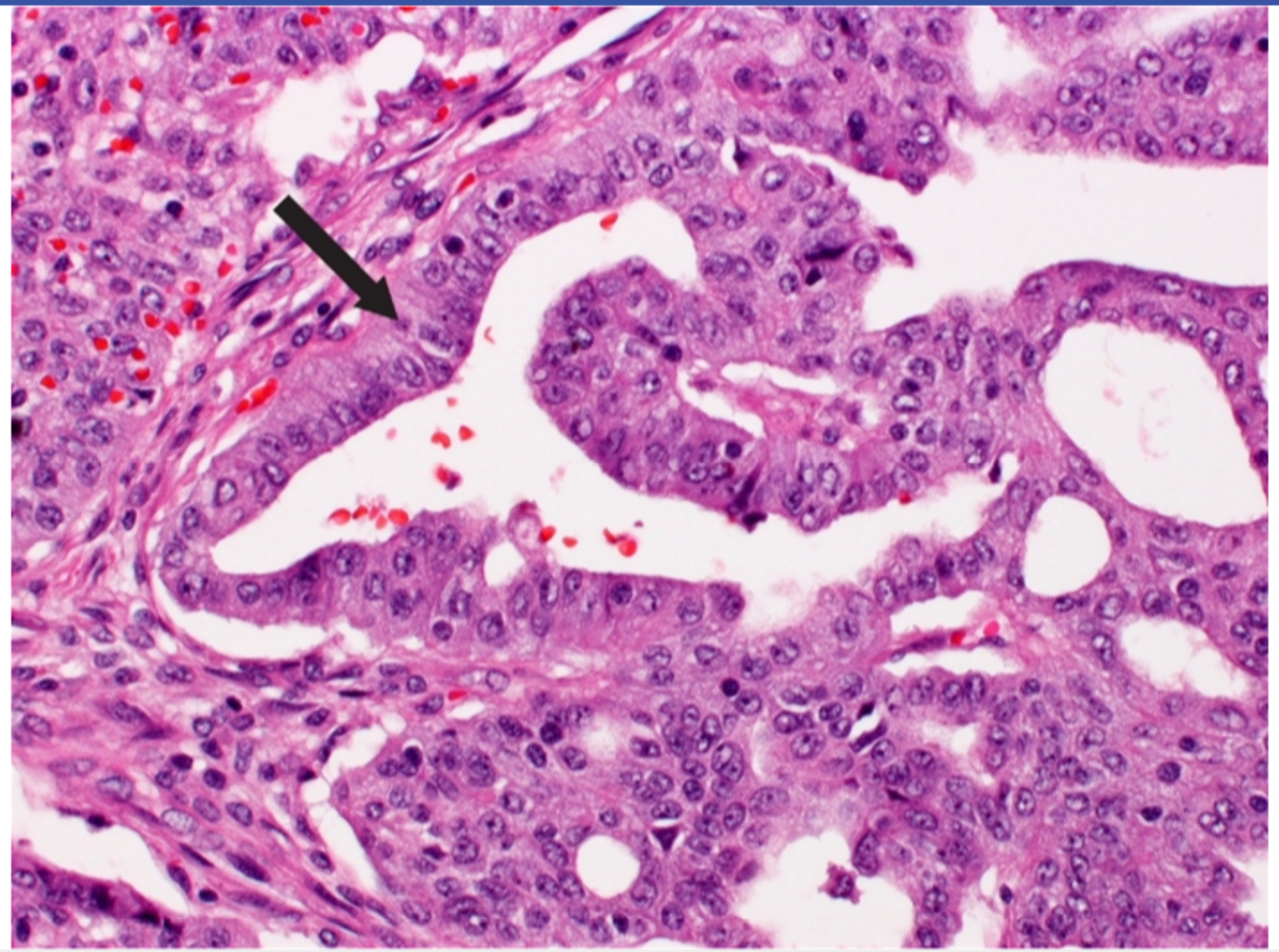

Zoom In | Zoom Out | Reset | Add To New Card | Existing Card

SGT typically follows an acute **viral illness** and is thought to be due to a cross-reacting immune response against viral proteins or tissue antigens

Exhibit Display

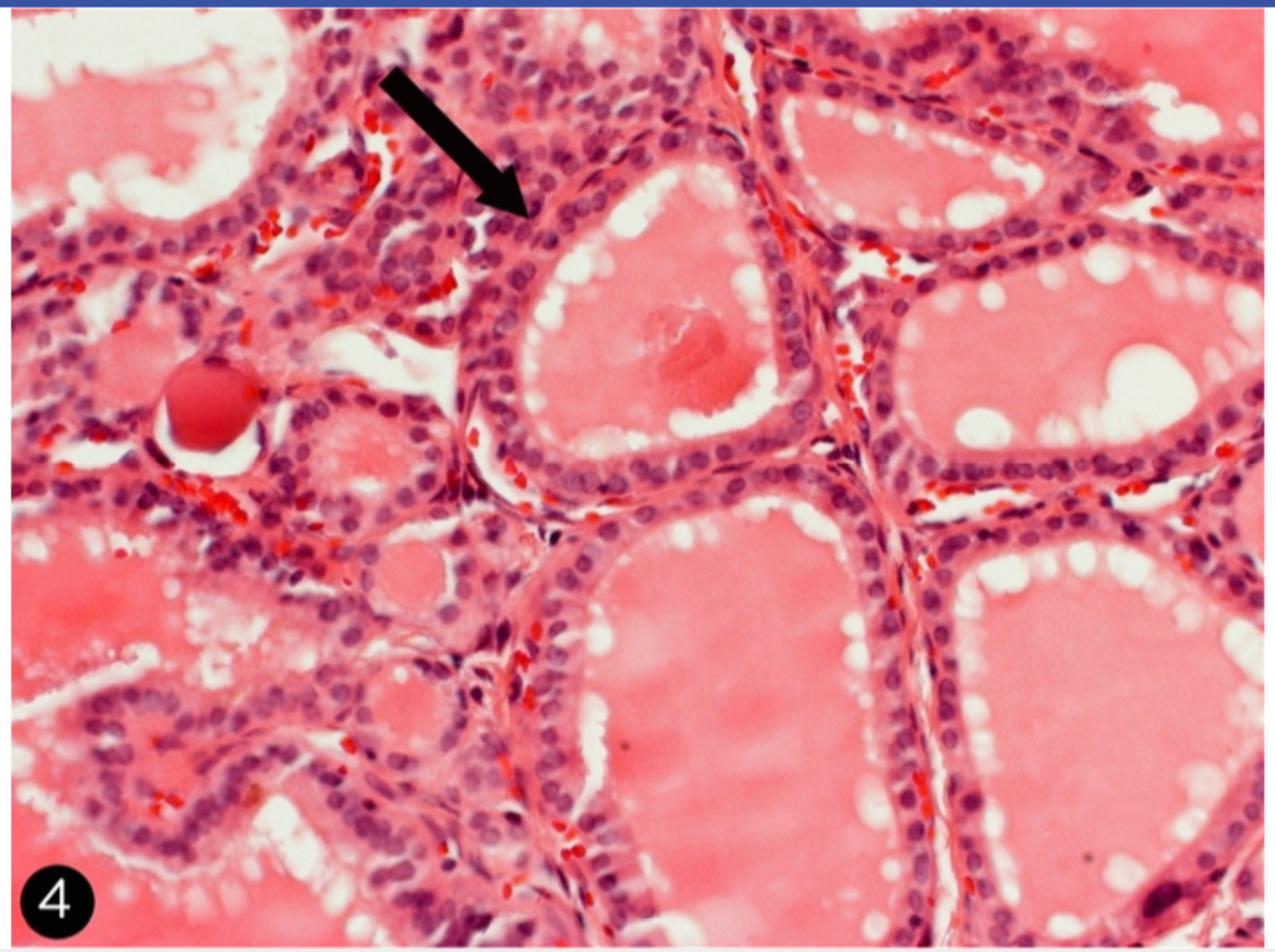


Zoom In | Zoom Out | Reset | Add To New Card | Existing Card

1
2
3
4
5
6
7
8
9
10
11
12
13
14
15
16
17
18
19
20
21
22
23
24
25
26
27
28
29
30
31

SGT typically follows an acute **viral illness** and is thought to be due to a cross-reacting immune response against viral proteins or tissue antigens

**Exhibit Display**

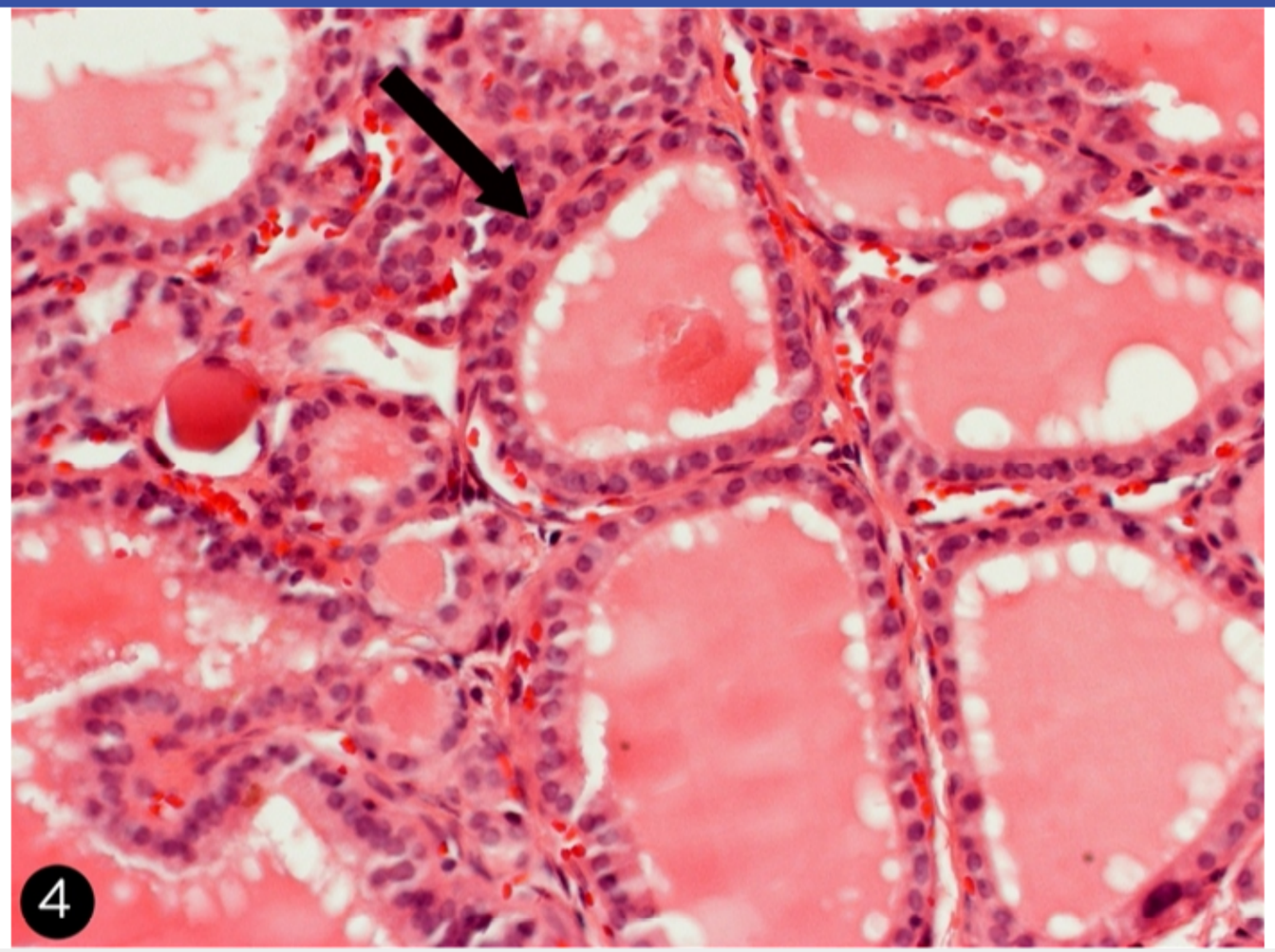


Zoom In | Zoom Out | Reset | Add To New Card | Existing Card

SGT typically follows an acute **viral illness** and is thought to be due to a cross-reacting immune response against viral proteins or tissue antigens

**Exhibit Display**

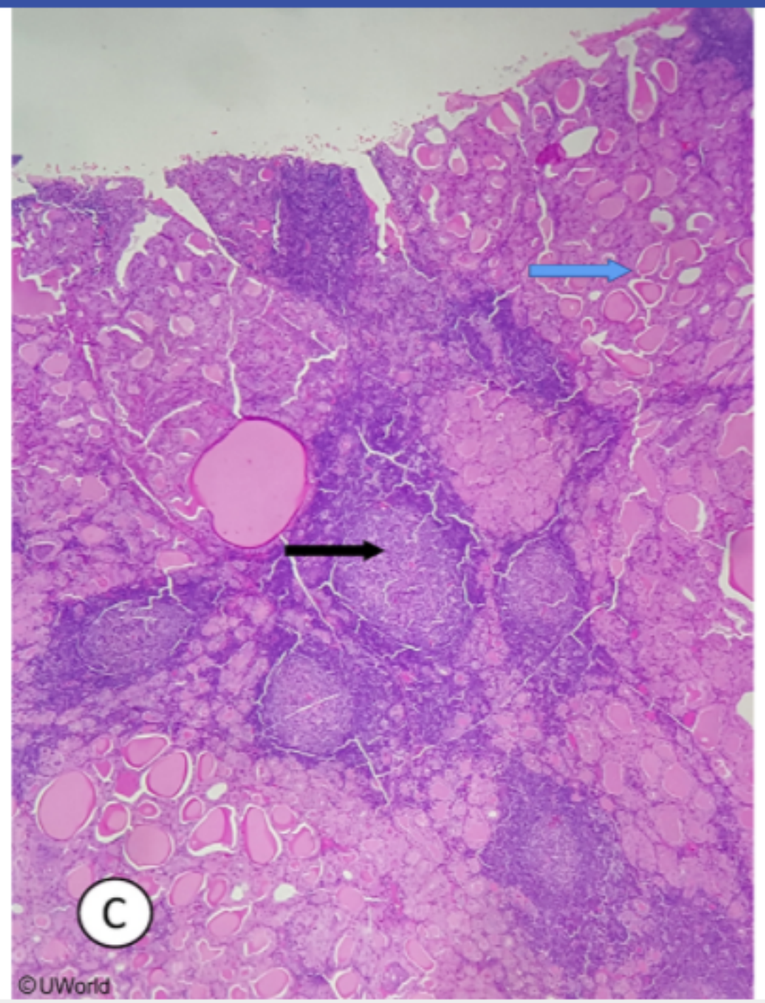


Zoom In | Zoom Out | Reset | Add To New Card | Existing Card

1
2
3
4
5
6
7
8
9
10
11
12
13
14
15
16
17
18
19
20
21
22
23
24
25
26
27
28
29
30
31

A 14-year-old boy is brought to the physician by his mother. She is concerned because although tall, her son looks much younger than his peers and shows no signs of "masculinity." On physical examination, the boy has poorly developed secondary sexual characteristics. He is unable to distinguish smells but has good visual acuity. Which of the following pathways is most likely defective in this patient?

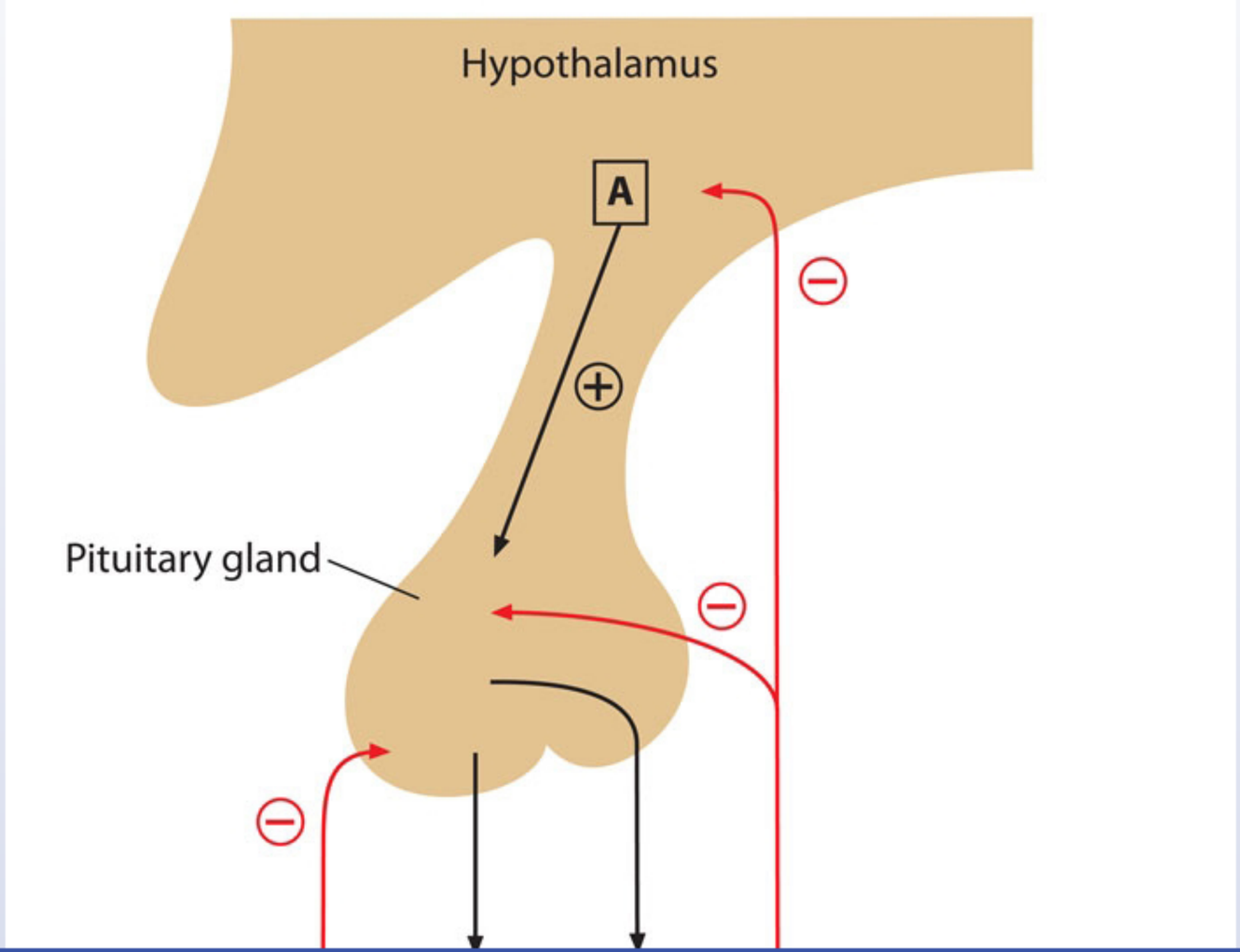

1
2
3
4
5
6
7
8
9
10
11
12
13
14
15
16
17
18
19
20
21
22
23
24
25
26
27
28
29
30
31

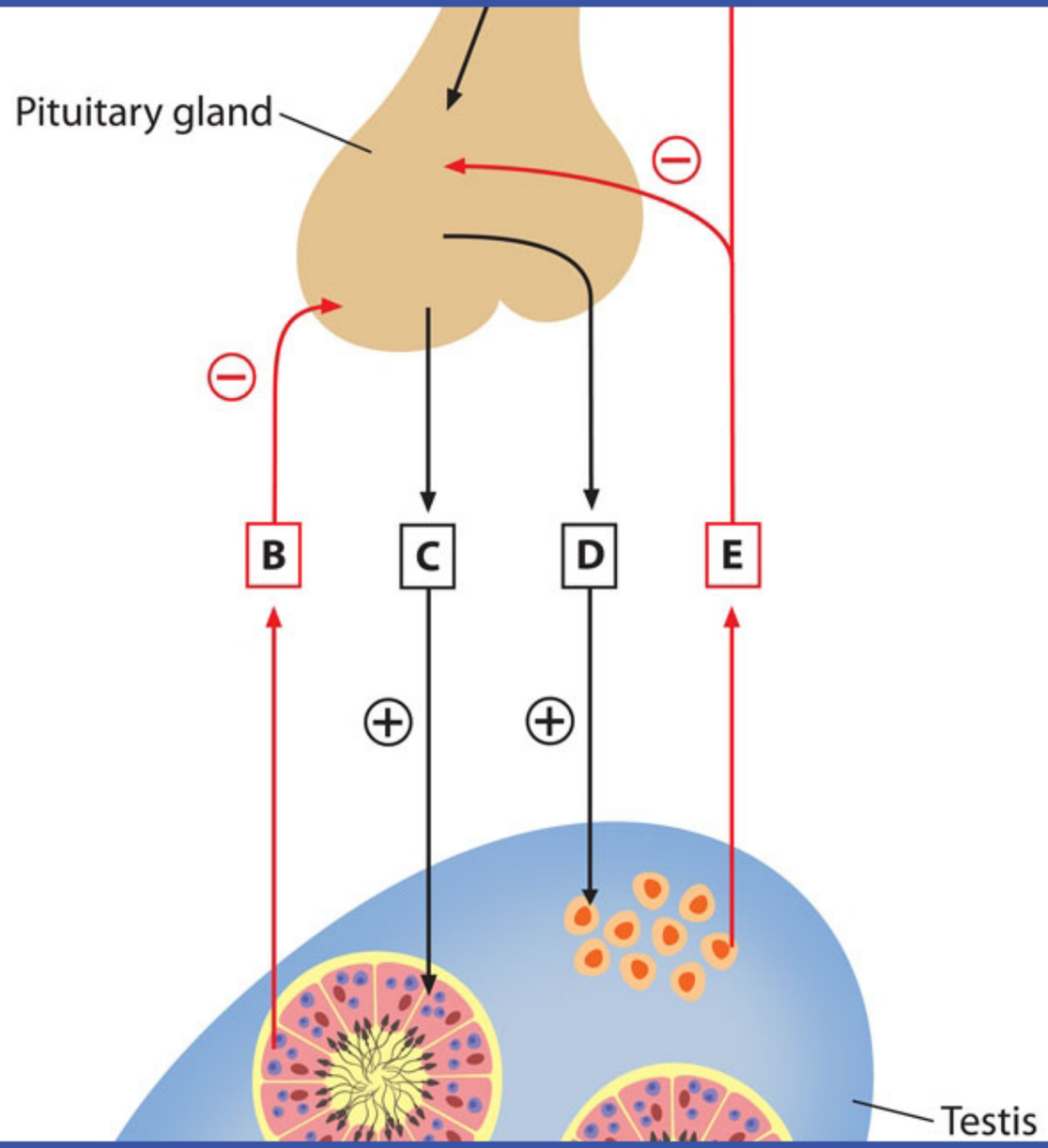

1
2
3
4
5
6
7
8
9
10
11
12
13
14
15
16
17
18
19
20
21
22
23
24
25
26
27
28
29
30
31

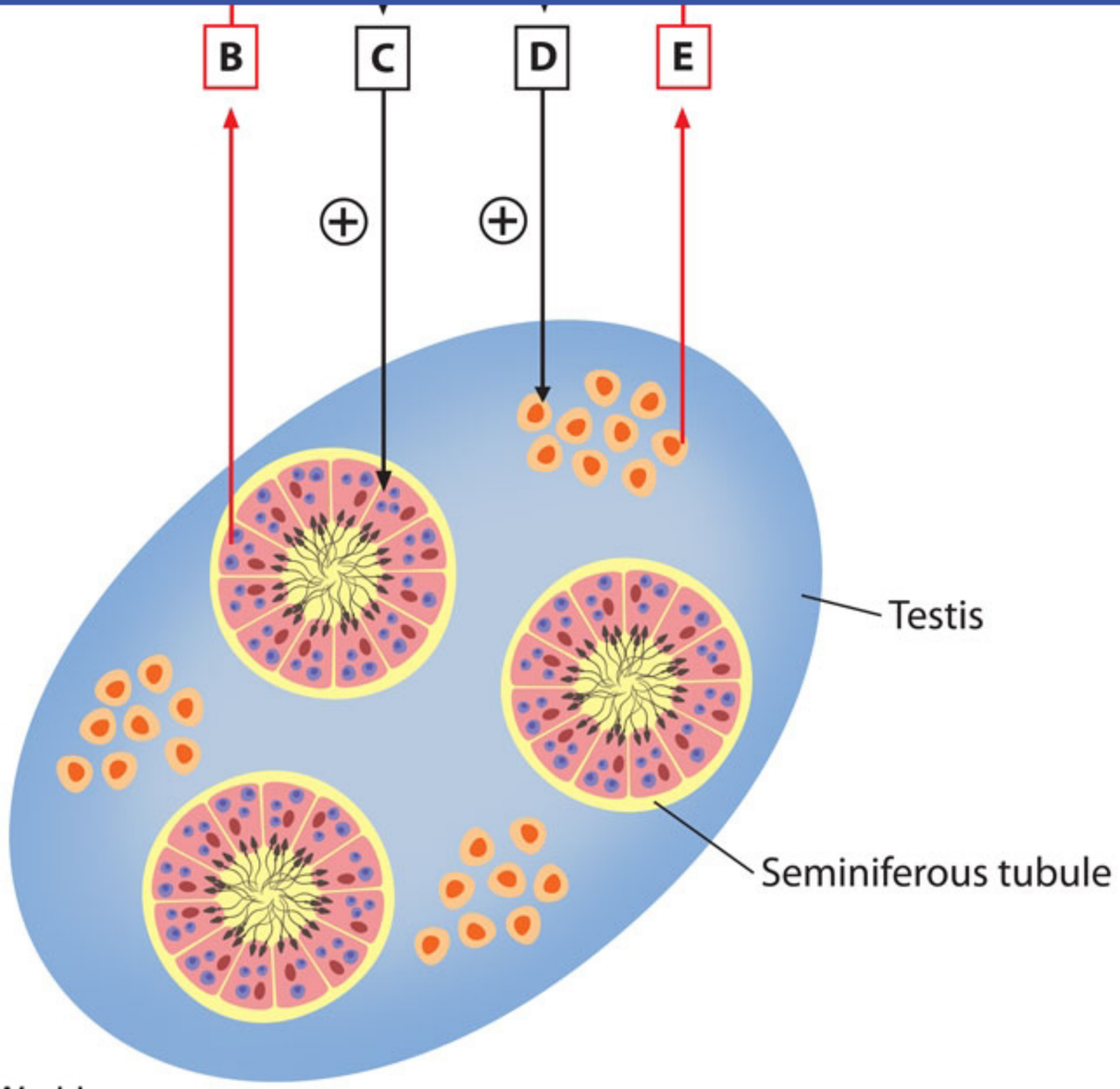


©UWorld

1
2
3
4
5
6
7
8
9
10
11
12
13
14
15
16
17
18
19
20
21
22
23
24
25
26
27
28
29
30
31

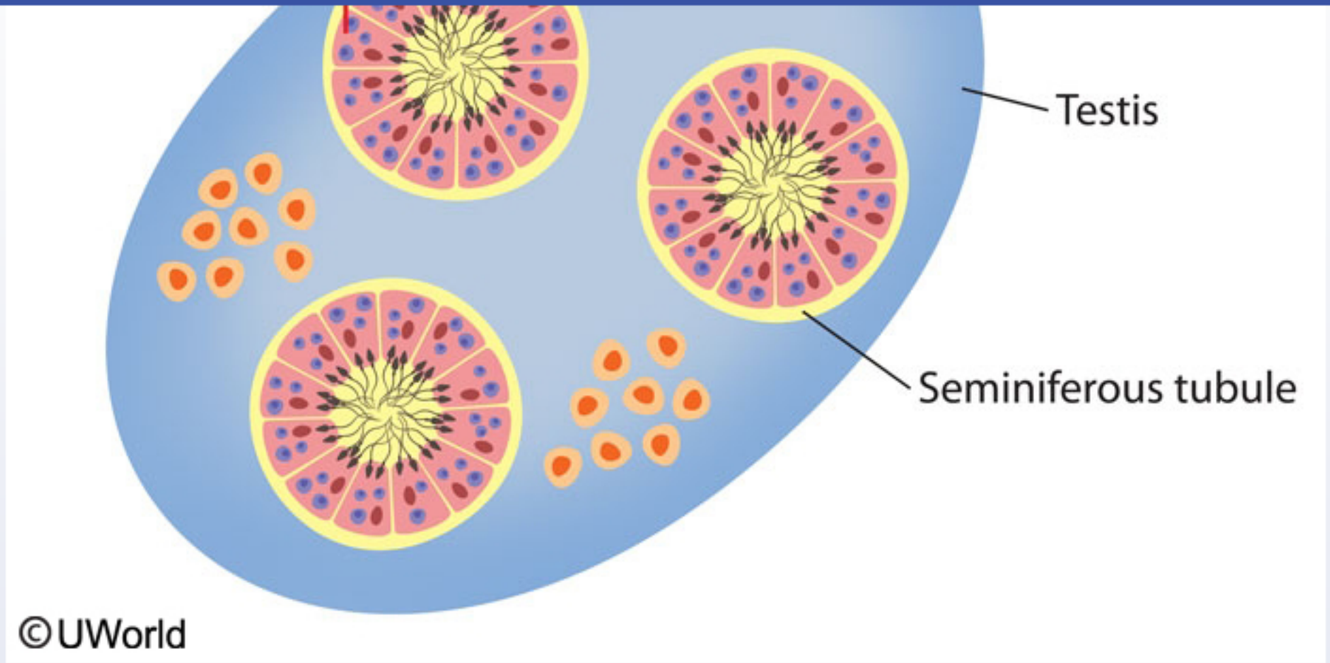


A. A

B. B

C. C

D. D

E. E

Submit

1 2 3 4 5 6 7 8 9 10 11 12 13 14 15 16 17 18 19 20 21 22 23 24 25 26 27 28 29 30 31

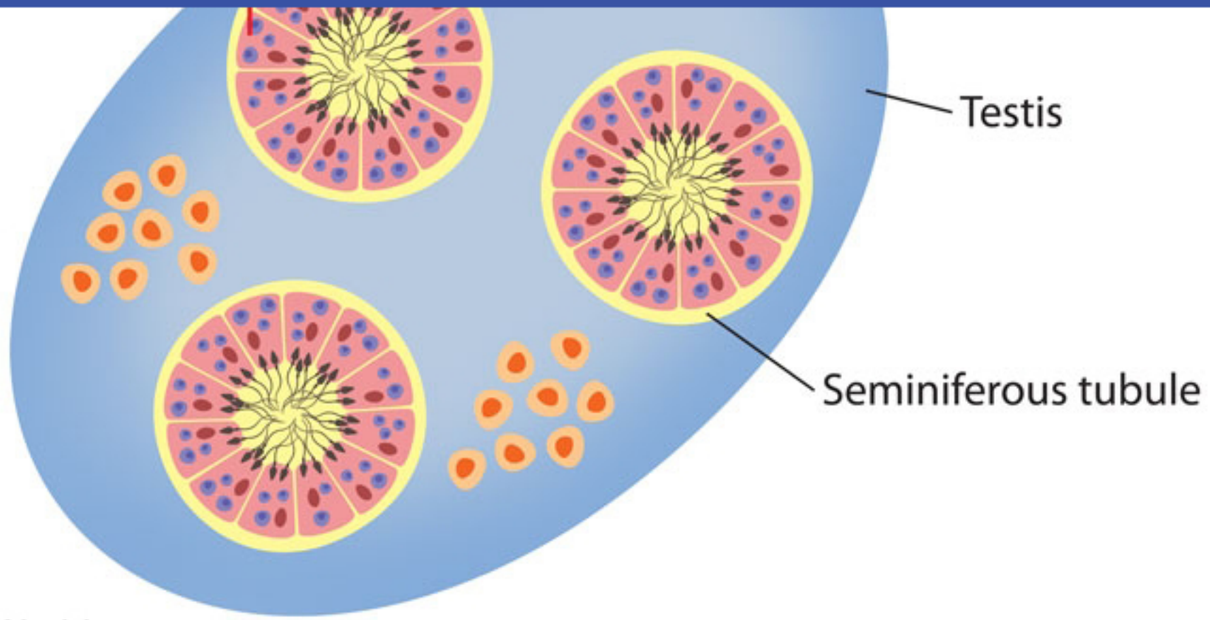


©UWorld

- ✓ A. A (57%)
- B. B (4%)
- C. C (8%)
- D. D (20%)
- E. E (8%)

Omitted
Correct answer

57%
Answered correctly

13 secs
Time Spent

07/08/2020
Last Updated

Explanation

This patient has delayed puberty plus anosmia, consistent with a diagnosis of Kallmann syndrome. Kallmann syndrome results from a failure of GnRH-secreting neurons to migrate from their origin in the olfactory placode (situated outside the central nervous system) to their normal anatomic location in the hypothalamus. Most often, the cause is a mutation in the KAL-1 gene or the fibroblast growth factor receptor-1 gene, which code for proteins required in this migration.

Patients with Kallmann syndrome classically have central hypogonadism and anosmia, although there may be other midline defects as well (eg, cleft lip or cleft palate). Most often, these patients present with delayed puberty. On physical examination, the testes are often just 1-2 mL in volume. There is usually some pubic hair because adrenarche occurs normally.

In the United States, delayed puberty is defined as the absence or incomplete development of secondary sexual characteristics by age 14 in boys and by age 12 in girls. Testicular enlargement is the first sign of puberty in boys, and breast enlargement is the first sign in girls. The initiation of puberty and the maintenance of secondary sexual characteristics and fertility require the coordinated efforts of the hypothalamus, pituitary, and gonads. Delayed puberty can result from a derangement anywhere in this axis.

**(Choices B, C, D, and E)** These pathways represent normal feedback loops between the testes and the hypothalamus and pituitary. Pituitary follicle-stimulating hormone (FSH) stimulates proliferation of the seminiferous tubules and spermatogenesis. The seminiferous tubules produce inhibin, which feeds back to inhibit pituitary FSH secretion. Luteinizing hormone from the pituitary stimulates the interstitial Leydig cells to produce testosterone, which also participates in feedback inhibition.

**Educational objective:**
In Kallmann syndrome, there is an absence of GnRH secretory neurons in the hypothalamus due to defective migration from the olfactory placode. These patients have central hypogonadism and anosmia, and often present with delayed puberty.

| Pathology | Endocrine, Diabetes & Metabolism | Kallmann syndrome |
|---|---|---|
| Subject | System | Topic |

Copyright © UWorld. All rights reserved.

1
2
3
4
5
6
7
8
9
10
11
12
13
14
15
16
17
18
19
20
21
22
23
24
25
26
27
28
29
30
31

## Exhibit Display

Gonadotropin regulation

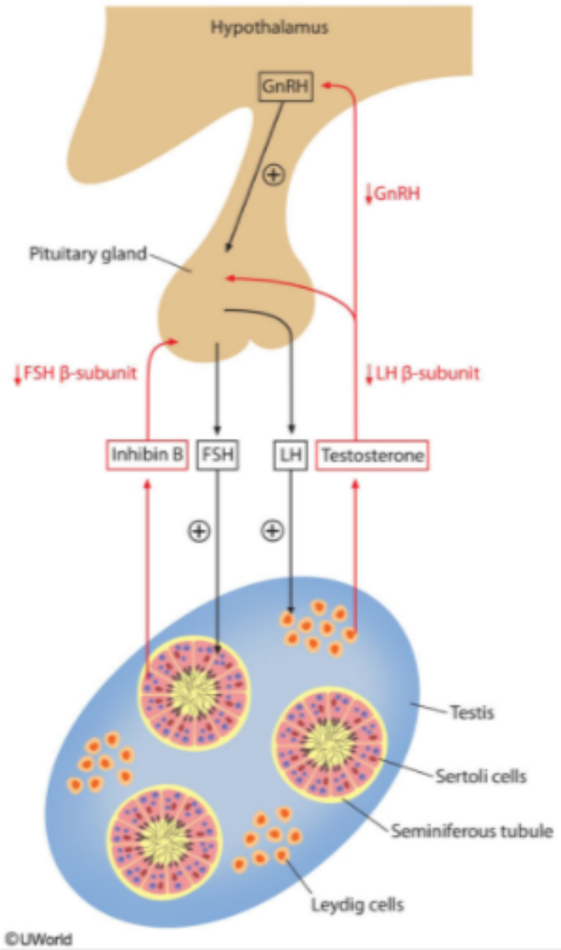


Zoom In | Zoom Out | Reset | Add To New Card | Existing Card

A 54-year-old man comes to the office due to worsening fatigue, generalized weakness, and an unintentional 7-kg (15.4-lb) weight loss over the past several weeks. The patient has no prior medical conditions and takes no medications. He has a 40-pack-year history of smoking and does not use alcohol or illicit drugs. Blood pressure is 160/100 mm Hg and pulse is 80/min. Physical examination shows darkening of the skin in sun-exposed areas. There are scattered ecchymoses on the extremities. Mild proximal muscle weakness is present. Chest imaging reveals a 6-cm, irregular right lung mass with mediastinal lymphadenopathy. Which of the following is most likely responsible for the patient's current symptoms?

- A. ACTH production from an ectopic site
- B. Excess cortisol release from the lung mass
- C. Excessive ACTH secretion from the pituitary
- D. Hypothalamic dysfunction from metastatic process
- E. Malignant invasion of the adrenal cortex

Submit

A 54-year-old man comes to the office due to worsening fatigue, generalized weakness, and an unintentional 7-kg (15.4-lb) weight loss over the past several weeks. The patient has no prior medical conditions and takes no medications. He has a 40-pack-year history of smoking and does not use alcohol or illicit drugs. Blood pressure is 160/100 mm Hg and pulse is 80/min. Physical examination shows darkening of the skin in sun-exposed areas. There are scattered ecchymoses on the extremities. Mild proximal muscle weakness is present. Chest imaging reveals a 6-cm, irregular right lung mass with mediastinal lymphadenopathy. Which of the following is most likely responsible for the patient's current symptoms?

- ✓ A. ACTH production from an ectopic site (85%)
- B. Excess cortisol release from the lung mass (3%)
- C. Excessive ACTH secretion from the pituitary (3%)
- D. Hypothalamic dysfunction from metastatic process (2%)
- E. Malignant invasion of the adrenal cortex (4%)

Omitted
Correct answer
A

85%
Answered correctly

02 secs
Time Spent

04/18/2020
Last Updated

Explanation

| Common paraneoplastic syndromes associated with lung cancer | |
|---|---|
| **Endocrine** | • Syndrome of inappropriate antidiuretic hormone*<br>• Parathyroid hormone-related protein secretion (hypercalcemia)<br>• Ectopic ACTH production (Cushing syndrome)* |

Explanation

| Common paraneoplastic syndromes associated with lung cancer | |
|---|---|
| **Endocrine** | • Syndrome of inappropriate antidiuretic hormone*<br>• Parathyroid hormone-related protein secretion (hypercalcemia)<br>• Ectopic ACTH production (Cushing syndrome)* |
| **Neurologic** | • Lambert-Eaton myasthenic syndrome*<br>• Paraneoplastic cerebellar degeneration* |
| **Musculoskeletal** | • Hypertrophic osteoarthropathy (clubbing) |

*Generally associated with small cell lung cancer.

This patient has fatigue, weakness, and weight loss associated with a suspicious **lung mass**. His hypertension, ecchymoses, and hyperpigmentation suggest **paraneoplastic hypercortisolism** (Cushing syndrome) due to **ectopic ACTH** secretion. As with primary adrenal insufficiency, excess ACTH secretion leads to hyperpigmentation, likely due to co-secretion of alpha-melanocyte-stimulating hormone (alpha-MSH) (both ACTH and alpha-MSH are derived from pro-opiomelanocortin) and direct stimulation of the MC2R receptor on melanocytes by ACTH. Although patients with paraneoplastic hypercortisolism may have many of the typical metabolic features of cortisol excess (eg, hypertension, hyperglycemia, edema), **weight loss** is more common than classic Cushingoid central obesity.

Paraneoplastic hypercortisolism is most commonly associated with small cell lung cancer but can also be seen with other neuroendocrine tumors (eg, bronchial or pancreatic carcinoid). ACTH secreted by small cell lung cancer is not inhibited by high-dose exogenous corticosteroids (eg, dexamethasone), whereas pituitary ACTH secretion decreases via negative feedback.

**(Choice B)** Cortisol is produced by the zona fasciculata of the adrenal cortex, and autonomous cortisol production (ie, ACTH-independent hypercortisolism) is almost always due to a primary adrenal disorder (eg, adrenal adenoma). Regardless of the source, excess cortisol in a patient with intact hypothalamus-pituitary function suppresses ACTH and patients do not develop hyperpigmentation.

**(Choice C)** Given this patient's large lung mass and associated weight loss (instead of weight gain and central fat deposition), paraneoplastic ACTH secretion is more likely than an ACTH-producing pituitary adenoma (Cushing disease)

*Generally associated with small cell lung cancer.

This patient has fatigue, weakness, and weight loss associated with a suspicious **lung mass**. His hypertension, ecchymoses, and hyperpigmentation suggest **paraneoplastic hypercortisolism** (Cushing syndrome) due to **ectopic ACTH** secretion. As with primary adrenal insufficiency, excess ACTH secretion leads to hyperpigmentation, likely due to co-secretion of alpha-melanocyte-stimulating hormone (alpha-MSH) (both ACTH and alpha-MSH are derived from pro-opiomelanocortin) and direct stimulation of the MC2R receptor on melanocytes by ACTH. Although patients with paraneoplastic hypercortisolism may have many of the typical metabolic features of cortisol excess (eg, hypertension, hyperglycemia, edema), **weight loss** is more common than classic Cushingoid central obesity.

Paraneoplastic hypercortisolism is most commonly associated with small cell lung cancer but can also be seen with other neuroendocrine tumors (eg, bronchial or pancreatic carcinoid). ACTH secreted by small cell lung cancer is not inhibited by high-dose exogenous corticosteroids (eg, dexamethasone), whereas pituitary ACTH secretion decreases via negative feedback.

**(Choice B)** Cortisol is produced by the zona fasciculata of the adrenal cortex, and autonomous cortisol production (ie, ACTH-independent hypercortisolism) is almost always due to a primary adrenal disorder (eg, adrenal adenoma). Regardless of the source, excess cortisol in a patient with intact hypothalamus-pituitary function suppresses ACTH and patients do not develop hyperpigmentation.

**(Choice C)** Given this patient's large lung mass and associated weight loss (instead of weight gain and central fat deposition), paraneoplastic ACTH secretion is more likely than an ACTH-producing pituitary adenoma (Cushing disease).

**(Choice D)** Metastasis to the hypothalamus would likely cause endocrine insufficiency resulting from a lack of trophic hormones to the anterior pituitary. Decreased production of corticotropin-releasing hormone would lead to central adrenal insufficiency, not hypercortisolism.

**(Choice E)** The adrenal glands are a common site of metastasis. If significant destruction of the adrenal cortical tissue occurs bilaterally, adrenal insufficiency may result. A subsequent increase of ACTH may cause hyperpigmentation; however, symptoms of adrenal insufficiency (eg, hypotension) would be expected, as opposed to the symptoms of cortisol excess seen in this patient.

**Educational objective:**
Paraneoplastic hypercortisolism, most commonly caused by small cell lung cancer, is due to ectopic ACTH secretion. Clinical features include hypertension, hyperglycemia, edema, and hyperpigmentation. Unlike nonparaneoplastic Cushing syndrome, central obesity is uncommon.

insufficiency, excess ACTH secretion leads to hyperpigmentation, likely due to co-secretion of alpha-melanocyte-stimulating hormone (alpha-MSH) (both ACTH and alpha-MSH are derived from pro-opiomelanocortin) and direct stimulation of the MC2R receptor on melanocytes by ACTH. Although patients with paraneoplastic hypercortisolism may have many of the typical metabolic features of cortisol excess (eg, hypertension, hyperglycemia, edema), **weight loss** is more common than classic Cushingoid central obesity.

Paraneoplastic hypercortisolism is most commonly associated with small cell lung cancer but can also be seen with other neuroendocrine tumors (eg, bronchial or pancreatic carcinoid). ACTH secreted by small cell lung cancer is not inhibited by high-dose exogenous corticosteroids (eg, dexamethasone), whereas pituitary ACTH secretion decreases via negative feedback.

**(Choice B)** Cortisol is produced by the zona fasciculata of the adrenal cortex, and autonomous cortisol production (ie, ACTH-independent hypercortisolism) is almost always due to a primary adrenal disorder (eg, adrenal adenoma). Regardless of the source, excess cortisol in a patient with intact hypothalamus-pituitary function suppresses ACTH and patients do not develop hyperpigmentation.

**(Choice C)** Given this patient's large lung mass and associated weight loss (instead of weight gain and central fat deposition), paraneoplastic ACTH secretion is more likely than an ACTH-producing pituitary adenoma (Cushing disease).

**(Choice D)** Metastasis to the hypothalamus would likely cause endocrine insufficiency resulting from a lack of trophic hormones to the anterior pituitary. Decreased production of corticotropin-releasing hormone would lead to central adrenal insufficiency, not hypercortisolism.

**(Choice E)** The adrenal glands are a common site of metastasis. If significant destruction of the adrenal cortical tissue occurs bilaterally, adrenal insufficiency may result. A subsequent increase of ACTH may cause hyperpigmentation; however, symptoms of adrenal insufficiency (eg, hypotension) would be expected, as opposed to the symptoms of cortisol excess seen in this patient.

**Educational objective:**
Paraneoplastic hypercortisolism, most commonly caused by small cell lung cancer, is due to ectopic ACTH secretion. Clinical features include hypertension, hyperglycemia, edema, and hyperpigmentation. Unlike nonparaneoplastic Cushing syndrome, central obesity is uncommon.

| Pathology | Endocrine, Diabetes & Metabolism | Cushing syndrome |
|---|---|---|
| Subject | System | Topic |

Copyright © UWorld. All rights reserved.

1
2
3
4
5
6
7
8
9
10
11
12
13
14
15
16
17
18
19
20
21
22
23
24
25
26
27
28
29
30
31

A 7-year-old boy is being evaluated for growth retardation. Brain MRI shows a 4 cm multiloculated, cystic, suprasellar lesion, which is bulging into the floor of the third ventricle and base of the brain. Calcifications are present. From which of the following structures is this mass most likely derived?

A. Prolactin secreting cells of the anterior pituitary

B. Remnants of the Rathke pouch

C. Astrocytes

D. Arachnoid cap cells

E. Posterior pituitary cells

Submit

A 7-year-old boy is being evaluated for growth retardation. Brain MRI shows a 4 cm multiloculated, cystic, suprasellar lesion, which is bulging into the floor of the third ventricle and base of the brain. Calcifications are present. From which of the following structures is this mass most likely derived?

- A. Prolactin secreting cells of the anterior pituitary (6%)
- ✓ B. Remnants of the Rathke pouch (80%)
- C. Astrocytes (7%)
- D. Arachnoid cap cells (2%)
- E. Posterior pituitary cells (3%)

Omitted
Correct answer
B

80%
Answered correctly

02 secs
Time Spent

05/25/2020
Last Updated

## Explanation

Craniopharyngiomas are tumors arising from remnants of Rathke's pouch. The anterior pituitary is formed from an out-pouching of the pharyngeal roof and is called Rathke's pouch. The posterior pituitary gland arises from an extension of the hypothalamic neurons. Together, the anterior and posterior pituitary glands lie in the sella turcica at the skull base.

During the time of pituitary development, remnants of Rathke's pouch cells can remain in the diencephalon (the posterior region of the forebrain). Neoplastic transformation of these "pouch cells" is called a craniopharyngioma. Typically, craniopharyngiomas have three components: solid, comprised of the actual tumor cells; cystic, filled with "machinery oil" liquid; and a calcified component. Any suprasellar mass with three components is highly suggestive of craniopharyngioma. Craniopharyngioma symptoms include headaches, visual field defects, and

1 2 3 4 5 6 7 8 9 10 11 12 13 14 15 16 17 18 19 20 21 22 23 24 25 26 27 28 29 30 31

Craniopharyngiomas are tumors arising from remnants of Rathke's pouch. The anterior pituitary is formed from an out-pouching of the pharyngeal roof and is called Rathke's pouch. The posterior pituitary gland arises from an extension of the hypothalamic neurons. Together, the anterior and posterior pituitary glands lie in the sella turcica at the skull base.

During the time of pituitary development, remnants of Rathke's pouch cells can remain in the diencephalon (the posterior region of the forebrain). Neoplastic transformation of these "pouch cells" is called a craniopharyngioma. Typically, craniopharyngiomas have three components: solid, comprised of the actual tumor cells; cystic, filled with "machinery oil" liquid; and a calcified component. Any suprasellar mass with three components is highly suggestive of craniopharyngioma. Craniopharyngioma symptoms include headaches, visual field defects, and hypopituitarism, evidenced by the growth retardation of this child. Ultimately, compression of the pituitary stalk by craniopharyngioma leads to hyperprolactinemia by loss of dopaminergic inhibition. Craniopharyngiomas are usually tumors of childhood, being most frequently discovered between the ages of 5 and 10 years of age.

**(Choice A)** Prolactinomas are uncommon in young children. They typically appear as a homogenous mass when imaged.

**(Choice C)** Gliomas can occur in the suprasellar region if they arise from the optic apparatus, but do not appear on imaging with the three components described above. Gliomas typically presents with visual symptoms, hypothalamic dysfunction, and hypopituitarism.

**(Choice D)** Meningiomas are tumors of the leptomeninges, which is the lining of the brain. Hence, meningiomas can occur in any "lined" part of the brain including sellar and suprasellar regions. Meningiomas are usually homogeneous appearance on MRI and can be seen "sticking" to leptomeninges.

**Educational Objective:**

1. The anterior pituitary is formed from an out-pouching of the pharyngeal roof and is called Rathke's pouch. The posterior pituitary gland arises from an extension of the hypothalamic neurons.
2. Craniopharyngiomas are tumors arising from Rathke's pouch remnants in the anterior pituitary. They characteristically have three components: solid, cystic, and calcified. They present during childhood, usually, with mass effect and visual deficits.

| Pathology | Endocrine, Diabetes & Metabolism | Craniopharyngiomas |
|---|---|---|
| Subject | System | Topic |

Copyright © UWorld. All rights reserved.

1
2
3
4
5
6
7
8
9
10
11
12
13
14
15
16
17
18
19
20
21
22
23
24
25
26
27
28
29
30
31

A 45-year-old previously healthy man comes to the office for evaluation of a neck lump. The patient first noticed the swelling a month ago while shaving, and it has progressively enlarged. He has had no fever, neck pain, hoarseness, or difficulty breathing or swallowing. The patient does not use tobacco, alcohol, or illicit drugs. Temperature is 36.7 C (98 F), blood pressure is 110/70 mm Hg, and pulse is 78/min. On physical examination, there is a nontender, firm nodule in the upper portion of the left thyroid lobe. Laboratory studies reveal a normal serum TSH and elevated serum calcitonin levels. Neck ultrasonography shows a 2-cm hypoechoic thyroid nodule with microcalcifications. Fine-needle aspiration of the nodule reveals spindle-shaped cells in an amorphous background. Which of the following gene alterations most likely contributed to this patient's current condition?

A. Activation of *ALK*

B. Activation of *RET*

C. Inactivation of *MEN1*

D. Inactivation of p53

E. Overexpression of *BCL2*

F. Overexpression of *JAK2*

Submit

A 45-year-old previously healthy man comes to the office for evaluation of a neck lump. The patient first noticed the swelling a month ago while shaving, and it has progressively enlarged. He has had no fever, neck pain, hoarseness, or difficulty breathing or swallowing. The patient does not use tobacco, alcohol, or illicit drugs. Temperature is 36.7 C (98 F), blood pressure is 110/70 mm Hg, and pulse is 78/min. On physical examination, there is a nontender, firm nodule in the upper portion of the left thyroid lobe. Laboratory studies reveal a normal serum TSH and elevated serum calcitonin levels. Neck ultrasonography shows a 2-cm hypoechoic thyroid nodule with microcalcifications. Fine-needle aspiration of the nodule reveals spindle-shaped cells in an amorphous background. Which of the following gene alterations most likely contributed to this patient's current condition?

A. Activation of *ALK* (0%)
✓ B. Activation of *RET* (76%)
C. Inactivation of *MEN1* (16%)
D. Inactivation of p53 (3%)
E. Overexpression of *BCL2* (1%)
F. Overexpression of *JAK2* (0%)

Omitted
Correct answer
B

76%
Answered correctly

02 secs
Time Spent

04/30/2020
Last Updated

Explanation

**Tumors associated with specific oncogenes**

1
2
3
4
5
6
7
8
9
10
11
12
13
14
15
16
17
18
19
20
21
22
23
24
25
26
27
28
29
30
31

| Tumors associated with specific oncogenes | |
|---|---|
| **Proto-oncogenes (tumor promoters)** | |
| *ABL* | Chronic myeloid leukemia |
| *ALK* | Large cell lymphoma, non–small cell lung cancer |
| *BRAF* | Melanoma |
| *HER1* | Squamous cell lung cancer |
| *HER2/neu* | Breast cancer, ovarian cancer |
| *MYC* | Neuroblastoma (NMYC), small cell lung cancer (LMYC) |
| *RET* | Medullary thyroid cancer, pheochromocytoma |
| **Anti-oncogenes (tumor suppressors)** | |
| *APC/β catenin* | Colorectal cancer, pancreatic cancer |
| *BRCA1, BRCA2* | Breast cancer, ovarian cancer |
| *NF1* | Neuroblastoma, sarcoma |
| *RB* | Retinoblastoma, osteosarcoma |
| *VHL* | Renal cell cancer |
| *WT1* | Wilms tumor |

This patient has **medullary thyroid cancer** (MTC) presenting with a palpable nodule and elevated serum calcitonin. MTC is a neuroendocrine tumor that arises from **calcitonin-secreting** C (parafollicular) cells. Microscopy shows nests or sheets of polygonal or spindle-shaped cells, often with extracellular amyloid deposition (consisting of full-length calcitonin). MTC is often seen in the context of multiple endocrine neoplasia type 2

This patient has **medullary thyroid cancer** (MTC) presenting with a palpable nodule and elevated serum calcitonin. MTC is a neuroendocrine tumor that arises from **calcitonin-secreting** C (parafollicular) cells. Microscopy shows nests or sheets of polygonal or spindle-shaped cells, often with extracellular amyloid deposition (consisting of full-length calcitonin). MTC is often seen in the context of multiple endocrine neoplasia type 2 (A and B), although the majority of cases are sporadic. Paraneoplastic symptoms (eg, diarrhea, flushing) can occur due to elevated calcitonin levels; however, calcium is usually normal, possibly due to the downregulation of calcitonin receptors.

MTC is associated with activating mutations in the ***RET* proto-oncogene**; mutations are commonly found in sporadic MTC, and germline mutations are present in more than 95% of patients with familial MTC. The *RET* proto-oncogene codes for a membrane-bound **tyrosine kinase receptor** involved in cell cycle regulation. In patients with MTC, **constitutive activation** of the receptor leads to unregulated cellular proliferation.

**(Choice A)** The anaplastic lymphoma kinase (*ALK*) oncogene codes for a transmembrane receptor tyrosine kinase. Mutations are common in anaplastic large cell lymphoma and non–small cell lung cancer.

**(Choice C)** The *MEN1* gene codes for a tumor suppressor protein. Mutations are associated with multiple endocrine neoplasia type 1 (pituitary adenomas, primary hyperparathyroidism, pancreatic neuroendocrine tumors) but not type 2.

**(Choice D)** p53 is a tumor suppressor protein involved in DNA repair, apoptosis, and cell cycle control. Inactivating mutations or deletions are present in a large percentage of human tumors, including anaplastic thyroid cancer, but not typically in early-stage MTC.

**(Choice E)** *BCL2* (B-cell lymphoma 2) is an antiapoptotic gene that enhances cell survival. Its expression is upregulated in many cancer cells. *BCL2* mutations are common in many follicular lymphomas.

**(Choice F)** Mutations in *JAK2* (Janus kinase 2) are seen in a variety of myeloproliferative disorders such as primary polycythemia and essential thrombocythemia.

**Educational objective:**
Medullary thyroid cancer is a neuroendocrine tumor that arises from calcitonin-secreting C (parafollicular) cells. It is often seen in the context of multiple endocrine neoplasia type 2 (A and B), although the majority of cases are sporadic. Both sporadic and familial medullary thyroid cancers are associated with mutations in the *RET* proto-oncogene.

**References**

- Diversity of mutations in the RET proto-oncogene and its oncogenic mechanism in medullary thyroid cancer.

This patient has **medullary thyroid cancer** (MTC) presenting with a palpable nodule and elevated serum calcitonin. MTC is a neuroendocrine

**Exhibit Display**

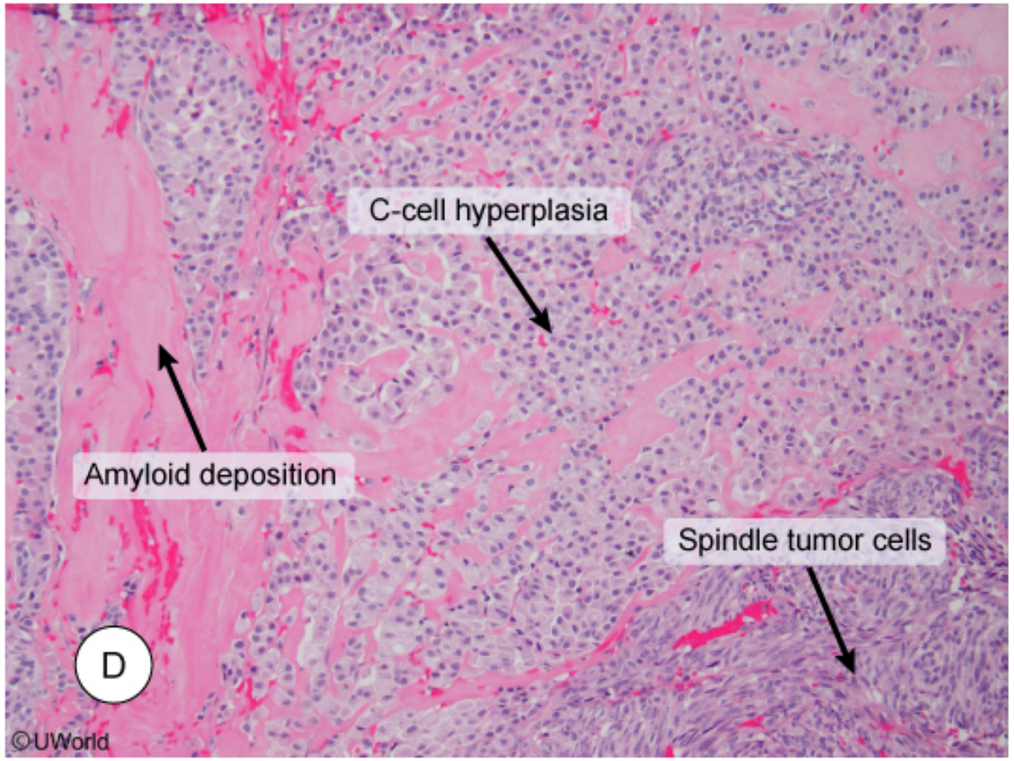


Zoom In | Zoom Out | Reset | Add To New Card | Existing Card

- Diversity of mutations in the RET proto-oncogene and its oncogenic mechanism in medullary thyroid cancer.

A 27-year-old woman comes to the office for evaluation of infertility. The patient and her husband have been trying to conceive for the past 2 years but have been unsuccessful. Her husband recently underwent infertility evaluation and was found to have no abnormalities. The patient's menses began at age 13, and her menstrual cycles were regular until the last few years, when they began occurring at intervals of 3-4 months. She has occasional headaches but no other symptoms. The patient has no prior medical conditions and takes no medications. On physical examination, the patient appears normal and has well-developed secondary sexual characteristics. Cardiopulmonary and abdominal examinations are normal. Pelvic examination reveals no adnexal masses. Neurological examination shows diminished vision in the bilateral temporal visual fields. Examination of the other cranial nerves is normal and there is no focal weakness or sensory loss. An abnormality originating in which of the following is the most likely cause of this patient's current condition?

- A. Hypothalamic neurons
- B. Ovarian granulosa cells
- C. Ovarian theca cells
- D. Pituitary lactotrophs
- E. Pituitary somatotrophs

Submit

A 27-year-old woman comes to the office for evaluation of infertility. The patient and her husband have been trying to conceive for the past 2 years but have been unsuccessful. Her husband recently underwent infertility evaluation and was found to have no abnormalities. The patient's menses began at age 13, and her menstrual cycles were regular until the last few years, when they began occurring at intervals of 3-4 months. She has occasional headaches but no other symptoms. The patient has no prior medical conditions and takes no medications. On physical examination, the patient appears normal and has well-developed secondary sexual characteristics. Cardiopulmonary and abdominal examinations are normal. Pelvic examination reveals no adnexal masses. Neurological examination shows diminished vision in the bilateral temporal visual fields. Examination of the other cranial nerves is normal and there is no focal weakness or sensory loss. An abnormality originating in which of the following is the most likely cause of this patient's current condition?

- A. Hypothalamic neurons (3%)
- B. Ovarian granulosa cells (0%)
- C. Ovarian theca cells (1%)
- ✓ D. Pituitary lactotrophs (85%)
- E. Pituitary somatotrophs (8%)

Omitted
Correct answer
D

85%
Answered correctly

02 secs
Time Spent

02/16/2020
Last Updated

Explanation

**Prolactin & amenorrhea**

1
2
3
4
5
6
7
8
9
10
11
12
13
14
15
16
17
18
19
20
21
22
23
24
25
26
27
28
29
30
31

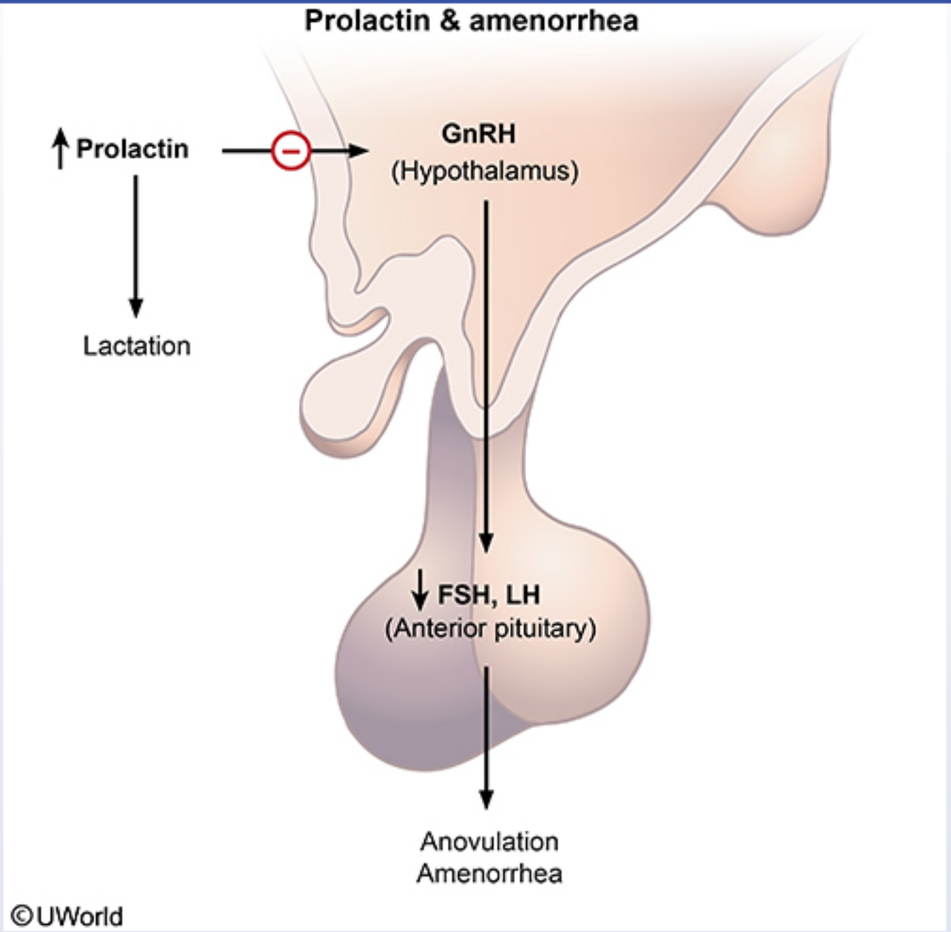


This patient's symptoms are concerning for a **pituitary tumor**. Large pituitary tumors can cause **headaches** due to mass effect, and compression of the optic chiasm by suprasellar extension of the tumor can lead to bitemporal hemianopsia.

The most common type of pituitary adenoma is a **prolactinoma**. Prolactin is a peptide hormone secreted from lactotrophs of the pituitary gland whose primary physiologic action is maintenance of lactation in postpartum women. Hyperprolactinemia also **suppresses GnRH production** in the hypothalamus, leading to **oligomenorrhea/amenorrhea** and infertility. Suppression of ovulation is also seen as a physiologic effect of breastfeeding, which supports elevated prolactin levels for 6 months or more postpartum.

©UWorld

This patient's symptoms are concerning for a **pituitary tumor**. Large pituitary tumors can cause **headaches** due to mass effect, and compression of the optic chiasm by suprasellar extension of the tumor can lead to bitemporal hemianopsia.

The most common type of pituitary adenoma is a **prolactinoma**. Prolactin is a peptide hormone secreted from lactotrophs of the pituitary gland whose primary physiologic action is maintenance of lactation in postpartum women. Hyperprolactinemia also **suppresses GnRH production** in the hypothalamus, leading to **oligomenorrhea/amenorrhea** and infertility. Suppression of ovulation is also seen as a physiologic effect of breastfeeding, which supports elevated prolactin levels for 6 months or more postpartum.

**(Choice A)** Kallmann syndrome is a disorder involving the GnRH-producing neurons in the hypothalamus. In addition to decreased sense of smell (anosmia/hyposomia), this condition causes hypogonadotropic hypogonadism and presents with short stature and delayed puberty (primary amenorrhea). This patient has secondary amenorrhea (ie, normal initial onset of puberty followed by menstrual dysregulation), and her bilateral temporal visual deficits are more suggestive of a pituitary rather than hypothalamic lesion.

**(Choice B)** Ovarian granulosa cells produce estrogen, progesterone, and inhibin. Loss of these cells (eg, due to autoimmune disorder) can lead to primary ovarian insufficiency and present with infertility and secondary amenorrhea. However, patients often have hypoestrogenic symptoms (eg, hot flashes), and this disorder would not cause visual field defects.

**(Choice C)** Ovarian theca cells produce androgens, which provide the substrate for subsequent synthesis of estrogens. Amenorrhea and infertility related to hyperactivity of these cells are typically associated with signs of hyperandrogenism (eg, hirsutism).

**(Choice E)** Unlike most pituitary hormones, which are under positive regulation by the hypothalamus, prolactin is primarily under negative regulation by hypothalamic dopaminergic neurons via the pituitary stalk. Because of this, any pituitary tumor of significant size that disrupts these dopaminergic pathways can cause moderate hyperprolactinemia. However, somatotroph adenomas typically cause acromegaly, with prognathism and bony enlargement of the hands and feet.

**Educational objective:**
Prolactinomas are the most common pituitary adenoma and can cause galactorrhea, menstrual irregularities, and infertility in premenopausal women. Large pituitary adenomas can cause headaches from mass effect and bitemporal hemianopsia from compression of the optic chiasm.

**References**

- Progress in the diagnosis and classification of pituitary adenomas.

©UWorld

## Exhibit Display

### Visual pathways from above

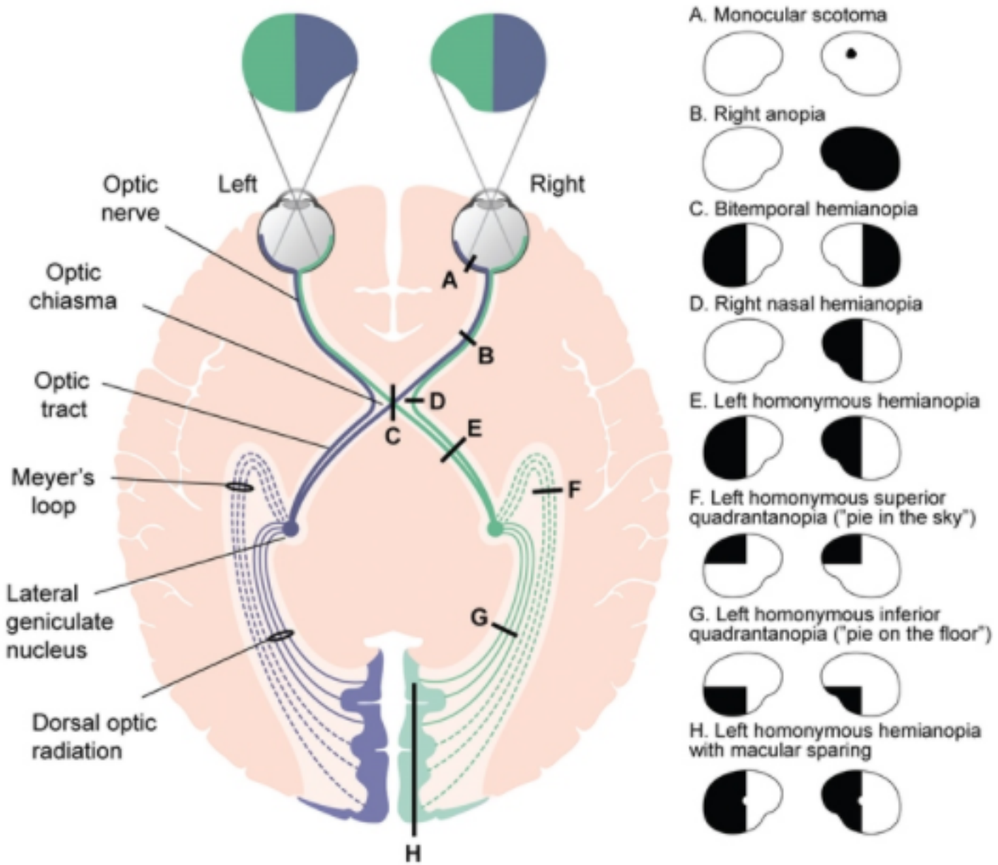


©UWorld

Zoom In Zoom Out Reset Add To New Card | Existing Card

- Progress in the diagnosis and classification of pituitary adenomas.

1
2
3
4
5
6
7
8
9
10
11
12
13
14
15
16
17
18
19
20
21
22
23
24
25
26
27
28
29
30
31

A 35-year-old woman is evaluated for a 3-month history of appetite loss, fatigue, weight loss, and abdominal pain. She has no chronic medical conditions and takes no medications. While undergoing upper gastrointestinal endoscopy, the patient develops cardiovascular collapse and dies, despite aggressive resuscitative measures. On autopsy, increased pigmentation is noted around the nipple areola and anal and vaginal mucous membranes. Which of the following additional findings are most likely to be seen on autopsy?

A. Atrophy of both adrenal glands

B. Bilateral adrenal hemorrhage

C. Ischemic anterior pituitary necrosis

D. Large pituitary tumor with hemorrhage

E. Unilateral adrenal mass with contralateral adrenal atrophy

Submit

A 35-year-old woman is evaluated for a 3-month history of appetite loss, fatigue, weight loss, and abdominal pain. She has no chronic medical conditions and takes no medications. While undergoing upper gastrointestinal endoscopy, the patient develops cardiovascular collapse and dies, despite aggressive resuscitative measures. On autopsy, increased pigmentation is noted around the nipple areola and anal and vaginal mucous membranes. Which of the following additional findings are most likely to be seen on autopsy?

- ✓ A. Atrophy of both adrenal glands (52%)
- B. Bilateral adrenal hemorrhage (18%)
- C. Ischemic anterior pituitary necrosis (4%)
- D. Large pituitary tumor with hemorrhage (12%)
- E. Unilateral adrenal mass with contralateral adrenal atrophy (12%)

Omitted
Correct answer
A

52%
Answered correctly

02 secs
Time Spent

05/06/2020
Last Updated

Explanation

| Primary adrenal insufficiency | |
|---|---|
| **Etiology** | • **Autoimmune adrenalitis** (most common)<br>• Infection (eg, tuberculosis)<br>• Hemorrhagic infarction |
| | • Fatigue, weakness, anorexia/weight loss |

| Primary adrenal insufficiency | |
|---|---|
| **Etiology** | • **Autoimmune adrenalitis** (most common)<br>• Infection (eg, tuberculosis)<br>• Hemorrhagic infarction |
| **Clinical features** | • Fatigue, weakness, anorexia/weight loss<br>• Nausea/vomiting/abdominal pain<br>• Postural hypotension<br>• Hyperpigmentation<br>• **Acute adrenal crisis:** confusion, shock |
| **Laboratory findings** | • Hyponatremia, hyperkalemia<br>• Low morning cortisol, high ACTH<br>• Eosinophilia |

This patient with a three month history of weight loss, abdominal pain, and fatigue developed cardiovascular collapse during a medical procedure (endoscopy), which suggests **chronic adrenal insufficiency** complicated by **acute adrenal crisis**. Severe physiologic stress (eg, infection, medical procedures) normally induces increased glucocorticoid production; however, patients with adrenal insufficiency are unable to increase production. Adrenal crisis (eg, hypotension, shock) is rapidly fatal if unrecognized.

Adrenal insufficiency can be caused by dysfunction of either the adrenal glands (primary) or pituitary (secondary). This patient's concomitant **skin hyperpigmentation** is highly suggestive of chronic **primary adrenal insufficiency** (PAI), as the resulting cortisol deficiency leads to increased ACTH secretion. ACTH is derived from proopiomelanocortin (POMC), the same prohormone from which melanocyte-stimulating hormone (MSH) is derived. Increased ACTH also leads to increased MSH secretion, which results in hyperpigmentation.

**Autoimmune adrenalitis** is the most common cause (>90%) of chronic PAI and occurs due to autoantibody formation, resulting in **atrophy of the bilateral adrenal glands**. It can occur as an isolated disorder or in association with other autoimmune syndromes (eg, hypothyroidism, vitiligo).

**(Choice B)** Bilateral adrenal hemorrhage (Waterhouse-Friderichsen syndrome [WFS]) can cause PAI and adrenal crisis but is typically seen

This patient with a three month history of weight loss, abdominal pain, and fatigue developed cardiovascular collapse during a medical procedure (endoscopy), which suggests **chronic adrenal insufficiency** complicated by **acute adrenal crisis**. Severe physiologic stress (eg, infection, medical procedures) normally induces increased glucocorticoid production; however, patients with adrenal insufficiency are unable to increase production. Adrenal crisis (eg, hypotension, shock) is rapidly fatal if unrecognized.

Adrenal insufficiency can be caused by dysfunction of either the adrenal glands (primary) or pituitary (secondary). This patient's concomitant **skin hyperpigmentation** is highly suggestive of chronic **primary adrenal insufficiency** (PAI), as the resulting cortisol deficiency leads to increased ACTH secretion. ACTH is derived from proopiomelanocortin (POMC), the same prohormone from which melanocyte-stimulating hormone (MSH) is derived. Increased ACTH also leads to increased MSH secretion, which results in hyperpigmentation.

**Autoimmune adrenalitis** is the most common cause (>90%) of chronic PAI and occurs due to autoantibody formation, resulting in **atrophy of the bilateral adrenal glands**. It can occur as an isolated disorder or in association with other autoimmune syndromes (eg, hypothyroidism, vitiligo).

**(Choice B)** Bilateral adrenal hemorrhage (Waterhouse-Friderichsen syndrome [WFS]) can cause PAI and adrenal crisis but is typically seen *acutely* in the setting of bacterial sepsis (eg, *Neisseria meningitidis*). However, hyperpigmentation occurs in *chronic* adrenal insufficiency and therefore would not be expected with WFS.

**(Choices C and D)** Ischemic necrosis of the pituitary (Sheehan syndrome) most commonly occurs due to hypoperfusion of the enlarged pituitary gland during childbirth. Acute pituitary hemorrhage (pituitary apoplexy) typically occurs in patients with pituitary adenomas. These conditions can cause central (secondary) adrenal insufficiency; however, hyperpigmentation is not seen because ACTH levels are low, and POMC levels are not increased.

**(Choice E)** A cortisol-producing adrenal tumor can cause contralateral adrenal atrophy due to suppression of ACTH secretion; however, it would not be associated with hyperpigmentation and would manifest as hypercortisolism rather than adrenal insufficiency.

**Educational objective:**
Primary adrenal insufficiency (PAI) is characterized by weight loss, abdominal pain, fatigue, and hyperpigmentation. Physiologic stress in patients with PAI can trigger acute adrenal crisis (eg, fever, shock, mental status changes). Autoimmune adrenalitis is the most common cause of PAI and leads to bilateral adrenal atrophy.

**References**

- Diagnosis and classification of Addison's disease (autoimmune adrenalitis).

**hyperpigmentation** is highly suggestive of chronic **primary adrenal insufficiency** (PAI), as the resulting cortisol deficiency leads to increased

Exhibit Display

Features of Cushing syndrome

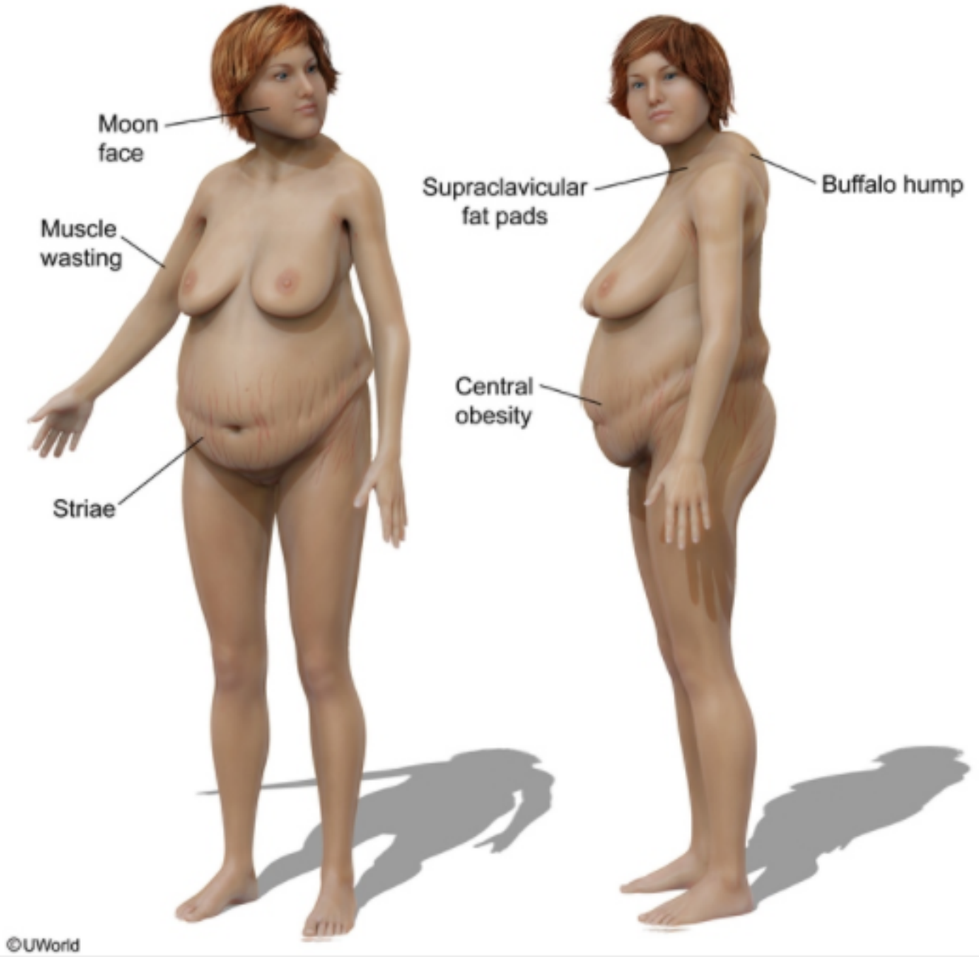


Zoom In Zoom Out Reset Add To Flash Card

1
2
3
4
5
6
7
8
9
10
11
12
13
14
15
16
17
18
19
20
21
22
23
24
25
26
27
28
29
30
31

A 53-year-old woman comes to the physician for a routine check-up. She has no current complaints. Her past medical history is significant for osteoarthritis of the right knee. Her mother suffered from hypertension and was diagnosed with breast cancer at age 68, from which she died 4 years later. Her father had diabetes mellitus and died in a motor vehicle accident at age 56. The patient's blood pressure is 140/85 mm Hg and heart rate is 80/min. Physical examination is normal. Laboratory testing is significant for a fasting blood glucose level of 140 mg/dL on more than 2 occasions. This patient is most likely to die from which of the following conditions?

A. Breast cancer

B. Hyperosmolar nonketotic coma

C. Myocardial infarction

D. Renal failure

E. Stroke

Submit

A 53-year-old woman comes to the physician for a routine check-up. She has no current complaints. Her past medical history is significant for osteoarthritis of the right knee. Her mother suffered from hypertension and was diagnosed with breast cancer at age 68, from which she died 4 years later. Her father had diabetes mellitus and died in a motor vehicle accident at age 56. The patient's blood pressure is 140/85 mm Hg and heart rate is 80/min. Physical examination is normal. Laboratory testing is significant for a fasting blood glucose level of 140 mg/dL on more than 2 occasions. This patient is most likely to die from which of the following conditions?

A. Breast cancer (6%)

B. Hyperosmolar nonketotic coma (3%)

✓ C. Myocardial infarction (61%)

D. Renal failure (23%)

E. Stroke (5%)

Omitted
Correct answer
C

61%
Answered correctly

02 secs
Time Spent

04/05/2020
Last Updated

Explanation

| Risk factors for coronary heart disease | |
|---|---|
| Highest risk factors (coronary heart | • Noncoronary atherosclerotic disease<br>• Diabetes mellitus |

| Risk factors for coronary heart disease | |
|---|---|
| **Highest risk factors (coronary heart disease equivalents)** | • Noncoronary atherosclerotic disease<br>• Diabetes mellitus<br>• Chronic kidney disease |
| **Major risk factors** | • Hypertension<br>• Hyperlipidemia (↑LDL & triglycerides)<br>• Cigarette smoking<br>• Advanced age<br>• Obesity<br>• Physical inactivity |

©UWorld

Several studies have shown that diabetes mellitus is one of the strongest risk factors for coronary heart disease. Cardiovascular mortality is increased by 2- to 4-fold in patients with type 2 diabetes mellitus, and approximately 40% of patients die secondary to coronary heart disease. For a person with type 2 diabetes mellitus, the risk of dying from coronary heart disease exceeds the risk of dying from any of the other listed causes, even in the absence of other major risk factors for coronary heart disease.

**(Choice A)** The risk of breast cancer is not increased in patients with diabetes mellitus. Although this patient has a family history of breast cancer, her risk is not significantly increased since her mother was at an advanced age when the cancer occurred.

**(Choice B)** Diabetic ketoacidosis (DKA) and hyperosmolar coma are acute complications of untreated diabetes mellitus. Hyperosmolar coma is seen mainly with type 2 diabetes mellitus and is characterized by very high blood sugar levels without ketoacidosis. The mortality of hyperosmolar coma is higher than DKA; however, very few patients with diabetes die directly from DKA or hyperosmolar coma.

**(Choice D)** Diabetes mellitus is the leading cause of end-stage renal disease (ESRD), followed by hypertension. However, approximately 50% of patients with ESRD die due to cardiovascular disease, with infections being the next most common cause.

**(Choice E)** The risk of stroke is increased in patients with diabetes mellitus. However, cerebrovascular accidents account for about 10% of total

| | |
|---|---|
| | • Obesity<br>• Physical inactivity |

©UWorld

Several studies have shown that diabetes mellitus is one of the strongest risk factors for coronary heart disease. Cardiovascular mortality is increased by 2- to 4-fold in patients with type 2 diabetes mellitus, and approximately 40% of patients die secondary to coronary heart disease. For a person with type 2 diabetes mellitus, the risk of dying from coronary heart disease exceeds the risk of dying from any of the other listed causes, even in the absence of other major risk factors for coronary heart disease.

**(Choice A)** The risk of breast cancer is not increased in patients with diabetes mellitus. Although this patient has a family history of breast cancer, her risk is not significantly increased since her mother was at an advanced age when the cancer occurred.

**(Choice B)** Diabetic ketoacidosis (DKA) and hyperosmolar coma are acute complications of untreated diabetes mellitus. Hyperosmolar coma is seen mainly with type 2 diabetes mellitus and is characterized by very high blood sugar levels without ketoacidosis. The mortality of hyperosmolar coma is higher than DKA; however, very few patients with diabetes die directly from DKA or hyperosmolar coma.

**(Choice D)** Diabetes mellitus is the leading cause of end-stage renal disease (ESRD), followed by hypertension. However, approximately 50% of patients with ESRD die due to cardiovascular disease, with infections being the next most common cause.

**(Choice E)** The risk of stroke is increased in patients with diabetes mellitus. However, cerebrovascular accidents account for about 10% of total mortality in patients with type 2 diabetes mellitus versus 40% from coronary heart disease.

**Educational objective:**
Patients with **noncoronary atherosclerotic disease**, **diabetes mellitus**, or **chronic kidney disease** are at the same risk of cardiovascular events (eg, myocardial infarction, stroke) as patients with known coronary heart disease. Coronary heart disease is the most common cause of death in patients with diabetes mellitus.

| Pathology | Endocrine, Diabetes & Metabolism | Diabetes mellitus |
|---|---|---|
| Subject | System | Topic |

Copyright © UWorld. All rights reserved.

1
2
3
4
5
6
7
8
9
10
11
12
13
14
15
16
17
18
19
20
21
22
23
24
25
26
27
28
29
30
31

A 45-year-old man comes to the office due to slowly progressive back and joint pain. In particular, his knee and ankle joints are stiff and painful when he walks. Over the past year, the patient has also experienced excessive sweating, and his ring and shoe sizes have increased. He has no prior medical issues and takes no medications. The patient does not use tobacco, alcohol, or illicit drugs. There is no significant family history. Physical examination shows coarse facial features with a prominent forehead, protruding jaw, and widely separated maxillary teeth. There is mild swelling and crepitus of the knees and ankles bilaterally. Which of the following is most likely to be associated with this patient's condition?

A. Aortic root dilation

B. Bicuspid aortic valve

C. Left ventricular hypertrophy

D. Mitral valve prolapse

E. Pericardial effusion

Submit

1
2
3
4
5
6
7
8
9
10
11
12
13
14
15
16
17
18
19
20
21
22
23
24
25
26
27
28
29
30
31

A 45-year-old man comes to the office due to slowly progressive back and joint pain. In particular, his knee and ankle joints are stiff and painful when he walks. Over the past year, the patient has also experienced excessive sweating, and his ring and shoe sizes have increased. He has no prior medical issues and takes no medications. The patient does not use tobacco, alcohol, or illicit drugs. There is no significant family history. Physical examination shows coarse facial features with a prominent forehead, protruding jaw, and widely separated maxillary teeth. There is mild swelling and crepitus of the knees and ankles bilaterally. Which of the following is most likely to be associated with this patient's condition?

A. Aortic root dilation (18%)

B. Bicuspid aortic valve (3%)

✓ C. Left ventricular hypertrophy (66%)

D. Mitral valve prolapse (10%)

E. Pericardial effusion (2%)

Omitted
Correct answer
C

66%
Answered correctly

02 secs
Time Spent

02/06/2020
Last Updated

Explanation

1
2
3
4
5
6
7
8
9
10
11
12
13
14
15
16
17
18
19
20
21
22
23
24
25
26
27
28
29
30
31

## Acromegaly

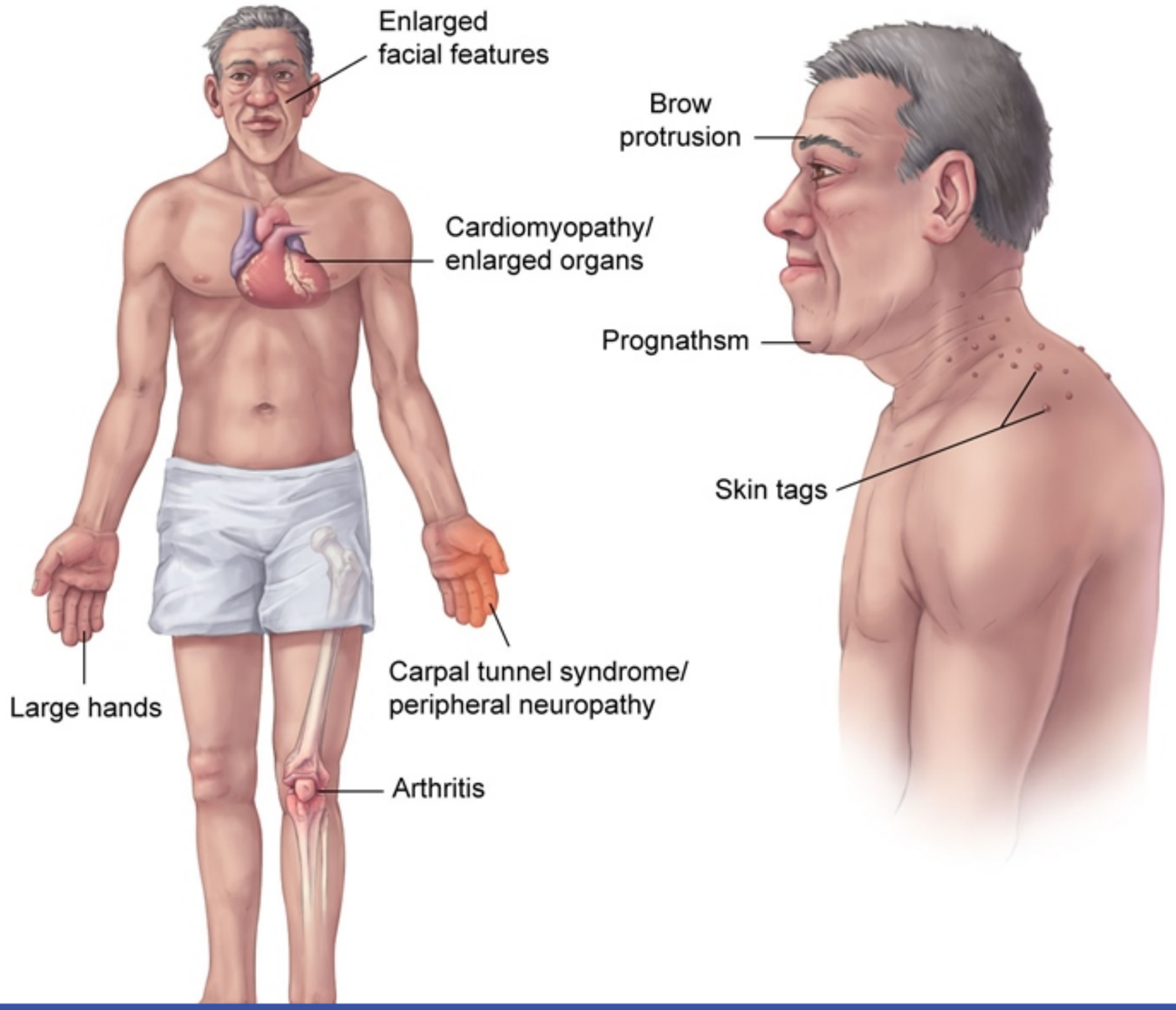

1
2
3
4
5
6
7
8
9
10
11
12
13
14
15
16
17
18
19
20
21
22
23
24
25
26
27
28
29
30
31

This patient has bony overgrowth (ie, frontal bossing; enlarged jaw, hands, and feet) consistent with acromegaly. **Acromegaly** is caused by excessive production of **growth hormone** (GH) and is most often due to a pituitary somatotroph adenoma. Excess GH both directly and indirectly (via release of insulin-like growth factor 1 from the liver) leads to overgrowth of many tissues, including bone, cartilage, and visceral organs.

In the heart, chronic GH elevation stimulates cardiac growth, causing **left ventricular hypertrophy**, diastolic dysfunction, and possible heart failure. The joints are also frequently involved in acromegaly, as excessive GH causes hyperplasia of articular chondrocytes and synovial hypertrophy, leading to wear and degeneration of articular cartilage and periarticular bone (hypertrophic **arthropathy**). Soft tissue involvement is also common and manifests as macroglossia, deepening of the voice (due to laryngeal soft tissue growth), carpal tunnel syndrome, and peripheral neuropathy.

**(Choices A and D)** Marfan syndrome is an inherited condition caused by a defect in fibrillin-1. Cardiovascular complications include cystic medial degeneration of the aorta (with aneurysmal dilation and dissection), aortic regurgitation, and mitral valve prolapse. However, unlike the bony enlargement in acromegaly, the typical marfanoid habitus is characterized by a tall, slender build and an increased ratio of limb length-to-height.

**(Choice B)** Ehlers-Danlos syndrome is due to an autosomal recessive defect in lysyl hydroxylase, which leads to defects in connective tissues (eg, fragile, hyperextensible skin). Musculoskeletal manifestations include hypermobile joints, pectus excavatum, and scoliosis. Valvular heart disease is common and can present as bicuspid aortic valve or mitral/tricuspid valve prolapse.

**(Choice E)** Patients with untreated hypothyroidism can have a pericardial effusion, and also frequently have nonpitting edema (myxedema) due to excessive deposition of mucopolysaccharides and adipogenesis in the dermis and subcutaneous tissues. However, bony enlargement is not characteristic.

**Educational objective:**
Acromegaly is caused by excessive production of growth hormone, usually due to a pituitary somatotroph adenoma. Musculoskeletal manifestations include bony hypertrophy (eg, frontal bossing; enlarged jaw, hands, and feet) and osteoarthritis. Left ventricular hypertrophy is often common in acromegaly and may progress to heart failure.

**References**

- GH and the cardiovascular system: an update on a topic at heart.

Pathology | Endocrine, Diabetes & Metabolism | Acromegaly

This patient has bony overgrowth (ie, frontal bossing; enlarged jaw, hands, and feet) consistent with acromegaly. **Acromegaly** is caused by

Exhibit Display

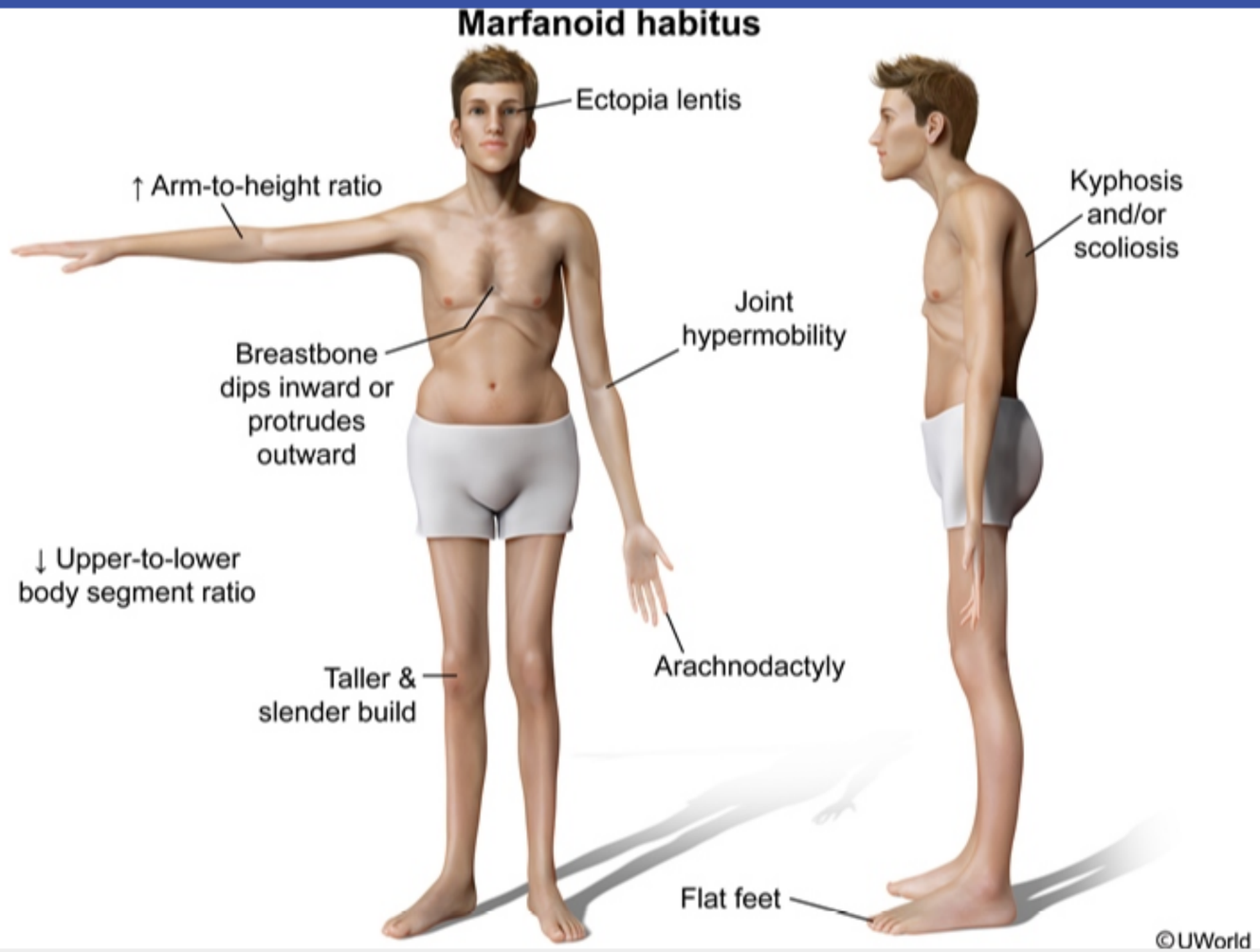


Zoom In | Zoom Out | Reset | Add To New Card | Existing Card

Pathology | Endocrine, Diabetes & Metabolism | Acromegaly

1
2
3
4
5
6
7
8
9
10
11
12
13
14
15
16
17
18
19
20
21
22
23
24
25
26
27
28
29
30
31

A 61-year-old woman comes to the office due to a neck lump. She is otherwise in good health and has no other symptoms. Temperature is 36.7 C (98 F), blood pressure is 115/70 mm Hg, and pulse is 78/min. On physical examination, there is a nontender, firm nodule in the left lobe of the thyroid. Laboratory results show a normal serum TSH level. Thyroid ultrasonography reveals a 2-cm, hypoechoic thyroid nodule with increased central blood flow. Fine-needle aspiration biopsy shows clusters of cells with large, overlapping nuclei containing sparse, finely dispersed chromatin. Numerous intranuclear inclusion bodies and grooves are also seen. Which of the following is the most likely diagnosis in this patient?

A. Anaplastic carcinoma
B. Colloid nodule
C. Follicular adenoma
D. Follicular carcinoma
E. Medullary carcinoma
F. Papillary carcinoma

Submit

A 61-year-old woman comes to the office due to a neck lump. She is otherwise in good health and has no other symptoms. Temperature is 36.7 C (98 F), blood pressure is 115/70 mm Hg, and pulse is 78/min. On physical examination, there is a nontender, firm nodule in the left lobe of the thyroid. Laboratory results show a normal serum TSH level. Thyroid ultrasonography reveals a 2-cm, hypoechoic thyroid nodule with increased central blood flow. Fine-needle aspiration biopsy shows clusters of cells with large, overlapping nuclei containing sparse, finely dispersed chromatin. Numerous intranuclear inclusion bodies and grooves are also seen. Which of the following is the most likely diagnosis in this patient?

- A. Anaplastic carcinoma (12%)
- B. Colloid nodule (1%)
- C. Follicular adenoma (10%)
- D. Follicular carcinoma (9%)
- E. Medullary carcinoma (9%)
- ✓ F. Papillary carcinoma (55%)

Omitted
Correct answer
F

55%
Answered correctly

02 secs
Time Spent

03/22/2020
Last Updated

Explanation

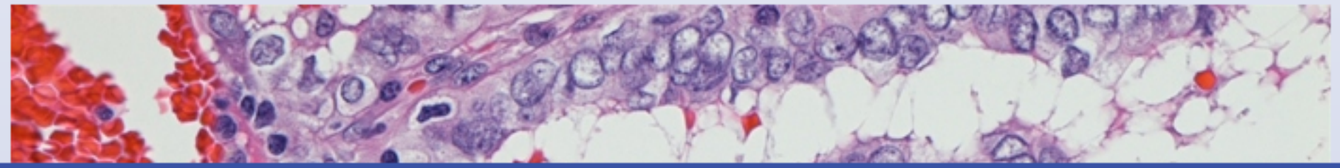

1
2
3
4
5
6
7
8
9
10
11
12
13
14
15
16
17
18
19
20
21
22
23
24
25
26
27
28
29
30
31

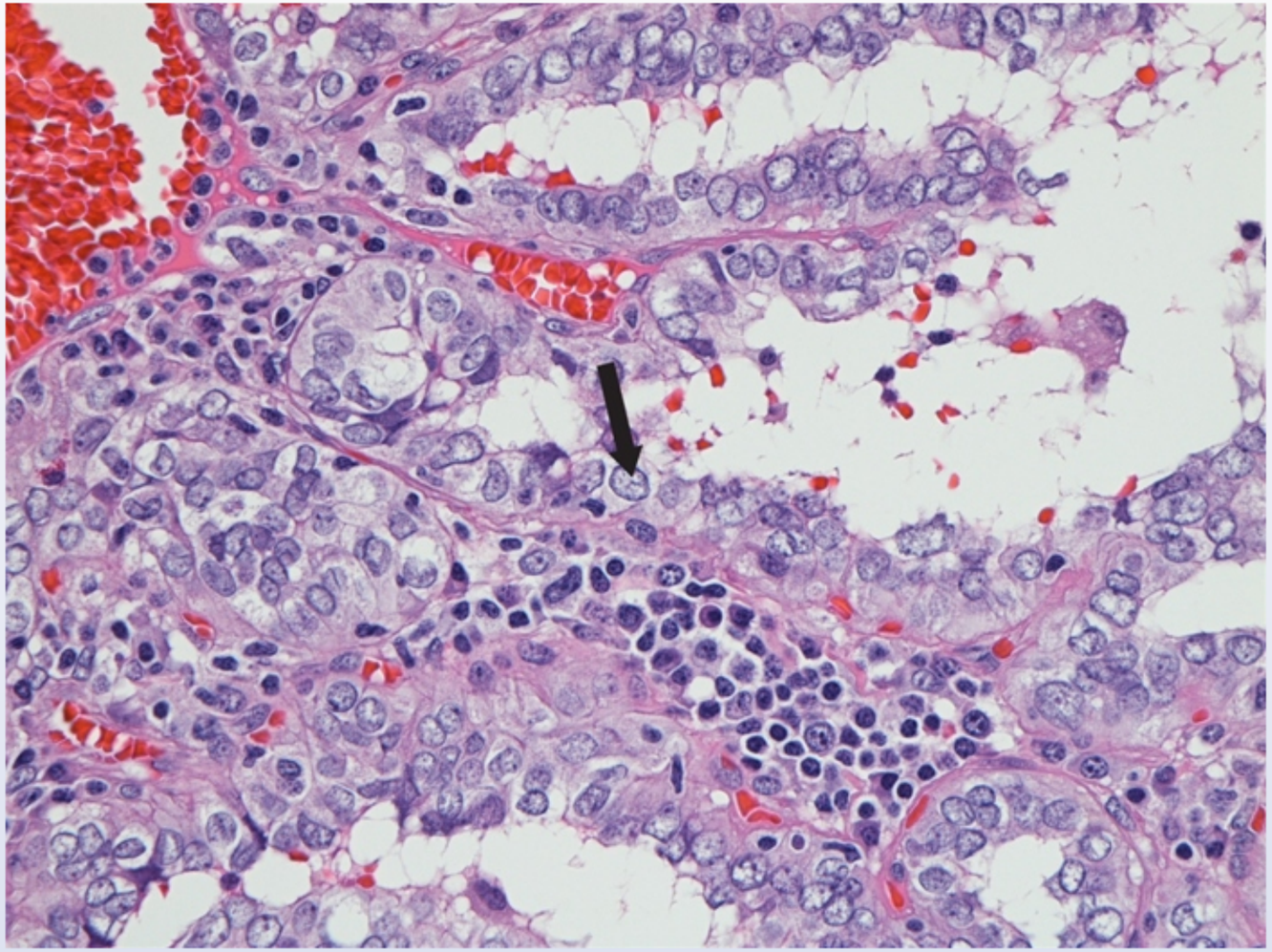

The 4 main types of primary thyroid carcinoma include papillary, follicular, medullary (derived from the parafollicular calcitonin-secreting C cells), and anaplastic. The papillary type is most common, accounting for >70% of cases. Risk factors include a positive family history of thyroid cancer and radiation exposure (especially during childhood).

1
2
3
4
5
6
7
8
9
10
11
12
13
14
15
16
17
18
19
20
21
22
23
24
25
26
27
28
29
30
31



The 4 main types of primary thyroid carcinoma include papillary, follicular, medullary (derived from the parafollicular calcitonin-secreting C cells), and anaplastic. The papillary type is most common, accounting for >70% of cases. Risk factors include a positive family history of thyroid cancer and radiation exposure (especially during childhood).

**Papillary carcinoma** cells are characteristically large with overlapping nuclei containing **finely dispersed chromatin**, giving them an empty or ground-glass appearance (sometimes termed **Orphan Annie eye** nuclei after a cartoon character whose eyes were drawn without pupils or irises). Numerous **intranuclear inclusions and grooves** (arrow) can be seen due to invagination of the nuclear membrane. Psammoma bodies (laminated calcium deposits) may also be found within the tumor.

**(Choice A)** Anaplastic thyroid cancer is an aggressive tumor with a very poor prognosis. It is most common in older patients (age >60). Cytologic features include markedly pleomorphic cells, including irregular giant cells and biphasic spindle cells.

**(Choice B)** Most benign thyroid nodules are colloid nodules formed from focal hyperplasia of normal thyroid follicular cells. On cytopathology, a colloid nodule consists of variable-sized thyroid follicles, colloid, and macrophages.

**(Choices C and D)** Follicular neoplasms lack the characteristic nuclear features and psammoma bodies found in papillary tumors. Distinguishing a benign follicular adenoma from a well-differentiated follicular cancer depends on the presence of vascular and capsular invasion, which cannot be determined on a fine-needle aspiration specimen.

**(Choice E)** Medullary thyroid cancer appears histologically as polygonal or spindle-shaped cells with a slightly granular cytoplasm that stains for calcitonin. Extracellular amyloid deposits (arrow) consisting of calcitonin polypeptide may also be seen. Medullary thyroid cancer is a component of multiple endocrine neoplasia types 2A and 2B.

**Educational objective:**
Papillary thyroid cancer is the most common type of thyroid cancer. Characteristic findings on histopathology include large cells with nuclei containing finely dispersed chromatin, giving an empty or ground-glass appearance (Orphan Annie eye), and intranuclear inclusions or grooves.

**References**

- Thyroid fine needle aspiration cytology: a review of the National Cancer Institute state of the science symposium.

1
2
3
4
5
6
7
8
9
10
11
12
13
14
15
16
17
18
19
20
21
22
23
24
25
26
27
28
29
30
31

Exhibit Display

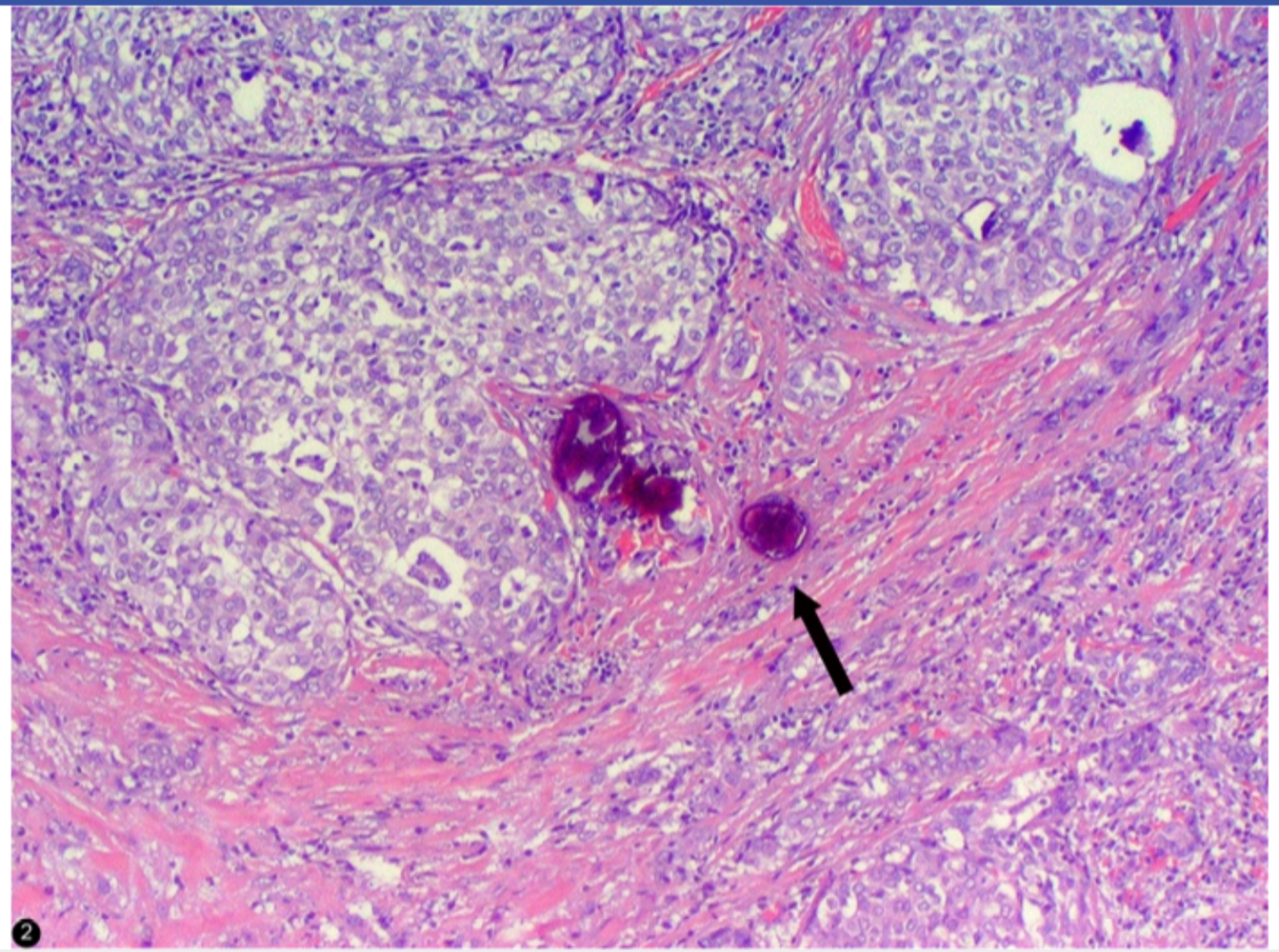

Zoom In | Zoom Out | Reset | Add To New Card | Existing Card

1
2
3
4
5
6
7
8
9
10
11
12
13
14
15
16
17
18
19
20
21
22
23
24
25
26
27
28
29
30
31

Exhibit Display

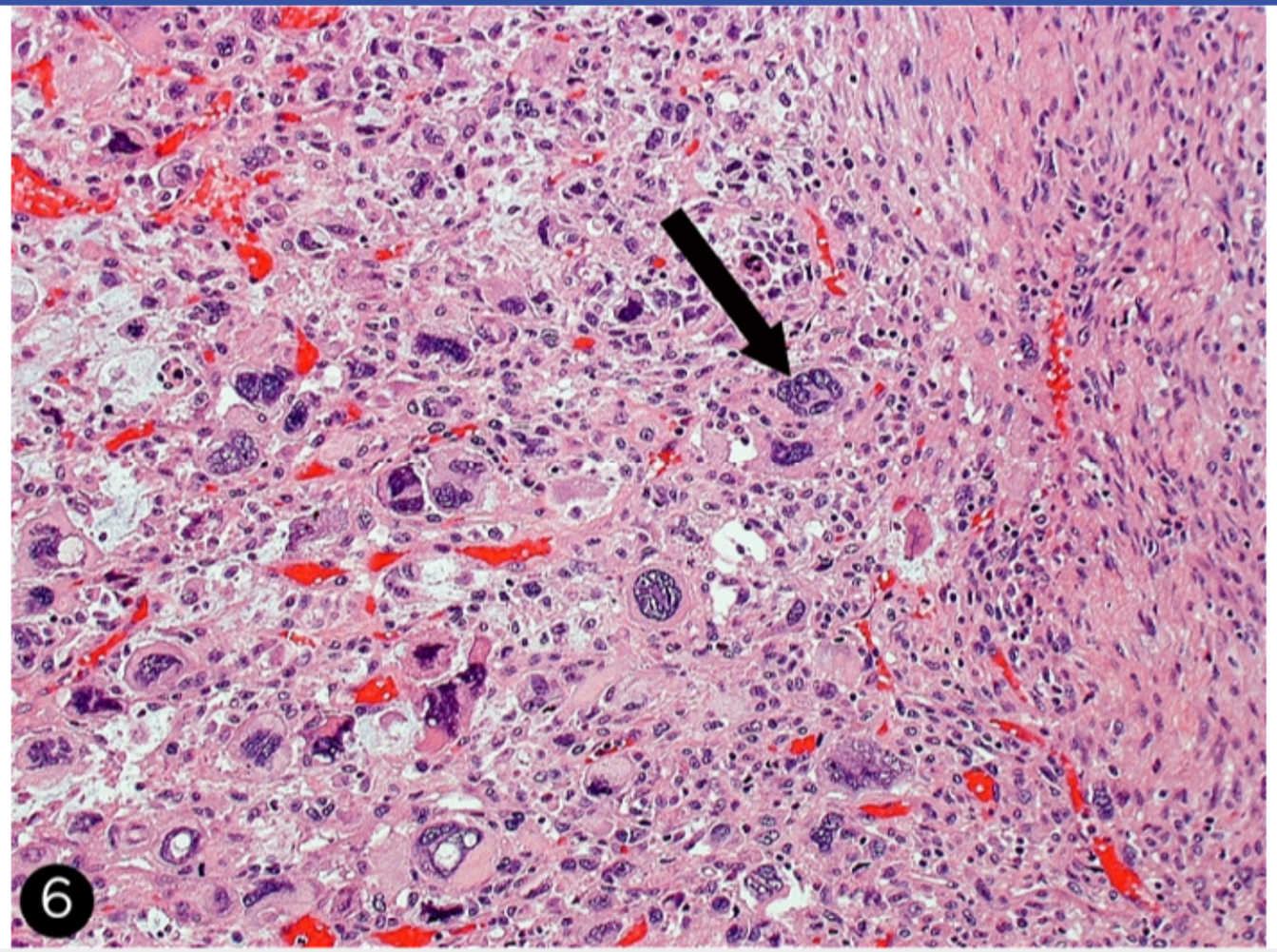


Zoom In
Zoom Out
Reset
Add To New Card | Existing Card

1
2
3
4
5
6
7
8
9
10
11
12
13
14
15
16
17
18
19
20
21
22
23
24
25
26
27
28
29
30
31

Exhibit Display

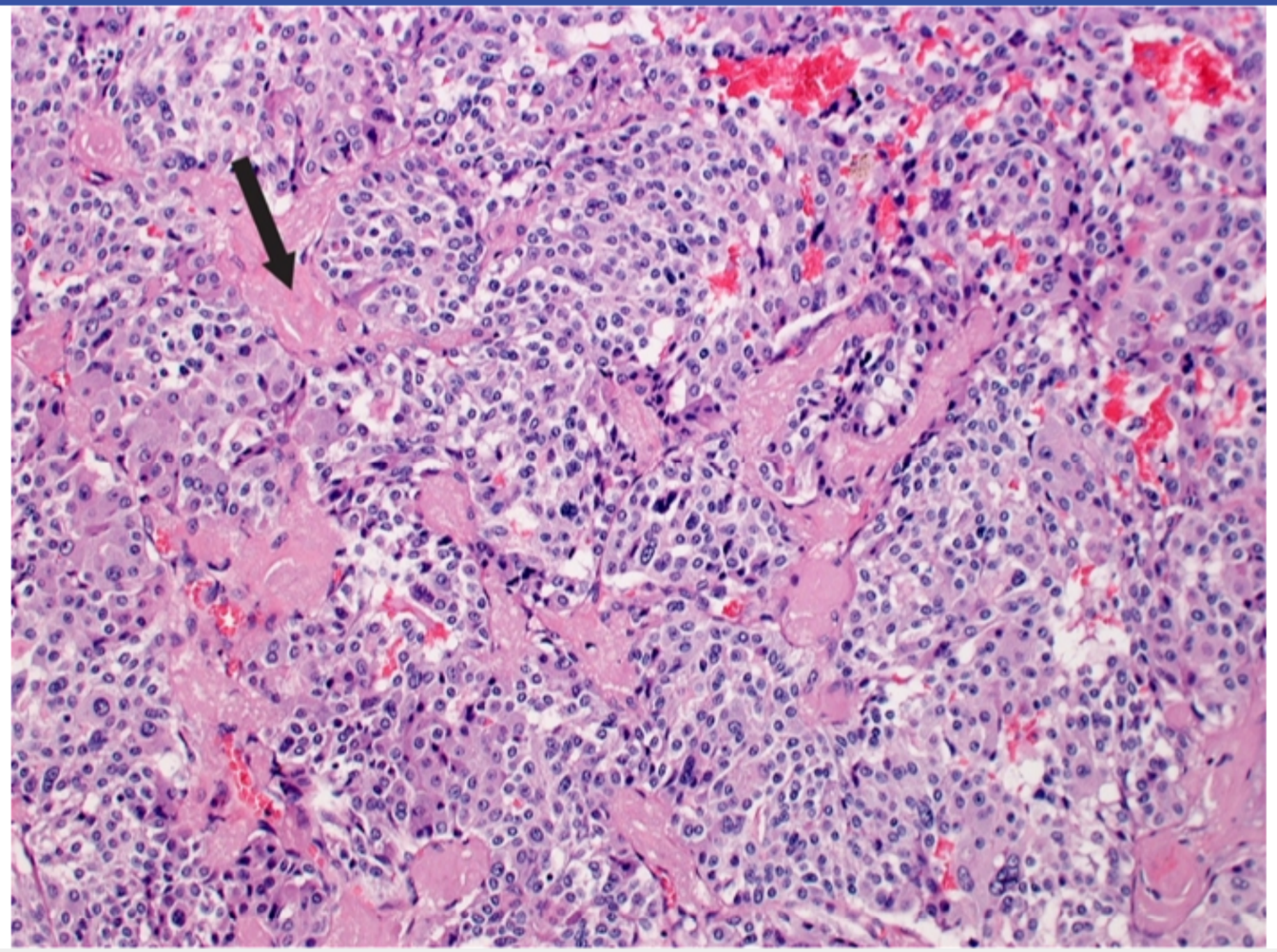

Zoom In | Zoom Out | Reset | Add To New Card | Existing Card

**Papillary carcinoma** cells are characteristically large with overlapping nuclei containing **finely dispersed chromatin**, giving them an empty or ground-glass appearance (sometimes termed **Orphan Annie eye** nuclei after a cartoon character whose eyes were drawn without pupils or irises). Numerous **intranuclear inclusions and grooves** (arrow) can be seen due to invagination of the nuclear membrane. Psammoma bodies (laminated calcium deposits) may also be found within the tumor.

**(Choice A)** Anaplastic thyroid cancer is an aggressive tumor with a very poor prognosis. It is most common in older patients (age >60). Cytologic features include markedly pleomorphic cells, including irregular giant cells and biphasic spindle cells.

**(Choice B)** Most benign thyroid nodules are colloid nodules formed from focal hyperplasia of normal thyroid follicular cells. On cytopathology, a colloid nodule consists of variable-sized thyroid follicles, colloid, and macrophages.

**(Choices C and D)** Follicular neoplasms lack the characteristic nuclear features and psammoma bodies found in papillary tumors. Distinguishing a benign follicular adenoma from a well-differentiated follicular cancer depends on the presence of vascular and capsular invasion, which cannot be determined on a fine-needle aspiration specimen.

**(Choice E)** Medullary thyroid cancer appears histologically as polygonal or spindle-shaped cells with a slightly granular cytoplasm that stains for calcitonin. Extracellular amyloid deposits (arrow) consisting of calcitonin polypeptide may also be seen. Medullary thyroid cancer is a component of multiple endocrine neoplasia types 2A and 2B.

**Educational objective:**
Papillary thyroid cancer is the most common type of thyroid cancer. Characteristic findings on histopathology include large cells with nuclei containing finely dispersed chromatin, giving an empty or ground-glass appearance (Orphan Annie eye), and intranuclear inclusions or grooves.

**References**

- Thyroid fine needle aspiration cytology: a review of the National Cancer Institute state of the science symposium.

| Pathology | Endocrine, Diabetes & Metabolism | Thyroid cancer |
|---|---|---|
| Subject | System | Topic |

Copyright © UWorld. All rights reserved.

1
2
3
4
5
6
7
8
9
10
11
12
13
14
15
16
17
18
19
20
21
22
23
24
25
26
27
28
29
30
31

A 6-year-old boy is brought to the emergency department after a traumatic fall from his bicycle. Physical examination shows a large laceration over his left leg that is irrigated and closed with sutures. While he is receiving care, a routine blood draw shows milky plasma that forms a creamy-appearing supernatant upon standing. Further testing shows that his plasma lipoprotein lipase activity measured after intravenous heparin administration is substantially lower than normal. If his condition remains untreated, this patient is most likely to develop which of the following features?

A. Acute pancreatitis

B. Intellectual disability

C. Myocardial infarction

D. Tendon xanthomas

E. Xanthelasmas

Submit

A 6-year-old boy is brought to the emergency department after a traumatic fall from his bicycle. Physical examination shows a large laceration over his left leg that is irrigated and closed with sutures. While he is receiving care, a routine blood draw shows milky plasma that forms a creamy-appearing supernatant upon standing. Further testing shows that his plasma lipoprotein lipase activity measured after intravenous heparin administration is substantially lower than normal. If his condition remains untreated, this patient is most likely to develop which of the following features?

- ✓ A. Acute pancreatitis (38%)
- B. Intellectual disability (1%)
- C. Myocardial infarction (20%)
- D. Tendon xanthomas (24%)
- E. Xanthelasmas (14%)

Omitted
Correct answer
A

38%
Answered correctly

02 secs
Time Spent

01/19/2020
Last Updated

Explanation

| Important inherited hyperlipoproteinemias | | | |
|---|---|---|---|
| Dyslipidemia | Protein defect | Elevated lipoproteins | Major manifestations |

| Important inherited hyperlipoproteinemias | | | |
|---|---|---|---|
| **Dyslipidemia** | **Protein defect** | **Elevated lipoproteins** | **Major manifestations** |
| **Familial chylomicronemia syndrome** (Type I) | • Lipoprotein lipase<br>• ApoC-II | Chylomicrons | • **Acute pancreatitis**<br>• Lipemia retinalis<br>• Eruptive skin xanthomas<br>• Hepatosplenomegaly |
| **Familial hypercholesterolemia** (Type II A) | • LDL receptor<br>• ApoB-100 | LDL | • **Premature coronary artery disease**<br>• Corneal arcus<br>• Tendon xanthomas<br>• Xanthelasmas |
| **Familial dysbetalipoproteinemia** (Type III) | • ApoE | Chylomicron and VLDL remnants | • **Premature coronary artery disease** & peripheral vascular disease<br>• Tuboeruptive & palmar xanthomas |
| **Familial** | | | • Increased pancreatitis risk |

| | | | |
|---|---|---|---|
| **Familial dysbetalipoproteinemia** (Type III) | • ApoE | Chylomicron and VLDL remnants | • **Premature coronary artery disease** & peripheral vascular disease<br>• Tuboeruptive & palmar xanthomas |
| **Familial hypertriglyceridemia** (Type IV) | • ApoA-V | VLDL | • Increased pancreatitis risk<br>• Associated with obesity & insulin resistance |

©UWorld

This patient has **familial chylomicronemia syndrome** (type 1 hyperlipoproteinemia), an autosomal recessive condition most often caused by **lipoprotein lipase (LPL) deficiency**. LPL is normally bound to heparan sulfate moieties on the vascular endothelium, allowing it to interact with chylomicrons and VLDL in the circulation and release free fatty acids into the adjacent tissues. Heparin administration releases these endothelium-bound lipases, allowing LPL activity to be measured in the laboratory. Without sufficient LPL activity, the body is unable to clear dietary lipid loads due to defective hydrolysis of serum triglycerides (especially **chylomicrons**).

Patients with familial chylomicronemia syndrome present in childhood with marked **hypertriglyceridemia**, recurrent **acute pancreatitis, lipemia retinalis** (milky-appearing retinal vasculature), and eruptive xanthomas (small yellowish papules surrounded by erythema found mainly on extensor surfaces).

**(Choice B)** The familial hyperlipoproteinemias are not associated with intellectual disability.

**(Choices C, D, and E)** Accelerated coronary artery disease, tendon xanthomas (nodular lipid deposits in the tendons, particularly the Achilles), and xanthelasmas are seen in familial hypercholesterolemia, a condition caused by defects in the LDL receptor or its ligand, ApoB-100. As LDL is mainly cleared from the circulation by receptor-mediated uptake in the liver, individuals with familial hypercholesterolemia have dramatically elevated LDL concentrations.

| | | | |
|---|---|---|---|
| (Type IV) | | | obesity & insulin resistance |

©UWorld

This patient has **familial chylomicronemia syndrome** (type 1 hyperlipoproteinemia), an autosomal recessive condition most often caused by **lipoprotein lipase (LPL) deficiency**. LPL is normally bound to heparan sulfate moieties on the vascular endothelium, allowing it to interact with chylomicrons and VLDL in the circulation and release free fatty acids into the adjacent tissues. Heparin administration releases these endothelium-bound lipases, allowing LPL activity to be measured in the laboratory. Without sufficient LPL activity, the body is unable to clear dietary lipid loads due to defective hydrolysis of serum triglycerides (especially **chylomicrons**).

Patients with familial chylomicronemia syndrome present in childhood with marked **hypertriglyceridemia**, recurrent **acute pancreatitis, lipemia retinalis** (milky-appearing retinal vasculature), and eruptive xanthomas (small yellowish papules surrounded by erythema found mainly on extensor surfaces).

**(Choice B)** The familial hyperlipoproteinemias are not associated with intellectual disability.

**(Choices C, D, and E)** Accelerated coronary artery disease, tendon xanthomas (nodular lipid deposits in the tendons, particularly the Achilles), and xanthelasmas are seen in familial hypercholesterolemia, a condition caused by defects in the LDL receptor or its ligand, ApoB-100. As LDL is mainly cleared from the circulation by receptor-mediated uptake in the liver, individuals with familial hypercholesterolemia have dramatically elevated LDL concentrations.

**Educational objective:**
Familial chylomicronemia syndrome frequently presents in childhood with recurrent episodes of acute pancreatitis. Patients with this disorder are not usually at increased risk for premature coronary artery disease. Eruptive skin xanthomas may be present in hypertriglyceridemia, but tendon xanthomas and xanthelasmas are primarily seen with hypercholesterolemia.

| Pathology | Endocrine, Diabetes & Metabolism | Dyslipidemia |
|---|---|---|
| Subject | System | Topic |

Copyright © UWorld. All rights reserved.

(Type IV)

obesity & insulin

Exhibit Display

Zoom In | Zoom Out | Reset | Add To New Card | Existing Card

1
2
3
4
5
6
7
8
9
10
11
12
13
14
15
16
17
18
19
20
21
22
23
24
25
26
27
28
29
30
31

1 2 3 4 5 6 7 8 9 10 11 12 13 14 15 16 17 18 19 20 21 22 23 24 25 26 27 28 29 30 31

A 25-year-old man comes to the office for evaluation of facial acne. He has no significant past medical history and does not use tobacco or alcohol. The patient works as a personal trainer. His family history is significant for diabetes mellitus in his mother and leukemia in his father. His blood pressure is 134/82 mm Hg and pulse is 58/min. On physical examination, there is mild facial acne. The patient's lungs are clear to auscultation. The liver span is 8 cm, and the spleen is not palpable. His testes are soft, and testicular volume is decreased. Laboratory results are as follows:

| | |
|---|---|
| Hematocrit | 60% |
| White blood cells | 7,500/mm$^3$ |
| Platelets | 225,000/mm$^3$ |
| Erythrocyte sedimentation rate | 15 mm/hr |
| Serum creatinine | 1.2 mg/dL |
| Blood urea nitrogen | 18 mg/dL |

Which of the following is the most likely explanation for this patient's abnormal laboratory findings?

A. High oxygen affinity hemoglobin
B. Intensive exercise schedule
C. Myeloproliferative disorder
D. Renal artery stenosis
E. Steroid drug abuse
F. Volume depletion due to excessive sweating

alcohol. The patient works as a personal trainer. His family history is significant for diabetes mellitus in his mother and leukemia in his father. His blood pressure is 134/82 mm Hg and pulse is 58/min. On physical examination, there is mild facial acne. The patient's lungs are clear to auscultation. The liver span is 8 cm, and the spleen is not palpable. His testes are soft, and testicular volume is decreased. Laboratory results are as follows:

| | |
|---|---|
| Hematocrit | 60% |
| White blood cells | 7,500/mm$^3$ |
| Platelets | 225,000/mm$^3$ |
| Erythrocyte sedimentation rate | 15 mm/hr |
| Serum creatinine | 1.2 mg/dL |
| Blood urea nitrogen | 18 mg/dL |

Which of the following is the most likely explanation for this patient's abnormal laboratory findings?

A. High oxygen affinity hemoglobin (1%)
B. Intensive exercise schedule (4%)
C. Myeloproliferative disorder (3%)
D. Renal artery stenosis (1%)
✓ E. Steroid drug abuse (86%)
F. Volume depletion due to excessive sweating (3%)

Omitted
Correct answer

86%
Answered correctly

06 secs
Time Spent

06/13/2020
Last Updated

1 2 3 4 5 6 7 8 9 10 11 12 13 14 15 16 17 18 19 20 21 22 23 24 25 26 27 28 29 30 31

**Effects of androgen abuse**

| | |
|---|---|
| **Cardiovascular** | • ↑ **Hematocrit**<br>• ↑ LDL, ↓ HDL cholesterol |
| **Dermatologic** | • **Acne**<br>• Hirsutism, male-pattern hair loss (♀) |
| **Genitourinary** | • Clitoromegaly, oligomenorrhea (♀)<br>• **Testicular atrophy**, ↓ spermatogenesis (♂) |
| **Psychiatric** | • Depression, hypomania (♀)<br>• Aggressiveness, mood disorders (♂) |
| **Breast** | • Atrophy (♀)<br>• **Gynecomastia** (♂) |
| **Other** | • **Deepening of voice** (♀)<br>• Premature epiphyseal closure (adolescents) |

©UWorld

This patient has acne, testicular atrophy, and erythrocytosis, findings concerning for **androgenic steroid abuse**. Abuse of androgens, androgen precursors, and agents that increase endogenous androgen production is most common in young adults who engage in competitive athletic activities or for cosmetic purposes.

Chronic androgen use may increase muscle mass but has multiple associated risks. Testosterone stimulates red blood cell production, which accounts for the higher hematocrit in normal males compared to normal females. This effect is exaggerated in exogenous androgen abuse, which **increases hematocrit** in a dose-dependent manner. Androgens decrease gonadotropin secretion, which results in **testicular atrophy** and

This patient has acne, testicular atrophy, and erythrocytosis, findings concerning for **androgenic steroid abuse**. Abuse of androgens, androgen precursors, and agents that increase endogenous androgen production is most common in young adults who engage in competitive athletic activities or for cosmetic purposes.

Chronic androgen use may increase muscle mass but has multiple associated risks. Testosterone stimulates red blood cell production, which accounts for the higher hematocrit in normal males compared to normal females. This effect is exaggerated in exogenous androgen abuse, which **increases hematocrit** in a dose-dependent manner. Androgens decrease gonadotropin secretion, which results in **testicular atrophy** and decreased sperm production. Other common findings include **virilization** in women (eg, clitoromegaly, hirsutism) and **acne**.

**(Choices A and D)** Mutations that cause a high oxygen affinity of hemoglobin reduce the ability of hemoglobin to release oxygen in tissues. Low tissue oxygen levels in the kidneys stimulate erythropoietin release. Renal artery stenosis decreases oxygen delivery to the kidney and also stimulates erythropoietin release. These conditions may produce a compensatory erythrocytosis but would not produce the other clinical signs (eg, acne, testicular atrophy) seen in this patient.

**(Choice B)** Intensive exercise could result in elevated myoglobin secondary to rhabdomyolysis, but the hematocrit level should not be changed by exercise.

**(Choice C)** Myeloproliferative disorders, such as polycythemia vera (PV), can lead to erythrocytosis. Patients with PV typically have leukocytosis and thrombocytosis as well. This patient's additional physical findings make steroid abuse more likely.

**(Choice F)** Heavy sweating may cause a transient increase in hematocrit due to loss of plasma volume but would likely cause other signs of dehydration (eg, tachycardia). This patient's creatinine at the upper limit of normal is typical for patients with increased total muscle mass; hypovolemia also will usually cause a more pronounced rise in blood urea nitrogen.

**Educational objective:**
Androgenic steroid abuse may lead to erythrocytosis, testicular atrophy, acne, and virilization in women (eg, clitoromegaly, hirsutism).

**References**

- Effects of graded doses of testosterone on erythropoiesis in healthy young and older men.

Pathology Endocrine, Diabetes & Metabolism Androgenic steroids

1
2
3
4
5
6
7
8
9
10
11
12
13
14
15
16
17
18
19
20
21
22
23
24
25
26
27
28
29
30
31

A 16-year-old boy is brought to the emergency department because of confusion, fatigue, and abdominal pain. He has also experienced excessive thirst and polyuria during the last 3 weeks. His past medical history is insignificant. Family history is unremarkable. Urine dipstick is positive for glucose and ketones. Which of the following factors most likely contributed to the development of this patient's condition?

A. Abdominal fat distribution

B. Excessive body weight

C. Genetic defects in insulin secretion

D. Islet amyloid deposition

E. Islet leukocytic infiltration

Submit

1
2
3
4
5
6
7
8
9
10
11
12
13
14
15
16
17
18
19
20
21
22
23
24
25
26
27
28
29
30
31

A 16-year-old boy is brought to the emergency department because of confusion, fatigue, and abdominal pain. He has also experienced excessive thirst and polyuria during the last 3 weeks. His past medical history is insignificant. Family history is unremarkable. Urine dipstick is positive for glucose and ketones. Which of the following factors most likely contributed to the development of this patient's condition?

- A. Abdominal fat distribution (1%)
- B. Excessive body weight (2%)
- C. Genetic defects in insulin secretion (19%)
- D. Islet amyloid deposition (5%)
- ✓ E. Islet leukocytic infiltration (71%)

Omitted
Correct answer
E

71%
Answered correctly

02 secs
Time Spent

02/10/2020
Last Updated

Explanation

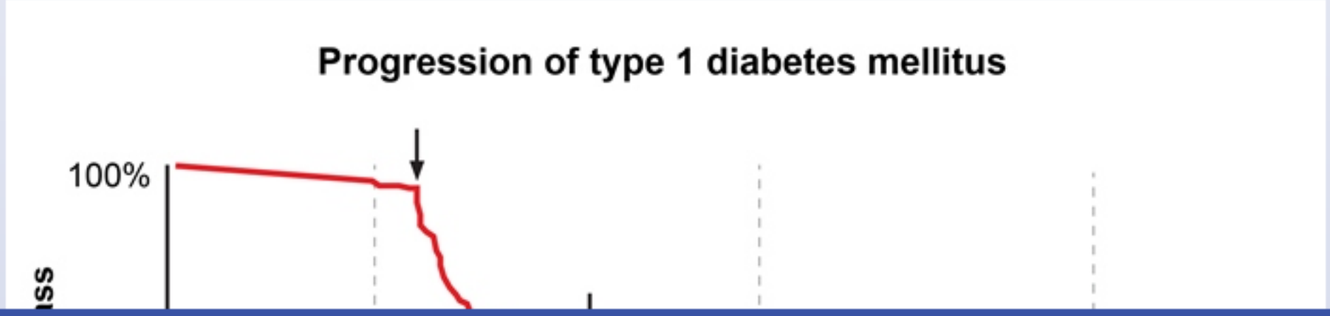

1
2
3
4
5
6
7
8
9
10
11
12
13
14
15
16
17
18
19
20
21
22
23
24
25
26
27
28
29
30
31

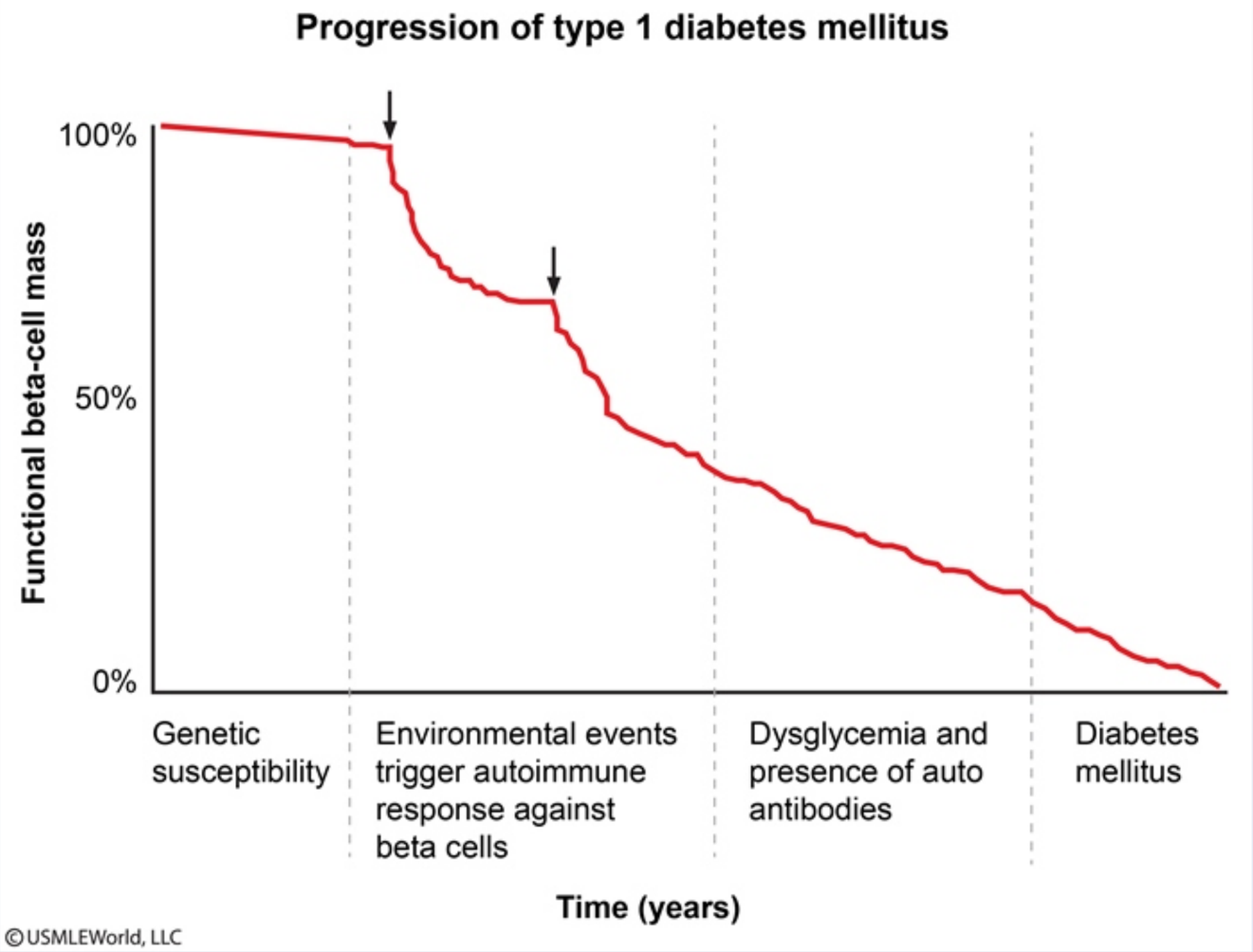


This patient is presenting with diabetic ketoacidosis, a condition that most commonly affects patients with **type 1 diabetes mellitus** due to their absolute insulin deficiency. Type 1 diabetes mellitus occurs in genetically susceptible individuals who are exposed to triggering environmental factors (eg, viral infections, environmental toxins, dietary components). This results in an **autoimmune response** against **pancreatic beta cells** that leads to progressive loss of beta cell mass. Overt manifestations of diabetes mellitus tend to develop once ≥90% of beta cells are destroyed

Time (years)

©USMLEWorld, LLC

This patient is presenting with diabetic ketoacidosis, a condition that most commonly affects patients with **type 1 diabetes mellitus** due to their absolute insulin deficiency. Type 1 diabetes mellitus occurs in genetically susceptible individuals who are exposed to triggering environmental factors (eg, viral infections, environmental toxins, dietary components). This results in an **autoimmune response** against **pancreatic beta cells** that leads to progressive loss of beta cell mass. Overt manifestations of diabetes mellitus tend to develop once >90% of beta cells are destroyed. Although antibodies against islet antigens are detected in a large number of patients, they are thought to play a permissive role in disease pathogenesis; the destruction of beta cells occurs primarily through **cell-mediated immunity**. Infiltration of islets by inflammatory cells is called **insulitis** and is more prominent during the early stages of disease.

**(Choices A and B)** Abdominal fat deposition and excessive body weight are important contributors to insulin resistance and development of type 2 diabetes mellitus. Intra-abdominal visceral fat is more strongly related to insulin resistance than is subcutaneous fat.

**(Choice C)** Maturity-onset diabetes of the young is an autosomal dominant disease caused by mutations that impair glucose sensing and insulin secretion by pancreatic beta cells. It presents as non-insulin-dependent diabetes at a young age (<25) and accounts for <5% of all cases of diabetes mellitus.

**(Choice D)** Islet amyloid polypeptide is secreted along with insulin from pancreatic beta cells. Amyloid deposition occurs in the islets of patients with type 2 diabetes mellitus, although its role as a causative agent of beta cell dysfunction remains unknown. Patients with type 1 diabetes mellitus have low circulating levels of islet amyloid polypeptide due to extensive beta cell destruction.

**Educational objective:**
Autoimmune insulitis with progressive beta cell loss is the most common cause of type 1 diabetes mellitus. Insulin resistance accompanied by relative insulin deficiency is the main cause of type 2 diabetes mellitus.

**References**

- Advances in the cellular immunological pathogenesis of type 1 diabetes.

| Pathology | Endocrine, Diabetes & Metabolism | Diabetes mellitus |
|---|---|---|
| Subject | System | Topic |

Copyright © UWorld. All rights reserved.

A 24-year-old woman, gravida 1 para 1, comes to the office for postpartum follow-up 2 weeks after a term vaginal delivery. Her baby is doing well, but she is concerned because she has not yet lactated. The patient knew she would lose weight and be tired after the baby was born, but she feels excessive fatigue and has had significant weight loss. She also has nausea, loss of appetite, and postural dizziness. The patient has no headaches, visual problems, cold intolerance, constipation, or polyuria. On examination, she appears fatigued and has mild pallor. Laboratory tests are drawn the next morning at 8:00 AM, with the following results:

| | |
|---|---|
| Hemoglobin | 9.6 g/dL |
| Sodium | 130 mEq/L |
| Cortisol, serum | 4 μg/dL |
| Free $T_4$ | 1.0 ng/dL |
| TSH | 0.2 μU/mL |

Which of the following pathologic processes is most likely responsible for this patient's symptoms?

- A. Glandular hemorrhage
- B. Inflammation
- C. Ischemic necrosis
- D. Malignant infiltration
- E. Non-malignant infiltration

Submit

A 24-year-old woman, gravida 1 para 1, comes to the office for postpartum follow-up 2 weeks after a term vaginal delivery. Her baby is doing well, but she is concerned because she has not yet lactated. The patient knew she would lose weight and be tired after the baby was born, but she feels excessive fatigue and has had significant weight loss. She also has nausea, loss of appetite, and postural dizziness. The patient has no headaches, visual problems, cold intolerance, constipation, or polyuria. On examination, she appears fatigued and has mild pallor. Laboratory tests are drawn the next morning at 8:00 AM, with the following results:

| | |
|---|---|
| Hemoglobin | 9.6 g/dL |
| Sodium | 130 mEq/L |
| Cortisol, serum | 4 μg/dL |
| Free $T_4$ | 1.0 ng/dL |
| TSH | 0.2 μU/mL |

Which of the following pathologic processes is most likely responsible for this patient's symptoms?

- A. Glandular hemorrhage (21%)
- B. Inflammation (1%)
- ✓ C. Ischemic necrosis (72%)
- D. Malignant infiltration (1%)
- E. Non-malignant infiltration (2%)

Omitted
Correct answer
C

72%
Answered correctly

03 secs
Time Spent

01/12/2020
Last Updated

1
2
3
4
5
6
7
8
9
10
11
12
13
14
15
16
17
18
19
20
21
22
23
24
25
26
27
28
29
30
31

| Hypopituitarism | |
|---|---|
| **Etiology** | **Pituitary causes**<br>• Mass lesions (primary or metastatic)<br>• Infiltration (eg, lymphocytic hypophysitis)<br>• Hemorrhage (pituitary apoplexy)<br>• Ischemic infarction (Sheehan syndrome)<br>**Hypothalamic lesions**<br>(eg, sarcoidosis, infection, radiation therapy) |
| **Clinical presentation** | **ACTH deficiency**<br>• Hypotension, weight loss, hypoglycemia<br>**Hypothyroidism**<br>• Fatigue, cold intolerance, slowed deep-tendon reflexes<br>**Gonadotropins**<br>• Women: Amenorrhea, infertility<br>• Men: Infertility, loss of libido |

©UWorld

This patient has signs of **panhypopituitarism** with failure of lactation, central hypothyroidism, and adrenal insufficiency. In the setting of a recent delivery, this most likely represents **ischemic necrosis** of the **pituitary gland** (Sheehan syndrome). During pregnancy, the pituitary enlarges due to estrogen-induced hyperplasia of the lactotrophs. However, the blood supply to the pituitary does not increase proportionally. As a result, the enlarged pituitary is vulnerable to ischemia in case of systemic hypotension due to **peripartum hemorrhage** (which this patient likely experienced given her low hemoglobin).

The most common manifestation of Sheehan syndrome is failure of lactation due to prolactin deficiency. It also commonly causes hypocortisolism

1
2
3
4
5
6
7
8
9
10
11
12
13
14
15
16
17
18
19
20
21
22
23
24
25
26
27
28
29
30
31

• Men: infertility, loss of libido

©UWorld

This patient has signs of **panhypopituitarism** with failure of lactation, central hypothyroidism, and adrenal insufficiency. In the setting of a recent delivery, this most likely represents **ischemic necrosis** of the **pituitary gland** (Sheehan syndrome). During pregnancy, the pituitary enlarges due to estrogen-induced hyperplasia of the lactotrophs. However, the blood supply to the pituitary does not increase proportionally. As a result, the enlarged pituitary is vulnerable to ischemia in case of systemic hypotension due to **peripartum hemorrhage** (which this patient likely experienced given her low hemoglobin).

The most common manifestation of Sheehan syndrome is failure of lactation due to prolactin deficiency. It also commonly causes hypocortisolism and hypothyroidism. Manifestations of thyroid deficiency may take a few weeks to develop due to the long circulating half-life of thyroxine (5-7 days) and peripheral conversion of thyroxine (T4) to T3. Cortisol deficiency manifests rapidly, however, with nausea, postural hypotension, fatigue, and weight loss.

**(Choice A)** Pituitary apoplexy is due to sudden hemorrhage into the pituitary, usually in the setting of a preexisting pituitary adenoma. It usually presents with acute severe headache, ophthalmoplegia, and altered sensorium.

**(Choice B)** Lymphocytic hypophysitis is the most common inflammatory condition of the pituitary and typically occurs during late pregnancy or the early postpartum period. In contrast to Sheehan syndrome, the presentation is acute with severe headaches and visual field defects.

**(Choice D)** Primary pituitary cancer is extremely rare, although the pituitary is prone to metastases due to its rich vascular supply. These patients typically present with tumor mass effects (eg, headache, bitemporal hemianopsia).

**(Choice E)** Non-malignant infiltrative lesions such as sarcoidosis and histiocytosis X mainly involve the suprasellar region, where they compress the hypothalamus and pituitary stalk. This disrupts the normal hypothalamic dopaminergic suppression of prolactin secretion, leading to increased prolactin levels and possible galactorrhea. Central diabetes insipidus may also be seen with resulting hypernatremia.

**Educational objective:**
High estrogen levels during pregnancy cause enlargement of the pituitary gland without a proportional increase in blood supply. Peripartum hypotension can cause ischemic necrosis of the pituitary leading to panhypopituitarism (Sheehan syndrome). Patients commonly develop failure of lactation due to deficiency of prolactin.

**References**

1
2
3
4
5
6
7
8
9
10
11
12
13
14
15
16
17
18
19
20
21
22
23
24
25
26
27
28
29
30
31

The most common manifestation of Sheehan syndrome is failure of lactation due to prolactin deficiency. It also commonly causes hypocortisolism and hypothyroidism. Manifestations of thyroid deficiency may take a few weeks to develop due to the long circulating half-life of thyroxine (5-7 days) and peripheral conversion of thyroxine (T4) to T3. Cortisol deficiency manifests rapidly, however, with nausea, postural hypotension, fatigue, and weight loss.

**(Choice A)** Pituitary apoplexy is due to sudden hemorrhage into the pituitary, usually in the setting of a preexisting pituitary adenoma. It usually presents with acute severe headache, ophthalmoplegia, and altered sensorium.

**(Choice B)** Lymphocytic hypophysitis is the most common inflammatory condition of the pituitary and typically occurs during late pregnancy or the early postpartum period. In contrast to Sheehan syndrome, the presentation is acute with severe headaches and visual field defects.

**(Choice D)** Primary pituitary cancer is extremely rare, although the pituitary is prone to metastases due to its rich vascular supply. These patients typically present with tumor mass effects (eg, headache, bitemporal hemianopsia).

**(Choice E)** Non-malignant infiltrative lesions such as sarcoidosis and histiocytosis X mainly involve the suprasellar region, where they compress the hypothalamus and pituitary stalk. This disrupts the normal hypothalamic dopaminergic suppression of prolactin secretion, leading to increased prolactin levels and possible galactorrhea. Central diabetes insipidus may also be seen with resulting hypernatremia.

**Educational objective:**
High estrogen levels during pregnancy cause enlargement of the pituitary gland without a proportional increase in blood supply. Peripartum hypotension can cause ischemic necrosis of the pituitary leading to panhypopituitarism (Sheehan syndrome). Patients commonly develop failure of lactation due to deficiency of prolactin.

**References**

- Sheehan's syndrome.

| Pathology | Endocrine, Diabetes & Metabolism | Hypopituitarism |
|---|---|---|
| Subject | System | Topic |

Copyright © UWorld. All rights reserved.

1
2
3
4
5
6
7
8
9
10
11
12
13
14
15
16
17
18
19
20
21
22
23
24
25
26
27
28
29
30
31

A 58-year-old man is evaluated for a thyroid nodule. The patient first noticed a painless neck lump 2 months ago, which has progressively enlarged. He has had no heat or cold intolerance, recent weight changes, or difficulty breathing or swallowing. Medical history is notable for well-controlled hypertension. The patient has no history of radiation exposure or family history of thyroid diseases. Physical examination shows a firm, nontender nodule in the right thyroid lobe. Serum TSH level is normal, and ultrasonography shows a 4-cm solid nodule in the right thyroid lobe. Fine-needle aspiration biopsy shows a large number of follicular cells dispersed in clusters and microfollicles. The patient undergoes right thyroid lobectomy. Which of the following histologic findings would confirm a diagnosis of follicular thyroid carcinoma in this patient?

A. C-cell hyperplasia
B. Cells with empty appearing nuclei
C. Hürthle cells
D. Lymphocytic germinal centers
E. Multinucleated giant cells
F. Tumor capsular invasion

Submit

A 58-year-old man is evaluated for a thyroid nodule. The patient first noticed a painless neck lump 2 months ago, which has progressively enlarged. He has had no heat or cold intolerance, recent weight changes, or difficulty breathing or swallowing. Medical history is notable for well-controlled hypertension. The patient has no history of radiation exposure or family history of thyroid diseases. Physical examination shows a firm, nontender nodule in the right thyroid lobe. Serum TSH level is normal, and ultrasonography shows a 4-cm solid nodule in the right thyroid lobe. Fine-needle aspiration biopsy shows a large number of follicular cells dispersed in clusters and microfollicles. The patient undergoes right thyroid lobectomy. Which of the following histologic findings would confirm a diagnosis of follicular thyroid carcinoma in this patient?

A. C-cell hyperplasia (5%)
B. Cells with empty appearing nuclei (10%)
C. Hürthle cells (9%)
D. Lymphocytic germinal centers (8%)
E. Multinucleated giant cells (3%)
✓ F. Tumor capsular invasion (63%)

Omitted
Correct answer
F

63%
Answered correctly

02 secs
Time Spent

02/23/2020
Last Updated

Explanation

1
2
3
4
5
6
7
8
9
10
11
12
13
14
15
16
17
18
19
20
21
22
23
24
25
26
27
28
29
30
31

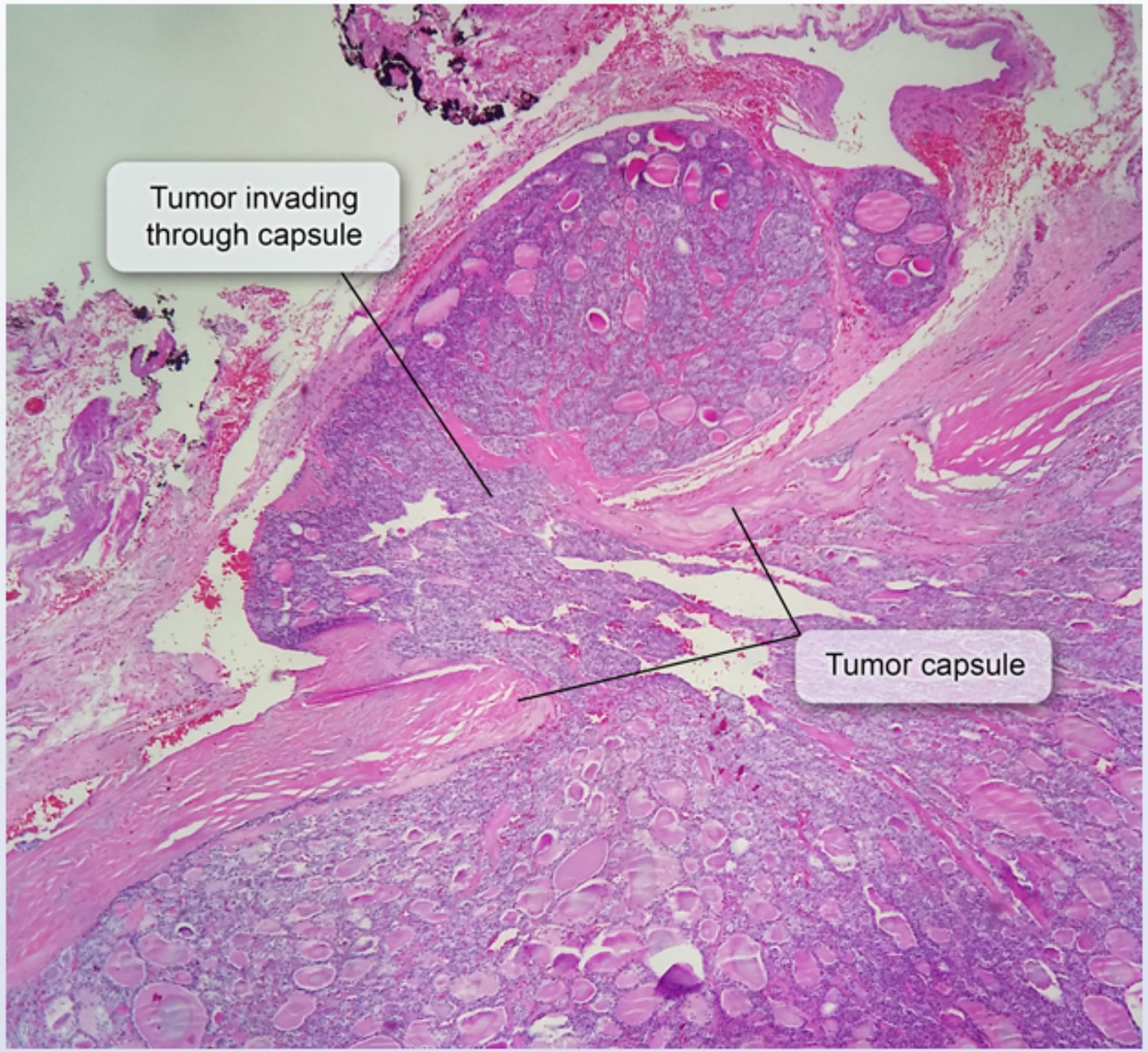


This euthyroid patient has a slowly enlarging, firm, painless thyroid nodule and fine-needle aspiration (FNA) results indicative of a **follicular neoplasm** (eg, numerous follicular cells and microfollicles). Most follicular thyroid neoplasms are benign follicular adenomas, but 15%-30% can

This euthyroid patient has a slowly enlarging, firm, painless thyroid nodule and fine-needle aspiration (FNA) results indicative of a **follicular neoplasm** (eg, numerous follicular cells and microfollicles). Most follicular thyroid neoplasms are benign follicular adenomas, but 15%-30% can be malignant follicular carcinomas. Both types of follicular neoplasms have a similar appearance on ultrasound and FNA.

Differentiating between benign and malignant follicular lesions can only be accomplished by histologic examination of the entire tumor (eg, thyroidectomy).

- Follicular adenomas (the most common benign thyroid neoplasm) display numerous neoplastic follicular cells and microfollicles on histology but are completely encapsulated.
- In contrast, **follicular thyroid carcinomas (FTCs)** are characterized by **invasion of the tumor capsule** and/or surrounding blood vessels.

This propensity of FTCs to invade surrounding blood vessels accounts for their tendency to metastasize via **hematogenous spread** to distant tissues (eg, bone, lung).

**(Choice A)** Medullary thyroid carcinomas (MTCs) can develop sporadically or in patients with an inherited *RET* proto-oncogene mutation (eg, multiple endocrine neoplasia 2a or 2b). In patients with this germline mutation, C-cell hyperplasia is often found as a precursor to a malignant lesion. Like normal C cells, malignant C cells secrete calcitonin, which can be used both for initial detection and monitoring postoperatively.

**(Choice B)** Papillary thyroid carcinoma (the most common type of thyroid malignancy) has distinct cytologic and histologic features. These include laminar calcifications (psammoma bodies), large cells with ground-glass cytoplasm, and cells with pale, empty-appearing nuclei (Orphan Annie–eye nuclei) with nuclear inclusion bodies and nuclear grooves. Unlike FTC, papillary thyroid carcinoma can be diagnosed on FNA results.

**(Choice C)** Hürthle cells are large, polygonal cells with granular, eosinophilic cytoplasm due to large quantities of mitochondria. They are seen in a wide variety of neoplastic and nonneoplastic thyroid lesions (eg, FTCs and follicular adenomas). Therefore, they would not be of benefit in differentiating between benign and malignant follicular lesions.

**(Choice D)** Chronic autoimmune (Hashimoto) thyroiditis typically presents with signs of primary hypothyroidism (eg, weight gain, cold intolerance, elevated TSH) due to autoimmune destruction of the thyroid gland. Histology shows inflammation and lymphocytic germinal centers in the thyroid gland.

**(Choice E)** Multinucleated giant cells are seen in many thyroid conditions, including thyroiditis, cystic degeneration, and papillary thyroid carcinoma. They are not typically seen in follicular lesions.

This euthyroid patient has a slowly enlarging, firm, painless thyroid nodule and fine-needle aspiration (FNA) results indicative of a **follicular**

Exhibit Display

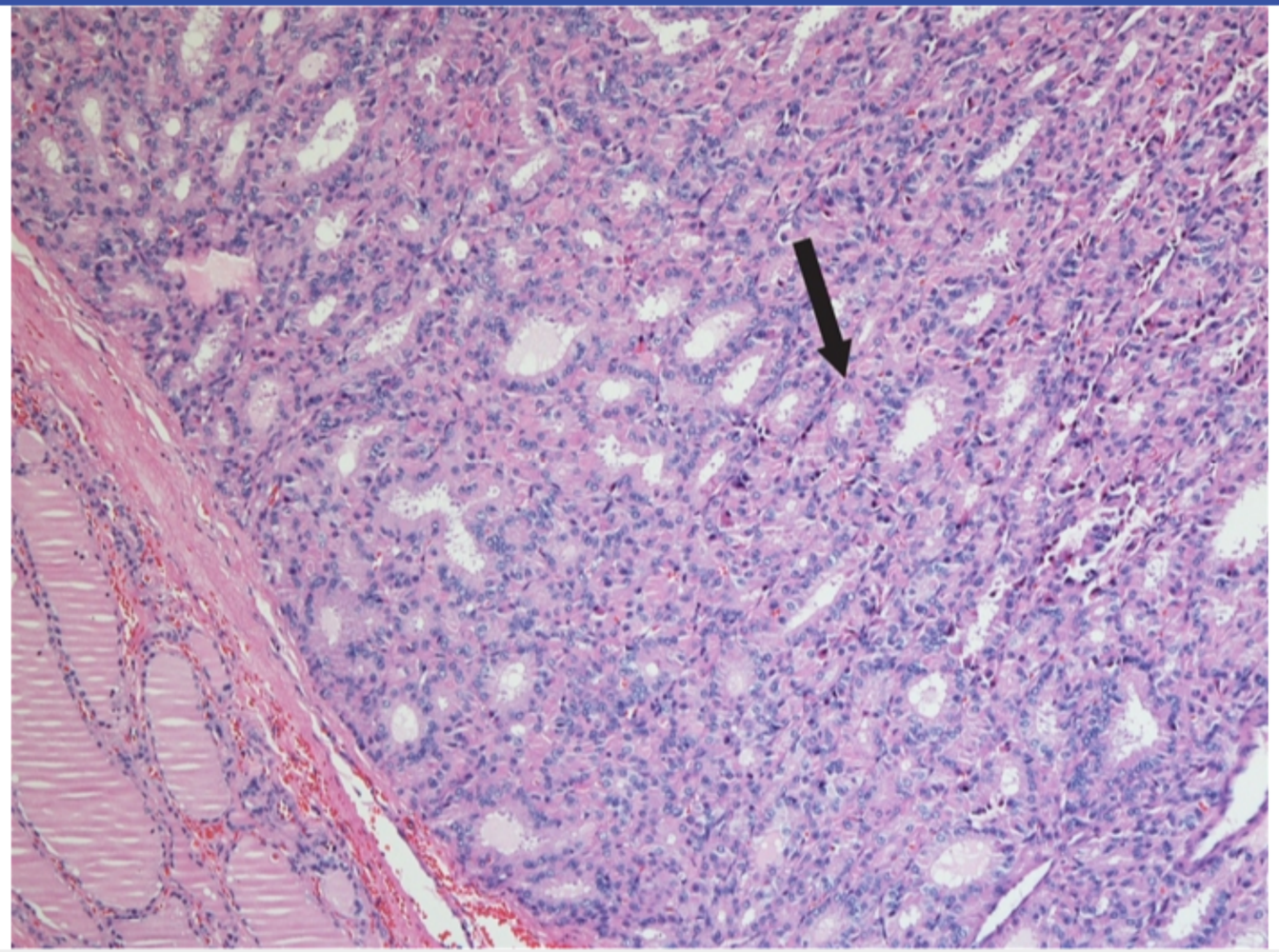

Zoom In | Zoom Out | Reset | Add To New Card | Existing Card

1
2
3
4
5
6
7
8
9
10
11
12
13
14
15
16
17
18
19
20
21
22
23
24
25
26
27
28
29
30
31

This euthyroid patient has a slowly enlarging, firm, painless thyroid nodule and fine-needle aspiration (FNA) results indicative of a **follicular**

Exhibit Display

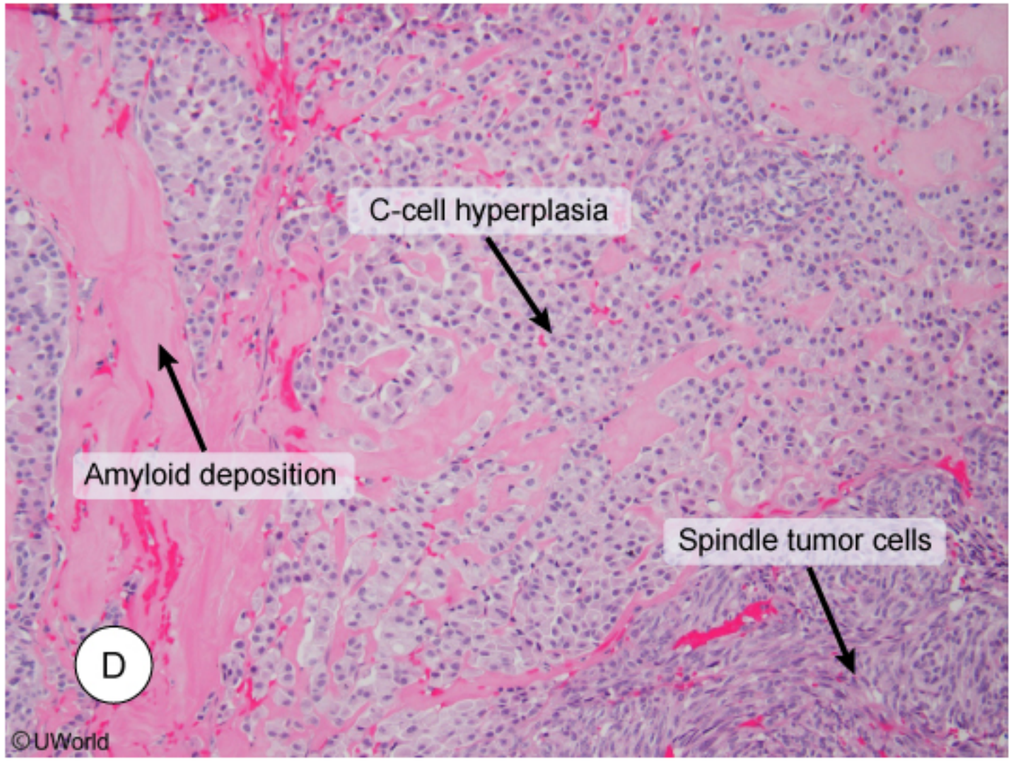


Zoom In | Zoom Out | Reset | Add To New Card | Existing Card

This euthyroid patient has a slowly enlarging, firm, painless thyroid nodule and fine-needle aspiration (FNA) results indicative of a **follicular**

Exhibit Display

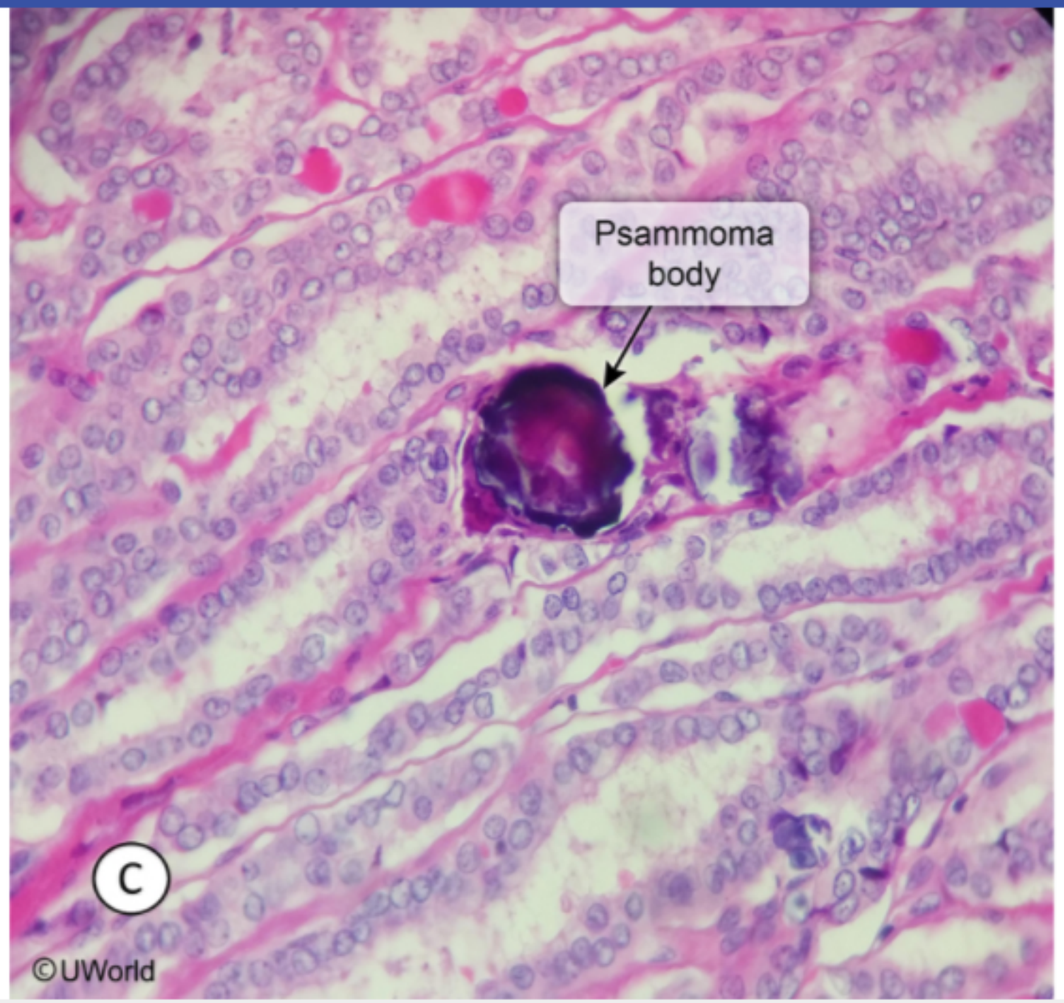


Zoom In | Zoom Out | Reset | Add To New Card | Existing Card

This euthyroid patient has a slowly enlarging, firm, painless thyroid nodule and fine-needle aspiration (FNA) results indicative of a **follicular**

Exhibit Display

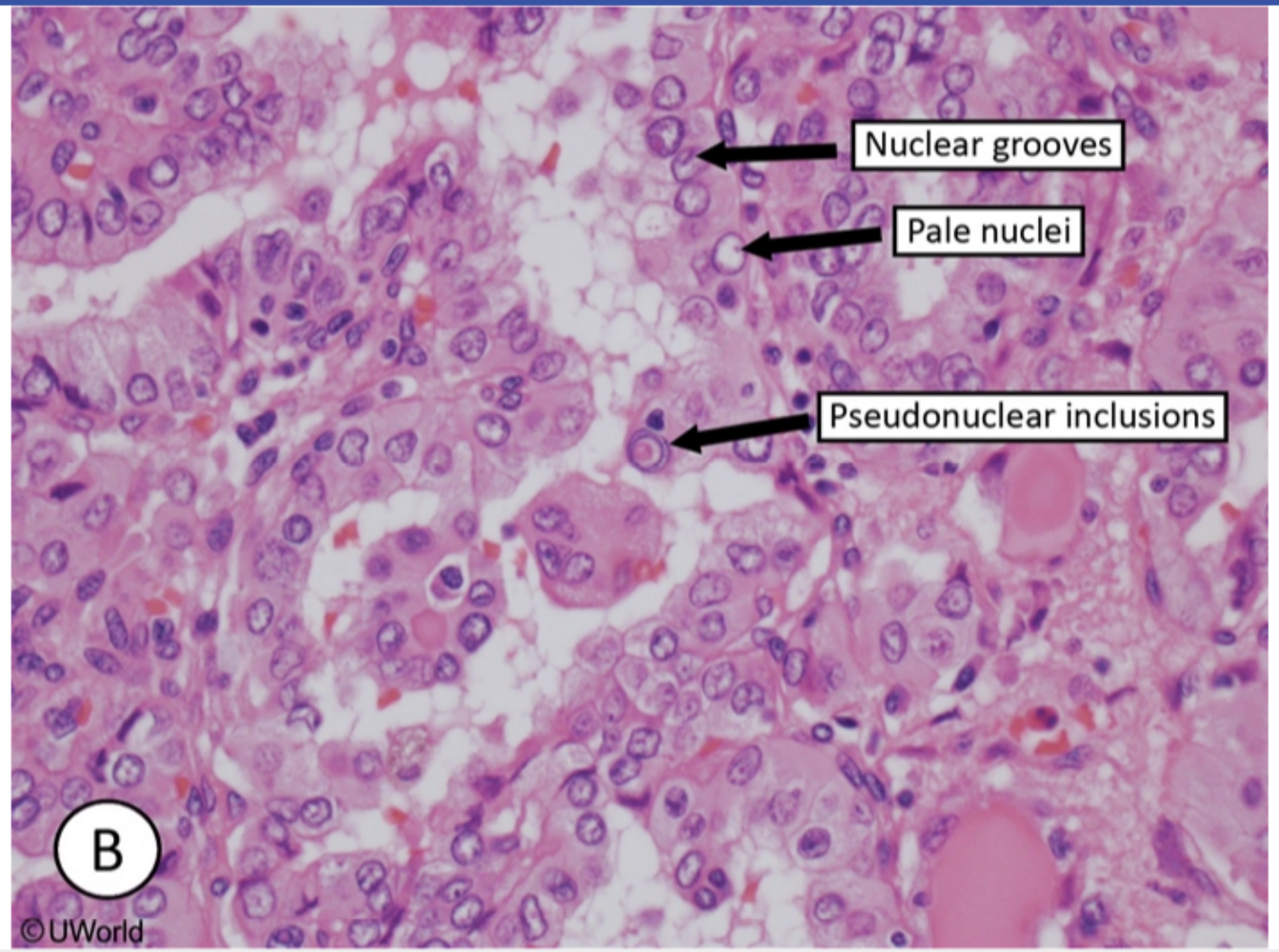


Zoom In | Zoom Out | Reset | Add To New Card | Existing Card

carcinoma. They are not typically seen in follicular lesions.

1
2
3
4
5
6
7
8
9
10
11
12
13
14
15
16
17
18
19
20
21
22
23
24
25
26
27
28
29
30
31

Exhibit Display

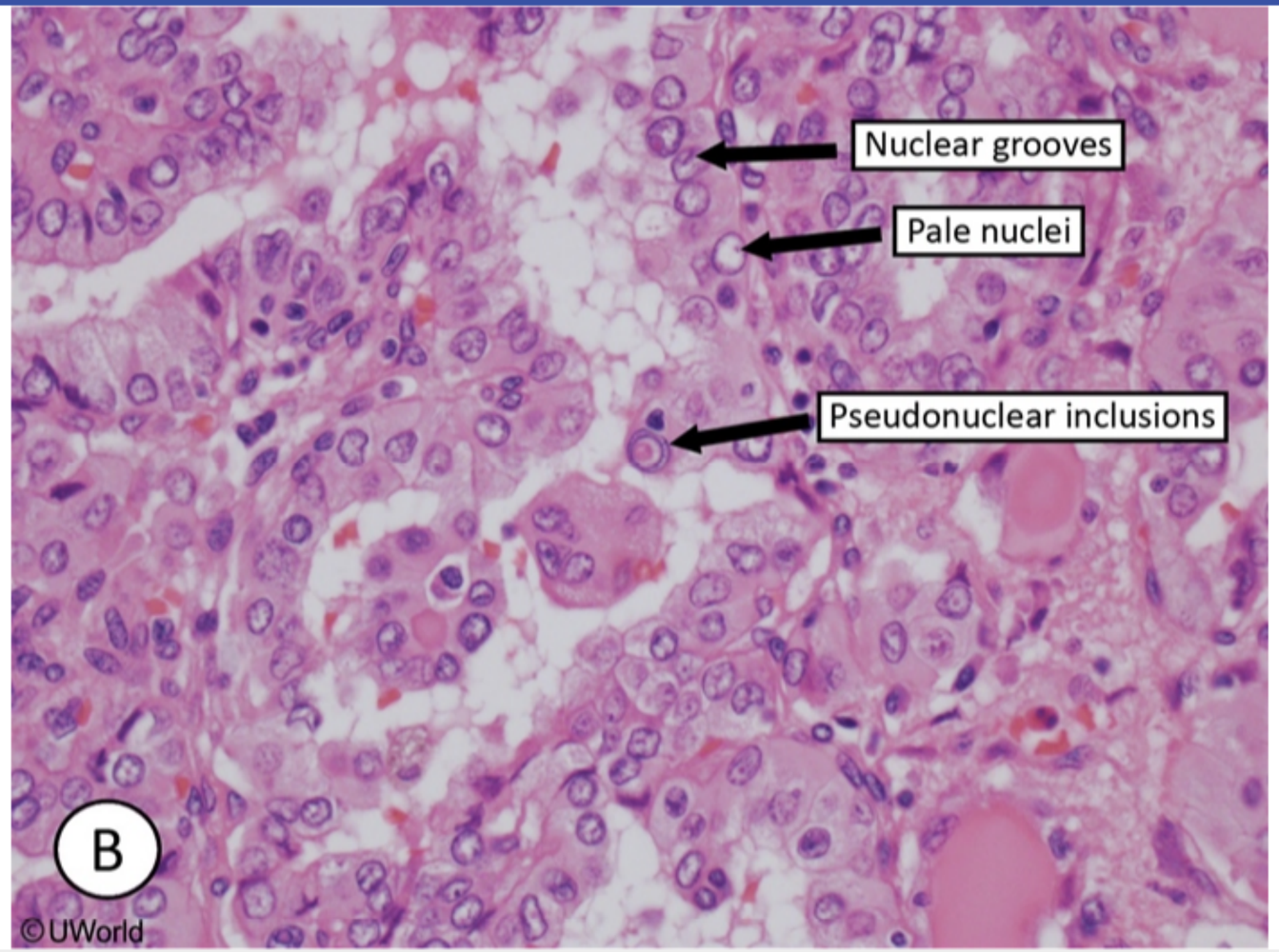


Zoom In | Zoom Out | Reset | Add To New Card | Existing Card

References

1
2
3
4
5
6
7
8
9
10
11
12
13
14
15
16
17
18
19
20
21
22
23
24
25
26
27
28
29
30
31

Exhibit Display

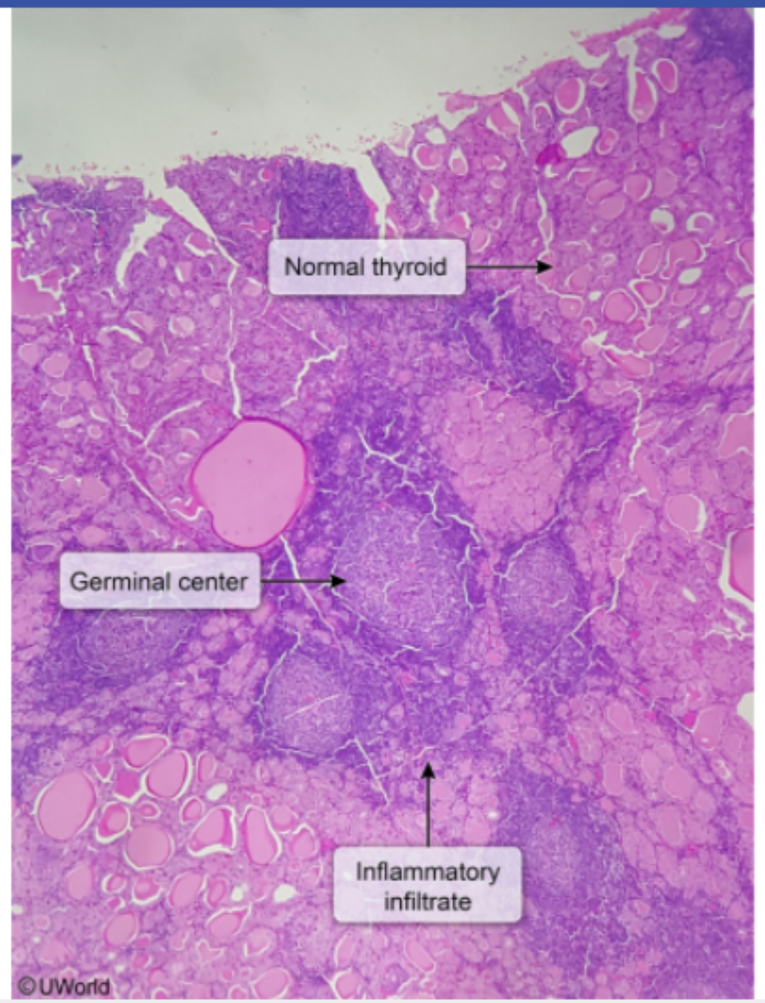


Zoom In | Zoom Out | Reset | Add To New Card | Existing Card

References

1
2
3
4
5
6
7
8
9
10
11
12
13
14
15
16
17
18
19
20
21
22
23
24
25
26
27
28
29
30
31

A 50-year-old man is brought to the emergency department due to a severe, sudden-onset headache that started an hour ago. The patient reports that he has had mild headaches and decreased libido over the past 3 months. He has no other medical conditions and takes no medications. Physical examination reveals bilateral deficits involving the temporal visual fields and impaired extraocular eye movements. Shortly after being admitted to the hospital, he becomes acutely hypotensive and loses consciousness. The patient dies despite aggressive resuscitation efforts. Which of the following is most likely to be found on autopsy?

A. Acute hemorrhage in the pituitary gland
B. Bleeding within the putamen
C. Dissection of the internal carotid artery
D. Inflamed temporal arteries
E. Ischemic necrosis of the pituitary gland
F. Ruptured intracranial aneurysm
G. Thrombus in the venous sinuses

Submit

A 50-year-old man is brought to the emergency department due to a severe, sudden-onset headache that started an hour ago. The patient reports that he has had mild headaches and decreased libido over the past 3 months. He has no other medical conditions and takes no medications. Physical examination reveals bilateral deficits involving the temporal visual fields and impaired extraocular eye movements. Shortly after being admitted to the hospital, he becomes acutely hypotensive and loses consciousness. The patient dies despite aggressive resuscitation efforts. Which of the following is most likely to be found on autopsy?

- ✓ A. Acute hemorrhage in the pituitary gland (61%)
- B. Bleeding within the putamen (1%)
- C. Dissection of the internal carotid artery (1%)
- D. Inflamed temporal arteries (1%)
- E. Ischemic necrosis of the pituitary gland (12%)
- F. Ruptured intracranial aneurysm (19%)
- G. Thrombus in the venous sinuses (2%)

Omitted
Correct answer
A

61%
Answered correctly

03 secs
Time Spent

02/09/2020
Last Updated

Explanation

| Pituitary apoplexy | |
|---|---|
| | |

1
2
3
4
5
6
7
8
9
10
11
12
13
14
15
16
17
18
19
20
21
22
23
24
25
26
27
28
29
30
31

| Pituitary apoplexy | |
|---|---|
| **Pathogenesis** | • Acute pituitary hemorrhage<br>• Usually occurs in preexisting adenoma |
| **Clinical presentation** | • Severe headache<br>• Bitemporal hemianopsia (optic chiasm) & ophthalmoplegia (CN III)<br>• Hemodynamic instability & altered sensorium |
| **Complications** | • Panhypopituitarism (acute & chronic)<br>• Severe hypotension (central adrenal failure)<br>• Coma & death |

This patient had typical features of acute pituitary hemorrhage (**pituitary apoplexy**), including a severe **headache**, **bitemporal hemianopsia** (due to compression of the optic chiasm), and **ophthalmoplegia** (due to compression of the oculomotor nerve [CN III]). Pituitary apoplexy usually occurs in a preexisting **pituitary adenoma**, as in this patient with chronic headaches and low libido (likely due to hyperprolactinemia). The diagnosis can be confirmed on cross-sectional imaging (CT or MRI scan).

Patients with pituitary apoplexy can develop cardiovascular collapse due to ACTH deficiency and subsequent **adrenocortical insufficiency**. Pituitary apoplexy is a medical emergency that requires urgent neurosurgical consultation and treatment with **glucocorticoids** .

**(Choice B)** Hemorrhage into the putamen (basal ganglia) causes neurologic deficits that gradually worsen over minutes to hours. Typical features include contralateral hemiparesis and hemianesthesia due to disruption of the corticospinal and somatosensory tracts. It is most often seen in chronic hypertensive vasculopathy.

**(Choice C)** Carotid dissection typically presents with unilateral headache, transient vision loss, ptosis, and miosis (partial Horner syndrome). It usually occurs following trauma, or can occur spontaneously in patients with chronic hypertension, connective tissue disease, or history of smoking.

1
2
3
4
5
6
7
8
9
10
11
12
13
14
15
16
17
18
19
20
21
22
23
24
25
26
27
28
29
30
31

seen in chronic hypertensive vasculopathy.

**(Choice C)** Carotid dissection typically presents with unilateral headache, transient vision loss, ptosis, and miosis (partial Horner syndrome). It usually occurs following trauma, or can occur spontaneously in patients with chronic hypertension, connective tissue disease, or history of smoking.

**(Choice D)** Typical symptoms of giant cell (temporal) arteritis include headaches, jaw claudication, and visual disturbances (eg, amaurosis fugax, anterior ischemic optic neuropathy). Patients frequently also have systemic symptoms (eg, fever, fatigue) and proximal muscle pain (polymyalgia rheumatica).

**(Choice E)** Ischemic necrosis of the pituitary (Sheehan syndrome) most commonly occurs due to hypoperfusion of the enlarged pituitary during childbirth. It presents with chronic hypopituitarism (eg, failure to lactate). Severe headaches and visual field defects do not occur.

**(Choice F)** Rupture of a saccular aneurysm near the optic chiasm can present similarly to pituitary apoplexy. However, this patient's chronic history of decreased libido and acute cardiovascular collapse is more suggestive of a pituitary etiology.

**(Choice G)** Cerebral venous sinus thrombosis is most common in patients with underlying thrombophilia, pregnancy, oral contraceptive use, malignancy, or infection. Presenting features include headaches, vomiting, seizures, and focal neurologic deficits.

**Educational objective:**
Acute pituitary hemorrhage (pituitary apoplexy) is characterized by severe headaches, bitemporal hemianopsia (compression of the optic chiasm), and ophthalmoplegia (compression of the oculomotor nerve). It usually occurs in a preexisting pituitary adenoma. Pituitary apoplexy is a medical emergency that requires urgent treatment with glucocorticoids to prevent acute adrenal crisis and circulatory collapse.

**References**

- Pituitary apoplexy: pathophysiology, diagnosis and management.

| Pathology | Endocrine, Diabetes & Metabolism | Pituitary apoplexy |
|---|---|---|
| Subject | System | Topic |

Copyright © UWorld. All rights reserved.

1
2
3
4
5
6
7
8
9
10
11
12
13
14
15
16
17
18
19
20
21
22
23
24
25
26
27
28
29
30
31

The following vignette applies to the next **2** items. The items in the set must be answered in sequential order. Once you click **Proceed to Next Item**, you will not be able to add or change an answer.

A 4-year-old boy is brought to the physician after his mother noticed that he started developing pubic hair. She also says he had a recent growth spurt and is now taller than his 5-year-old brother. In addition, his preschool teacher has noticed axillary odor after he runs or plays. On physical examination, his height corresponds to the 96th percentile and his weight corresponds to the 78th percentile for his age. There is sparse growth of long, pigmented hair at the base of the penis and in both axilla. Laboratory assessment reveals high serum concentrations of 17-hydroxyprogesterone and testosterone.

**Item 1 of 2**

Which of the following is most likely present in this patient?

A. Adrenal medullary hyperplasia
B. Adrenal cortical hyperplasia
C. Leydig cell hyperplasia
D. Pituitary adenoma
E. Seminoma

Submit

The following vignette applies to the next **2** items. The items in the set must be answered in sequential order. Once you click **Proceed to Next Item**, you will not be able to add or change an answer.

A 4-year-old boy is brought to the physician after his mother noticed that he started developing pubic hair. She also says he had a recent growth spurt and is now taller than his 5-year-old brother. In addition, his preschool teacher has noticed axillary odor after he runs or plays. On physical examination, his height corresponds to the 96th percentile and his weight corresponds to the 78th percentile for his age. There is sparse growth of long, pigmented hair at the base of the penis and in both axilla. Laboratory assessment reveals high serum concentrations of 17-hydroxyprogesterone and testosterone.

**Item 1 of 2**

Which of the following is most likely present in this patient?

A. Adrenal medullary hyperplasia (5%)
✓ B. Adrenal cortical hyperplasia (73%)
C. Leydig cell hyperplasia (11%)
D. Pituitary adenoma (8%)
E. Seminoma (1%)

Omitted
Correct answer
B

73%
Answered correctly

02 secs
Time Spent

01/23/2020
Last Updated

Explanation

1
2
3
4
5
6
7
8
9
10
11
12
13
14
15
16
17
18
19
20
21
22
23
24
25
26
27
28
29
30
31

| Clinical phenotypes of 21-hydroxylase deficiency | | | |
|---|---|---|---|
| | Classic, salt-wasting | Classic, non-salt-wasting | Non-classic, delayed |
| Degree of 21-hydroxylase deficiency | Severe | Moderate | Mild |
| Clinical presentation | Girls present at birth with ambiguous genitalia<br><br>Boys present at 1-2 weeks with failure to thrive, dehydration, hyperkalemia & hyponatremia | Girls present at birth with ambiguous genitalia<br><br>Boys present at 2-4 years with signs of early virilization | Premature pubarche or sexual precocity in school-age children<br><br>Young women can present with acne, hirsutism & menstrual irregularity |

©UWorld

21-hydroxylase deficiency is a form of congenital adrenal hyperplasia caused by an autosomal recessive inherited defect in the 21-hydroxylase gene. It can present as 3 distinct syndromes depending on the residual activity of the 21-hydroxylase enzyme. This patient is most likely suffering from the classic, non-salt-wasting form of the disease. Males with this variety typically present during the first few years of life with early virilization and accelerated linear growth due to shunting of corticosteroid precursors toward androgen production in the adrenal cortex. Females with this variety present with ambiguous genitalia at birth. As in all forms of 21-hydroxylase deficiency, patients will have increased serum concentrations of 17-hydroxyprogesterone and androgens.

**(Choice A)** Adrenal medullary hyperplasia would result in increased production and release of catecholamines. This would have no effect on virilization or linear growth and would not produce the laboratory abnormalities noted.

**(Choice C)** Leydig cell hyperplasia would result in masculinization due to excessive production of testosterone, androstenedione, and dehydroepiandrosterone. However, there would be no excess of the adrenal hormone 17-hydroxyprogesterone.

**(Choice D)** Pituitary adenomas producing excessive luteinizing hormone and follicle-stimulating hormone can result in increased testosterone

©UWorld

21-hydroxylase deficiency is a form of congenital adrenal hyperplasia caused by an autosomal recessive inherited defect in the 21-hydroxylase gene. It can present as 3 distinct syndromes depending on the residual activity of the 21-hydroxylase enzyme. This patient is most likely suffering from the classic, non-salt-wasting form of the disease. Males with this variety typically present during the first few years of life with early virilization and accelerated linear growth due to shunting of corticosteroid precursors toward androgen production in the adrenal cortex. Females with this variety present with ambiguous genitalia at birth. As in all forms of 21-hydroxylase deficiency, patients will have increased serum concentrations of 17-hydroxyprogesterone and androgens.

**(Choice A)** Adrenal medullary hyperplasia would result in increased production and release of catecholamines. This would have no effect on virilization or linear growth and would not produce the laboratory abnormalities noted.

**(Choice C)** Leydig cell hyperplasia would result in masculinization due to excessive production of testosterone, androstenedione, and dehydroepiandrosterone. However, there would be no excess of the adrenal hormone 17-hydroxyprogesterone.

**(Choice D)** Pituitary adenomas producing excessive luteinizing hormone and follicle-stimulating hormone can result in increased testosterone levels but would not increase 17-hydroxyprogesterone levels. Pituitary adenomas producing excess adrenocorticotropic hormone (ACTH) can lead to excessive adrenal androgen production. However, the symptoms of excess cortisol production (Cushing's syndrome) would dominate.

**(Choice E)** A seminoma is a testicular tumor most commonly seen in adults. These tumors are derived from the seminiferous tubules and do not present with virilization or hormonal abnormalities.

**Educational objective:**
Males with classic, non-salt-wasting 21-hydroxylase deficiency present at age 2-4 years with early virilization, increased linear growth, and elevated levels of 17-hydroxyprogesterone and androgens. Females with classic 21-hydroxylase deficiency (with or without salt-wasting) present with ambiguous genitalia at birth.

| Pathology | Endocrine, Diabetes & Metabolism | Congenital adrenal hyperplasia |
|---|---|---|
| Subject | System | Topic |

Copyright © UWorld. All rights reserved.

**Item 2 of 2**

After initial assessment, the appropriate interventions are initiated. Treatment of this patient's condition is targeted at directly suppressing which of the following hormones?

- A. Cortisol
- B. Luteinizing hormone
- C. Adrenocorticotropic hormone
- D. Testosterone
- E. Prolactin

Submit

**Item 2 of 2**

After initial assessment, the appropriate interventions are initiated. Treatment of this patient's condition is targeted at directly suppressing which of the following hormones?

- A. Cortisol (3%)
- B. Luteinizing hormone (13%)
- ✓ C. Adrenocorticotropic hormone (47%)
- D. Testosterone (35%)
- E. Prolactin (0%)

Omitted
Correct answer
C

47%
Answered correctly

03 secs
Time Spent

01/23/2020
Last Updated

Explanation

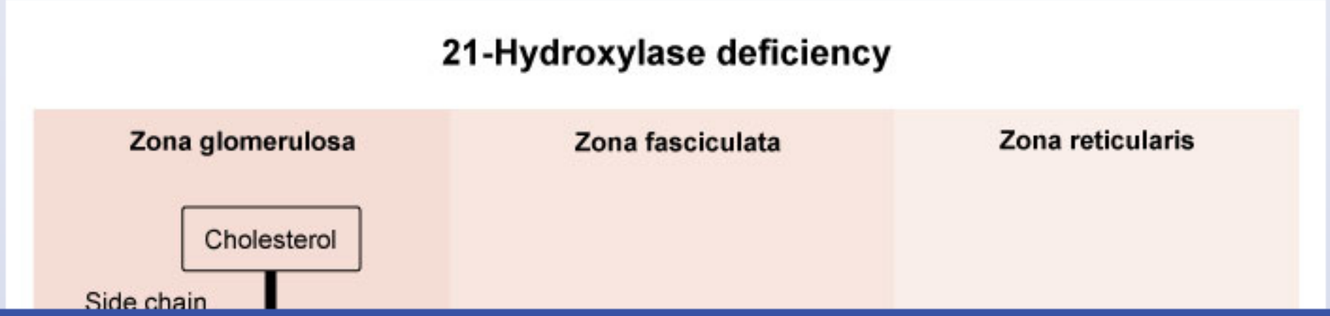

1
2
3
4
5
6
7
8
9
10
11
12
13
14
15
16
17
18
19
20
21
22
23
24
25
26
27
28
29
30
31

## 21-Hydroxylase deficiency

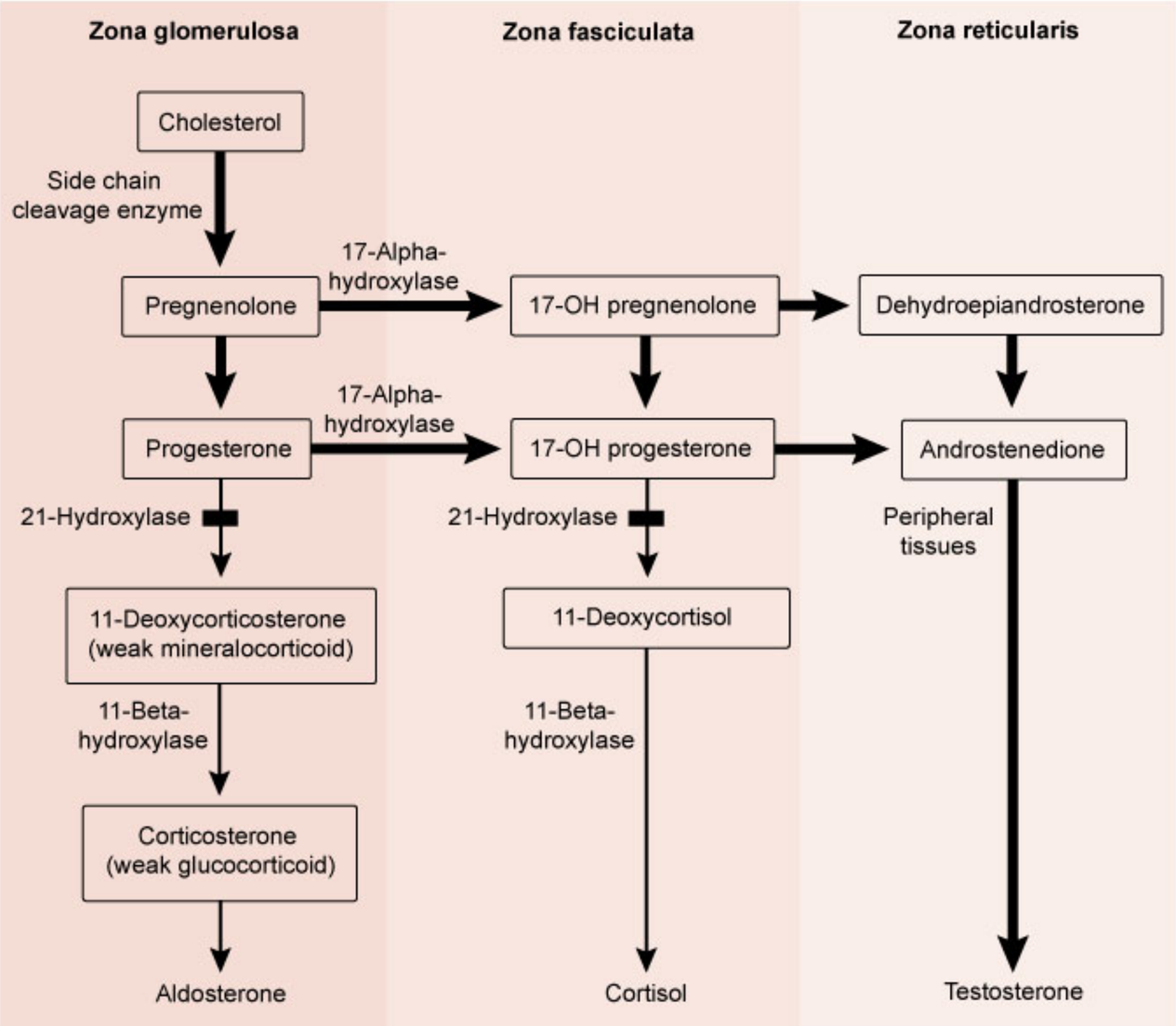

1
2
3
4
5
6
7
8
9
10
11
12
13
14
15
16
17
18
19
20
21
22
23
24
25
26
27
28
29
30
31

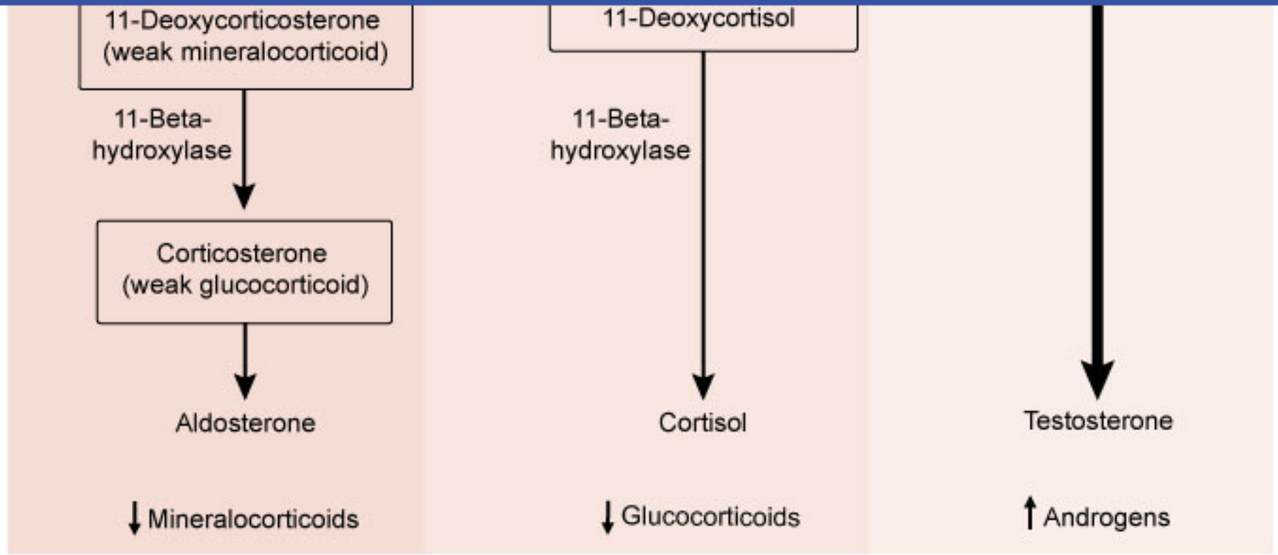


©UWorld

Patients with congenital adrenal hyperplasia due to 21-hydroxylase deficiency have defective conversion of 17-hydroxyprogesterone to 11-deoxycortisol, which impairs cortisol synthesis. Decreased cortisol levels are sensed by the hypothalamus and cause a consequential increase in adrenocorticotropic hormone (ACTH) secretion by the anterior pituitary. This results in stimulation of the adrenal cortex and androgen overproduction.

Treatment of congenital adrenal hyperplasia involves administering low (ie, physiologic) doses of exogenous corticosteroids to suppress ACTH secretion. By removing excessive ACTH stimulation, exogenous corticosteroids can decrease androgen production by the adrenal cortex.

**(Choice A)** Failure of cortisol production is the underlying problem in this patient. Further decrease in cortisol production could precipitate adrenal crisis and would be medically dangerous.

**(Choice B)** Luteinizing hormone (LH) stimulates the testis to produce testosterone. Decreasing LH levels would decrease testosterone production by the testes, but excess testicular testosterone production is not the underlying issue in this patient.

**(Choice D)** Testosterone is a gonadal androgen that is synthesized only in minimal quantities by the adrenal gland. The virilizing effects seen in this patient are the result of excessive adrenal androgen production (eg, dehydroepiandrosterone and androstenedione). These adrenal

1
2
3
4
5
6
7
8
9
10
11
12
13
14
15
16
17
18
19
20
21
22
23
24
25
26
27
28
29
30
31

| | | |
|---|---|---|
| ↓ Mineralocorticoids | ↓ Glucocorticoids | ↑ Androgens |

©UWorld

Patients with congenital adrenal hyperplasia due to 21-hydroxylase deficiency have defective conversion of 17-hydroxyprogesterone to 11-deoxycortisol, which impairs cortisol synthesis. Decreased cortisol levels are sensed by the hypothalamus and cause a consequential increase in adrenocorticotropic hormone (ACTH) secretion by the anterior pituitary. This results in stimulation of the adrenal cortex and androgen overproduction.

Treatment of congenital adrenal hyperplasia involves administering low (ie, physiologic) doses of exogenous corticosteroids to suppress ACTH secretion. By removing excessive ACTH stimulation, exogenous corticosteroids can decrease androgen production by the adrenal cortex.

**(Choice A)** Failure of cortisol production is the underlying problem in this patient. Further decrease in cortisol production could precipitate adrenal crisis and would be medically dangerous.

**(Choice B)** Luteinizing hormone (LH) stimulates the testis to produce testosterone. Decreasing LH levels would decrease testosterone production by the testes, but excess testicular testosterone production is not the underlying issue in this patient.

**(Choice D)** Testosterone is a gonadal androgen that is synthesized only in minimal quantities by the adrenal gland. The virilizing effects seen in this patient are the result of excessive adrenal androgen production (eg, dehydroepiandrosterone and androstenedione). These adrenal androgens undergo peripheral conversion to testosterone, thus explaining the high levels of testosterone found in this patient.

**(Choice E)** Prolactin excess typically results from a pituitary adenoma. In men, prolactin excess causes hypogonadism, not virilization.

**Educational objective:**
Treatment of congenital adrenal hyperplasia involves low doses of exogenous corticosteroids to suppress excessive ACTH secretion and reduce stimulation of the adrenal cortex.

| Pathology | Endocrine, Diabetes & Metabolism | Congenital adrenal hyperplasia |
|---|---|---|
| Subject | System | Topic |

Copyright © UWorld. All rights reserved.

1
2
3
4
5
6
7
8
9
10
11
12
13
14
15
16
17
18
19
20
21
22
23
24
25
26
27
28
29
30
31

A 42-year-old woman comes to the physician for a routine check-up. She has no current complaints and no significant past medical history. On physical examination, the physician notes lesions on her eyelids that are pictured below.

Which of the following is the best next step in the management of this patient?

A. ECG and serum cardiac enzymes

1
2
3
4
5
6
7
8
9
10
11
12
13
14
15
16
17
18
19
20
21
22
23
24
25
26
27
28
29
30
31

Which of the following is the best next step in the management of this patient?

A. ECG and serum cardiac enzymes

B. Serum lipids and blood glucose level

C. Liver function tests and abdominal ultrasonography

D. Complete blood count and stool guaiac test

E. Slit lamp exam and ophthalmoscopy

F. Lesion biopsy and surgeon referral

Submit

1
2
3
4
5
6
7
8
9
10
11
12
13
14
15
16
17
18
19
20
21
22
23
24
25
26
27
28
29
30
31

Which of the following is the best next step in the management of this patient?

A. ECG and serum cardiac enzymes (0%)

✓ B. Serum lipids and blood glucose level (93%)

C. Liver function tests and abdominal ultrasonography (3%)

D. Complete blood count and stool guaiac test (0%)

E. Slit lamp exam and ophthalmoscopy (0%)

F. Lesion biopsy and surgeon referral (0%)

Omitted
Correct answer

93%
Answered correctly

05 secs
Time Spent

04/01/2020
Last Updated

Explanation

The lesion pictured is a xanthelasma, a type of xanthoma usually found on the medial eyelids. Hyperlipidemia and/or dyslipidemia can result in xanthomas (including xanthelasmas). Xanthelasmas are dermal accumulations of benign-appearing macrophages with abundant, finely vacuolated (foamy) cytoplasm containing cholesterol (free and esterified), phospholipids, and triglycerides. Due in part to insulin resistance promoting increased VLDL production, diabetics may develop a secondary Type IV or V hyperlipidemia (increased VLDL, chylomicrons) and/or a secondary diabetic dyslipidemia with elevated LDL cholesterol and low HDL cholesterol. Thus, in order to determine the type of this patient's lipid disorder and to rule out underlying diabetes, her serum lipids and blood glucose should be measured.

**(Choice A)** Although this patient may be at increased risk for coronary artery disease due to hyperlipidemia or dyslipidemia, she does not currently have symptoms of myocardial infarction. Her current management should be focused on treating her lipid disorder.

**(Choice C)** The first step in managing this patient is to establish what type of lipid abnormality she has based upon her serum lipid levels and lipoprotein profile. If the results are consistent with an obstructive liver and/or biliary system lesion producing cholestasis and hypercholesterolemia, then liver function tests and abdominal ultrasonography may be warranted.

**(Choice D)** A CBC and stool guaiac test are performed when searching for occult GI bleeding.

**(Choice E)** Slit lamp examination and funduscopy could reveal ocular findings associated with this patient's lipid disorder, such as a corneal arcus (lipid deposit) or lipemia retinalis. However, a serum lipid profile should be obtained next in order to establish the type of hyperlipidemia or dyslipidemia in this patient.

**(Choice F)** Xanthelasmas are usually diagnosed based on clinical appearance. Biopsy is not required. Treatment is primarily medical and directed at the underlying lipid abnormality. Surgical excision is not medically necessary, but may be undertaken electively for cosmetic reasons.

**Educational objective:**
Xanthelasmas, a type of xanthoma, are yellowish macules/papules found on the medial eyelids. They are dermal accumulations of macrophages containing cholesterol and triglycerides, and are generally associated with a primary or secondary hyperlipidemia or dyslipidemia. An LDL receptor abnormality is the most common cause.

A 55-year-old man comes to the office for follow-up of abnormal serum chemistries found on routine laboratory testing. He has a history of hypertension, for which he is being treated with pharmacologic therapy, weight loss, and dietary salt restriction. Blood pressure is 130/80 mm Hg and pulse is 80/min. BMI is 27 kg/m$^2$. Physical examination reveals no abnormalities. Laboratory studies are as follows:

| Serum chemistry | |
|---|---|
| Sodium | 134 mEq/L |
| Potassium | 3.8 mEq/L |
| Blood urea nitrogen | 18 mg/dL |
| Creatinine | 0.8 mg/dL |
| Calcium | 11.0 mg/dL |
| Glucose | 98 mg/dL |
| Albumin | 4 g/dL |
| Parathyroid hormone | decreased |

Which of the following is most likely responsible for these findings?

A. Familial hypocalciuric hypercalcemia
B. Hypothyroidism
C. Medication effect
D. Primary hyperparathyroidism
E. Secondary hyperparathyroidism

and pulse is 80/min. BMI is 27 kg/m$^2$. Physical examination reveals no abnormalities. Laboratory studies are as follows:

| Serum chemistry | |
|---|---|
| Sodium | 134 mEq/L |
| Potassium | 3.8 mEq/L |
| Blood urea nitrogen | 18 mg/dL |
| Creatinine | 0.8 mg/dL |
| Calcium | 11.0 mg/dL |
| Glucose | 98 mg/dL |
| Albumin | 4 g/dL |
| Parathyroid hormone | decreased |

Which of the following is most likely responsible for these findings?

A. Familial hypocalciuric hypercalcemia
B. Hypothyroidism
C. Medication effect
D. Primary hyperparathyroidism
E. Secondary hyperparathyroidism

Submit

and pulse is 80/min. BMI is 27 kg/m$^2$. Physical examination reveals no abnormalities. Laboratory studies are as follows:

| Serum chemistry | |
|---|---|
| Sodium | 134 mEq/L |
| Potassium | 3.8 mEq/L |
| Blood urea nitrogen | 18 mg/dL |
| Creatinine | 0.8 mg/dL |
| Calcium | 11.0 mg/dL |
| Glucose | 98 mg/dL |
| Albumin | 4 g/dL |
| Parathyroid hormone | decreased |

Which of the following is most likely responsible for these findings?

A. Familial hypocalciuric hypercalcemia (20%)
B. Hypothyroidism (1%)
✓ C. Medication effect (63%)
D. Primary hyperparathyroidism (4%)
E. Secondary hyperparathyroidism (9%)

Omitted
Correct answer

63%
Answered correctly

04 secs
Time Spent

03/15/2020
Last Updated

1
2
3
4
5
6
7
8
9
10
11
12
13
14
15
16
17
18
19
20
21
22
23
24
25
26
27
28
29
30
31

# Effect of thiazide diuretics on distal tubular calcium reabsorption

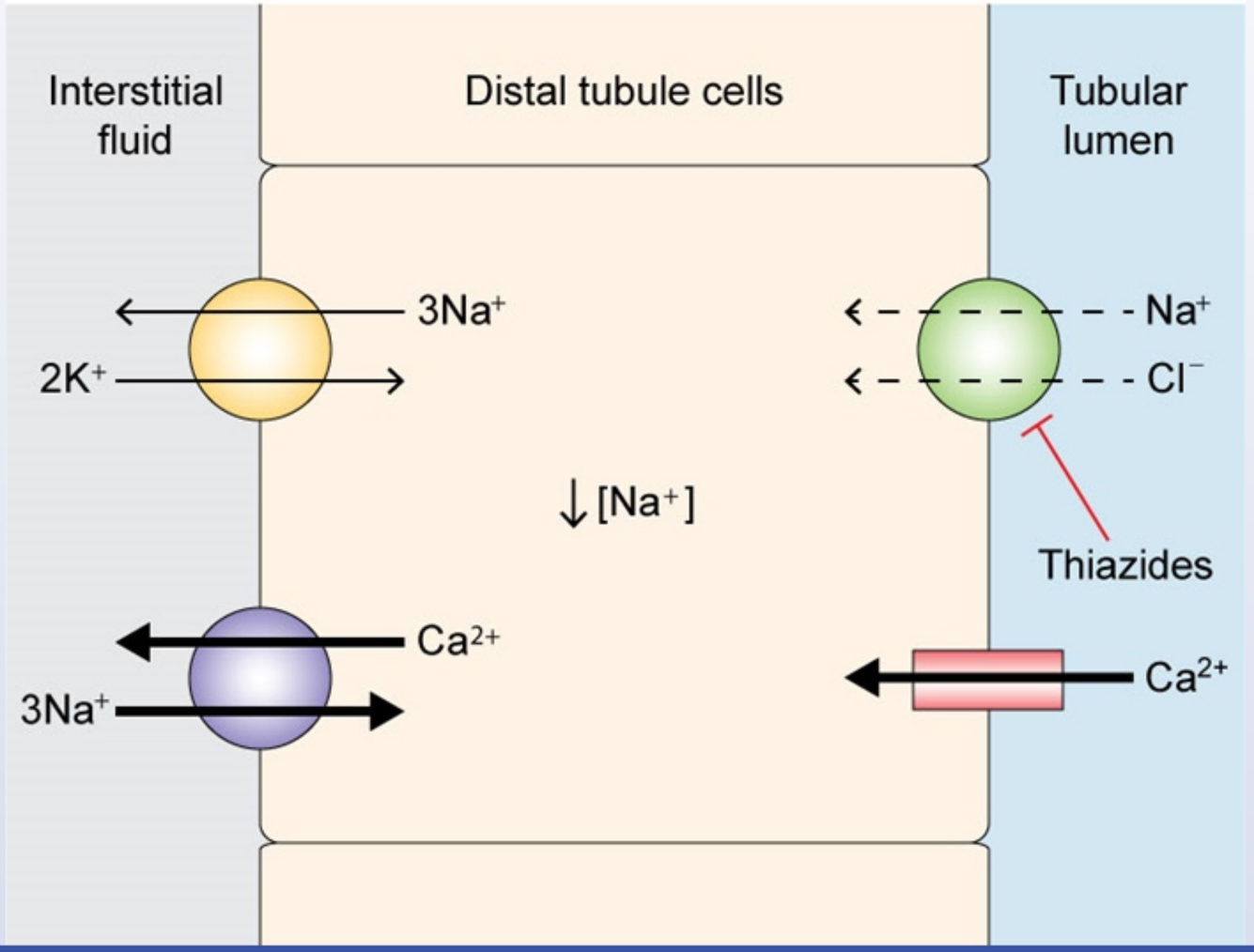

1
2
3
4
5
6
7
8
9
10
11
12
13
14
15
16
17
18
19
20
21
22
23
24
25
26
27
28
29
30
31

**Thiazide diuretics** (eg, chlorthalidone, hydrochlorothiazide) are some of the most widely used agents for treatment of hypertension. However, thiazides, especially in higher doses, can cause a variety of metabolic complications, including hypercalcemia, hyperglycemia, hyperlipidemia, hyponatremia, and hypokalemia. The incidence of the individual side effects is relatively low, and, patients rarely experience all of the potential adverse effects.

Thiazides increase renal $Ca^{2+}$ reabsorption, leading to **hypercalcemia** and **hypocalciuria**. This occurs through 2 major mechanisms:

1. Thiazides **inhibit the $Na^+/Cl^-$ cotransporter** on the apical side of distal convoluted tubule cells, which decreases intracellular $Na^+$ concentration. This activates the basolateral **$Na^+/Ca^{2+}$ antiporter**, which pumps $Na^+$ into the cell in exchange for $Ca^{2+}$. The resulting decrease in intracellular $Ca^{2+}$ enhances luminal $Ca^{2+}$ reabsorption across the apical membrane.
2. **Hypovolemia** induced by thiazides increases $Na^+$ and $H_2O$ reabsorption in the proximal tubule, leading to a passive increase in paracellular $Ca^{2+}$ reabsorption.

The increase in circulating calcium suppresses parathyroid hormone (PTH) release, leading to a new steady state with a mildly elevated serum calcium concentration and low serum PTH.

**(Choice A)** Familial hypocalciuric hypercalcemia is a benign disorder caused by mutations in the calcium-sensing receptor in the parathyroid gland and kidneys. Higher calcium levels are required to suppress secretion of PTH, leading to mild hypercalcemia and hypocalciuria. However, unlike in patients taking thiazide diuretics, PTH is high-normal or mildly elevated.

**(Choice B)** Hyperthyroidism can cause hypercalcemia due to increased osteoclastic bone resorption, but serum calcium in hypothyroidism is usually normal.

**(Choices D and E)** Primary hyperparathyroidism is caused by parathyroid hyperplasia or adenoma; it is characterized by hypercalcemia with elevated or inappropriately normal PTH levels. Secondary hyperparathyroidism is usually seen in patients with chronic kidney disease and is due to phosphate retention and decreased production of 1,25-dihydroxyvitamin D; these disturbances lead to decreased intestinal calcium absorption,

Thiazides increase renal $Ca^{2+}$ reabsorption, leading to **hypercalcemia** and **hypocalciuria**. This occurs through 2 major mechanisms:

1. Thiazides **inhibit the $Na^+/Cl^-$ cotransporter** on the apical side of distal convoluted tubule cells, which decreases intracellular $Na^+$ concentration. This activates the basolateral **$Na^+/Ca^{2+}$ antiporter**, which pumps $Na^+$ into the cell in exchange for $Ca^{2+}$. The resulting decrease in intracellular $Ca^{2+}$ enhances luminal $Ca^{2+}$ reabsorption across the apical membrane.
2. **Hypovolemia** induced by thiazides increases $Na^+$ and $H_2O$ reabsorption in the proximal tubule, leading to a passive increase in paracellular $Ca^{2+}$ reabsorption.

The increase in circulating calcium suppresses parathyroid hormone (PTH) release, leading to a new steady state with a mildly elevated serum calcium concentration and low serum PTH.

**(Choice A)** Familial hypocalciuric hypercalcemia is a benign disorder caused by mutations in the calcium-sensing receptor in the parathyroid gland and kidneys. Higher calcium levels are required to suppress secretion of PTH, leading to mild hypercalcemia and hypocalciuria. However, unlike in patients taking thiazide diuretics, PTH is high-normal or mildly elevated.

**(Choice B)** Hyperthyroidism can cause hypercalcemia due to increased osteoclastic bone resorption, but serum calcium in hypothyroidism is usually normal.

**(Choices D and E)** Primary hyperparathyroidism is caused by parathyroid hyperplasia or adenoma; it is characterized by hypercalcemia with elevated or inappropriately normal PTH levels. Secondary hyperparathyroidism is usually seen in patients with chronic kidney disease and is due to phosphate retention and decreased production of 1,25-dihydroxyvitamin D; these disturbances lead to decreased intestinal calcium absorption, hypocalcemia, hyperphosphatemia, and a compensatory increase in PTH secretion. This patient has a decreased PTH level.

**Educational objective:**
Thiazide diuretics cause hypercalcemia by increasing the distal tubular reabsorption of $Ca^{2+}$. The increased circulating calcium levels result in suppression of parathyroid hormone, which distinguishes this effect from hyperparathyroidism.

| Pathology | Endocrine, Diabetes & Metabolism | Hypercalcemia |
|---|---|---|
| Subject | System | Topic |

Copyright © UWorld. All rights reserved.

1
2
3
4
5
6
7
8
9
10
11
12
13
14
15
16
17
18
19
20
21
22
23
24
25
26
27
28
29
30
31

A 14-year-old boy is brought to the office due to painless nodules on his lips and tongue. The lesions appeared several months ago and have been progressively enlarging. The patient underwent total thyroidectomy 5 years ago following the discovery of a thyroid mass and takes thyroid hormone replacement. On physical examination, the patient is tall and slender with disproportionately long arms and legs. His fingers are also long and thin, and joint laxity is present. Eye examination is normal and oral inspection reveals several small, soft, flesh-colored papules on his lips and tongue. Serum TSH is within normal limits. This patient most likely has which of the following conditions?

A. Ehlers-Danlos syndrome
B. Marfan syndrome
C. Multiple endocrine neoplasia type 1
D. Multiple endocrine neoplasia type 2B
E. Neurofibromatosis type 1
F. Neurofibromatosis type 2

Submit

A 14-year-old boy is brought to the office due to painless nodules on his lips and tongue. The lesions appeared several months ago and have been progressively enlarging. The patient underwent total thyroidectomy 5 years ago following the discovery of a thyroid mass and takes thyroid hormone replacement. On physical examination, the patient is tall and slender with disproportionately long arms and legs. His fingers are also long and thin, and joint laxity is present. Eye examination is normal and oral inspection reveals several small, soft, flesh-colored papules on his lips and tongue. Serum TSH is within normal limits. This patient most likely has which of the following conditions?

- A. Ehlers-Danlos syndrome (4%)
- B. Marfan syndrome (6%)
- C. Multiple endocrine neoplasia type 1 (1%)
- ✓ D. Multiple endocrine neoplasia type 2B (83%)
- E. Neurofibromatosis type 1 (2%)
- F. Neurofibromatosis type 2 (1%)

Omitted
Correct answer
D

83%
Answered correctly

02 secs
Time Spent

05/18/2020
Last Updated

Explanation

| Classification of multiple endocrine neoplasia | |
|---|---|
| | • **Primary hyperparathyroidism** (parathyroid adenomas or hyperplasia) |

| Classification of multiple endocrine neoplasia | |
|---|---|
| **Type 1** | • **Primary hyperparathyroidism** (parathyroid adenomas or hyperplasia)<br>• Pituitary tumors (prolactin, visual defects)<br>• Pancreatic tumors (especially gastrinomas) |
| **Type 2A** | • **Medullary thyroid cancer** (calcitonin)<br>• Pheochromocytoma<br>• Primary hyperparathyroidism (parathyroid hyperplasia) |
| **Type 2B** | • **Medullary thyroid cancer** (calcitonin)<br>• Pheochromocytoma<br>• Mucosal neuromas/marfanoid habitus |

This patient has a **marfanoid habitus**—a tall and slender build with disproportionately long arms, legs, and fingers. The flesh-colored nodules on his lips and tongue are likely **mucosal neuromas**, which are unencapsulated, thickened proliferations of neural tissue. This patient also has a history of total thyroidectomy, which was likely due to **medullary thyroid cancer** (MTC). This combination of clinical findings is consistent with **multiple endocrine neoplasia type 2B** (MEN 2B), which is due to an autosomal dominant germ-line mutation in the *RET* proto-oncogene. Other possible manifestations of MEN 2B include pheochromocytoma and intestinal ganglioneuromas (which may cause constipation). The earliest manifestations of the disease often appear in childhood or adolescence. Early recognition of MEN 2B is important as almost all patients develop MTC and prophylactic thyroidectomy can be life-saving.

**(Choice A)** Ehlers-Danlos syndrome is a heritable connective tissue disorder characterized by skin hyperextensibility, joint hypermobility, tissue fragility, poor wound healing, and easy bruising. There is no known association between Ehlers-Danlos syndrome and thyroid cancer or perioral nodules.

**(Choice B)** Although this patient has a marfanoid habitus, the remainder of his presentation is more consistent with MEN 2B than Marfan syndrome. In addition, unlike true Marfan syndrome, patients with MEN 2B do not develop aortic malformations (eg, dilation) or ocular

| | |
|---|---|
| | • Mucosal neuromas/marfanoid habitus |

This patient has a **marfanoid habitus**—a tall and slender build with disproportionately long arms, legs, and fingers. The flesh-colored nodules on his lips and tongue are likely **mucosal neuromas**, which are unencapsulated, thickened proliferations of neural tissue. This patient also has a history of total thyroidectomy, which was likely due to **medullary thyroid cancer** (MTC). This combination of clinical findings is consistent with **multiple endocrine neoplasia type 2B** (MEN 2B), which is due to an autosomal dominant germ-line mutation in the *RET* proto-oncogene. Other possible manifestations of MEN 2B include pheochromocytoma and intestinal ganglioneuromas (which may cause constipation). The earliest manifestations of the disease often appear in childhood or adolescence. Early recognition of MEN 2B is important as almost all patients develop MTC and prophylactic thyroidectomy can be life-saving.

**(Choice A)** Ehlers-Danlos syndrome is a heritable connective tissue disorder characterized by skin hyperextensibility, joint hypermobility, tissue fragility, poor wound healing, and easy bruising. There is no known association between Ehlers-Danlos syndrome and thyroid cancer or perioral nodules.

**(Choice B)** Although this patient has a marfanoid habitus, the remainder of his presentation is more consistent with MEN 2B than Marfan syndrome. In addition, unlike true Marfan syndrome, patients with MEN 2B do not develop aortic malformations (eg, dilation) or ocular malformations (eg, ectopia lentis).

**(Choice C)** Multiple endocrine neoplasia type 1 (MEN 1) is an autosomal dominant condition characterized by parathyroid adenomas with hyperparathyroidism, anterior pituitary gland tumors, and pancreatic endocrine tumors (the "3 Ps"). MEN 1 is not associated with thyroid cancer or perioral nodules.

**(Choices E and F)** Neurofibromatosis type 1 is characterized by café au lait spots, cutaneous neurofibromas, axillary or inguinal freckling, optic glioma, and iris hamartomas. Neurofibromatosis type 2 (the more central form) is characterized by bilateral acoustic neuromas, brain meningiomas, and schwannomas of the dorsal roots in the spinal cord. Although this patient has (mucosal) neuromas, the remainder of his presentation is more consistent with MEN 2B.

**Educational objective:**
Multiple endocrine neoplasia type 2B is characterized by medullary thyroid cancer, pheochromocytoma, marfanoid habitus, and oral and intestinal mucosal neuromas.

**References**

- Mucosal neuromas/marfanoid habitus

Exhibit Display

Zoom In | Zoom Out | Reset | Add To New Card | Existing Card

References

1
2
3
4
5
6
7
8
9
10
11
12
13
14
15
16
17
18
19
20
21
22
23
24
25
26
27
28
29
30
31

- Mucosal neuromas/marfanoid habitus

Exhibit Display

Zoom In | Zoom Out | Reset | Add To New Card | Existing Card

References

1
2
3
4
5
6
7
8
9
10
11
12
13
14
15
16
17
18
19
20
21
22
23
24
25
26
27
28
29
30
31

1
2
3
4
5
6
7
8
9
10
11
12
13
14
15
16
17
18
19
20
21
22
23
24
25
26
27
28
29
30
31

A 60-year-old woman comes to the office due to difficulty climbing stairs and dyspnea on exertion over the last 6 weeks. The patient has a 40-pack-year smoking history. Blood pressure is 160/90 mm Hg and pulse is 78/min. Auscultation of the chest reveals decreased breath sounds over the right lung base. Proximal muscle strength is 4 on a scale of 0-5. Skin examination shows scattered ecchymoses. Laboratory results show mild hyperglycemia and elevated 24-hour urinary free cortisol. Serum cortisol level is at the upper limit of normal and is not suppressed following administration of low-dose dexamethasone. Serum ACTH level is elevated. Chest x-ray reveals a right lower lobe lung mass. Which of the following changes are most likely to occur after administration of high-dose dexamethasone in this patient?

| | ACTH | Cortisol |
|---|---|---|
| A. | Decrease | Decrease |
| B. | Increase | Increase |
| C. | Increase | No change |
| D. | No change | Decrease |
| E. | No change | No change |

Submit

A 60-year-old woman comes to the office due to difficulty climbing stairs and dyspnea on exertion over the last 6 weeks. The patient has a 40-pack-year smoking history. Blood pressure is 160/90 mm Hg and pulse is 78/min. Auscultation of the chest reveals decreased breath sounds over the right lung base. Proximal muscle strength is 4 on a scale of 0-5. Skin examination shows scattered ecchymoses. Laboratory results show mild hyperglycemia and elevated 24-hour urinary free cortisol. Serum cortisol level is at the upper limit of normal and is not suppressed following administration of low-dose dexamethasone. Serum ACTH level is elevated. Chest x-ray reveals a right lower lobe lung mass. Which of the following changes are most likely to occur after administration of high-dose dexamethasone in this patient?

| | ACTH | Cortisol |
|---|---|---|
| A. (5%) | Decrease | Decrease |
| B. (2%) | Increase | Increase |
| C. (1%) | Increase | No change |
| D. (8%) | No change | Decrease |
| ✓ E. (82%) | No change | No change |

Omitted
Correct answer
E

82%
Answered correctly

02 secs
Time Spent

04/23/2020
Last Updated

Explanation

Explanation

| Biochemical findings in Cushing syndrome | | | |
|---|---|---|---|
| **Etiology** | **ACTH** | **Cortisol** | **High-dose dexamethasone suppression test** |
| Pituitary adenoma | ↑ | ↑ | ↓ Cortisol |
| Ectopic ACTH secretion | ↑ | ↑ | Cortisol remains elevated |
| Adrenal adenoma/carcinoma | ↓ | ↑ | |

This patient's hypertension, proximal muscle weakness, and hyperglycemia are suggestive of excess cortisol (ie, **Cushing syndrome** [CS]). Hypercortisolism can be confirmed by finding elevated cortisol levels in a late-night salivary sample or 24-hour urine collection. Additionally, low-dose dexamethasone suppression testing can also be useful for confirming the diagnosis; administration of a small dose of a potent glucocorticoid rapidly suppresses ACTH and cortisol secretion in normal individuals, but patients with CS are resistant to low-dose glucocorticoids so serum cortisol remains elevated.

Once the diagnosis is confirmed, the next step is **establishing the cause** of CS, which involves measurement of serum ACTH levels:

- Low ACTH levels are seen with autonomous adrenal production of cortisol (eg, adrenal adenoma or carcinoma) or exogenous glucocorticoid exposure due to feedback suppression
- **High ACTH** levels occur with pituitary adenomas (ie, Cushing disease) or ectopic ACTH production by nonpituitary tumors, which can be further distinguished with the **high-dose dexamethasone suppression test**:
  - Pituitary sources of ACTH are only relatively resistant to feedback inhibition, and high doses of dexamethasone will suppress ACTH and cortisol levels **(Choice A)**
  - Nonpituitary **ectopic sources** of ACTH (eg, **small cell lung cancer**) are completely resistant to feedback inhibition, and ACTH and cortisol will remain elevated following high doses of dexamethasone

This patient's rapid symptom onset, heavy smoking history, and lung mass are consistent with paraneoplastic CS, likely due to small cell lung cancer. **ACTH and cortisol production** will likely be **unchanged** following high-dose dexamethasone.

1
2
3
4
5
6
7
8
9
10
11
12
13
14
15
16
17
18
19
20
21
22
23
24
25
26
27
28
29
30
31

Hypercortisolism can be confirmed by finding elevated cortisol levels in a late-night salivary sample or 24-hour urine collection. Additionally, low-dose dexamethasone suppression testing can also be useful for confirming the diagnosis; administration of a small dose of a potent glucocorticoid rapidly suppresses ACTH and cortisol secretion in normal individuals, but patients with CS are resistant to low-dose glucocorticoids so serum cortisol remains elevated.

Once the diagnosis is confirmed, the next step is **establishing the cause** of CS, which involves measurement of serum ACTH levels:

- Low ACTH levels are seen with autonomous adrenal production of cortisol (eg, adrenal adenoma or carcinoma) or exogenous glucocorticoid exposure due to feedback suppression
- **High ACTH** levels occur with pituitary adenomas (ie, Cushing disease) or ectopic ACTH production by nonpituitary tumors, which can be further distinguished with the **high-dose dexamethasone suppression test**:
  - Pituitary sources of ACTH are only relatively resistant to feedback inhibition, and high doses of dexamethasone will suppress ACTH and cortisol levels **(Choice A)**
  - Nonpituitary **ectopic sources** of ACTH (eg, **small cell lung cancer**) are completely resistant to feedback inhibition, and ACTH and cortisol will remain elevated following high doses of dexamethasone

This patient's rapid symptom onset, heavy smoking history, and lung mass are consistent with paraneoplastic CS, likely due to small cell lung cancer. **ACTH and cortisol production** will likely be **unchanged** following high-dose dexamethasone.

**(Choices B and C)** In normal individuals, dexamethasone suppresses ACTH release from the pituitary. In patients with abnormal pituitary or ectopic ACTH production, dexamethasone affects ACTH levels as described above. However, dexamethasone does not stimulate ACTH release in any setting.

**(Choice D)** The fall in cortisol seen in dexamethasone suppression tests is due to feedback suppression causing decreased ACTH release. A fall in cortisol would not be seen without a corresponding fall in ACTH.

**Educational objective:**
Cushing syndrome caused by a pituitary adenoma or ectopic (paraneoplastic) ACTH secretion is associated with elevated ACTH levels. High-dose dexamethasone suppresses ACTH and cortisol secretion when Cushing syndrome is caused by a pituitary adenoma (Cushing disease) but not when it is caused by ectopic ACTH secretion (eg, small cell lung cancer).

Hypercortisolism can be confirmed by finding elevated cortisol levels in a late-night salivary sample or 24-hour urine collection. Additionally, low-

**Exhibit Display**

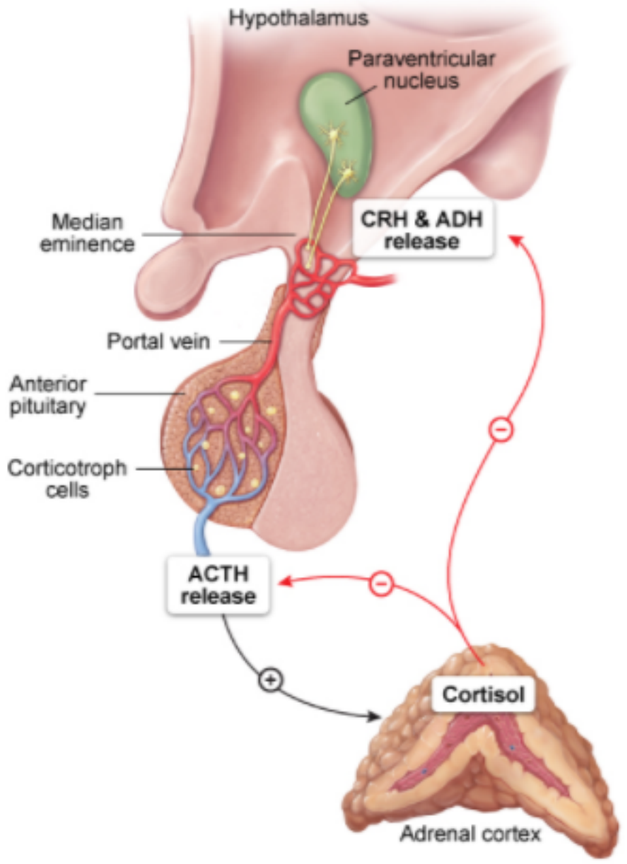


ADH = antidiuretic hormone; CRH = corticotropin-releasing hormone.
©UWorld

Zoom In | Zoom Out | Reset | Add To New Card | Existing Card

not when it is caused by ectopic ACTH secretion (eg, small cell lung cancer).

Hypercortisolism can be confirmed by finding elevated cortisol levels in a late-night salivary sample or 24-hour urine collection. Additionally, low-

**Exhibit Display**

**Diagnosing the cause of Cushing syndrome**

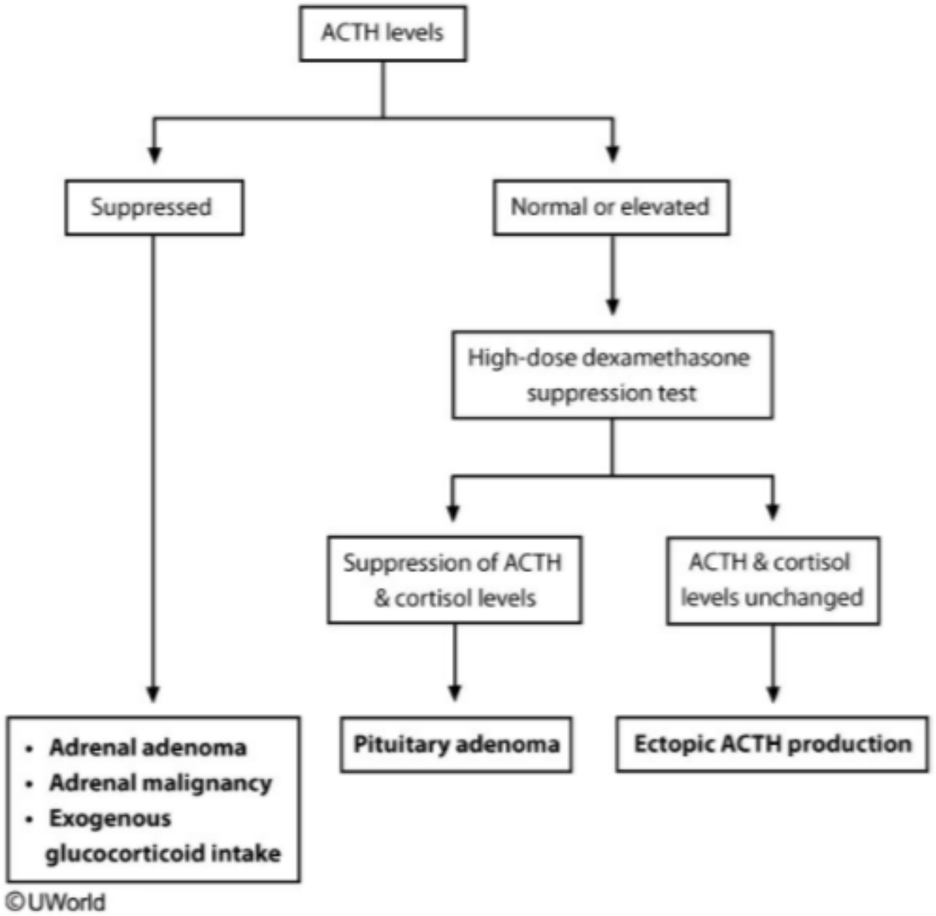


©UWorld

Zoom In | Zoom Out | Reset | Add To New Card | Existing Card

not when it is caused by ectopic ACTH secretion (eg, small cell lung cancer).

- **High ACTH** levels occur with pituitary adenomas (ie, Cushing disease) or ectopic ACTH production by nonpituitary tumors, which can be further distinguished with the **high-dose dexamethasone suppression test**:
  - Pituitary sources of ACTH are only relatively resistant to feedback inhibition, and high doses of dexamethasone will suppress ACTH and cortisol levels **(Choice A)**
  - Nonpituitary **ectopic sources** of ACTH (eg, **small cell lung cancer**) are completely resistant to feedback inhibition, and ACTH and cortisol will remain elevated following high doses of dexamethasone

This patient's rapid symptom onset, heavy smoking history, and lung mass are consistent with paraneoplastic CS, likely due to small cell lung cancer. **ACTH and cortisol production** will likely be **unchanged** following high-dose dexamethasone.

**(Choices B and C)** In normal individuals, dexamethasone suppresses ACTH release from the pituitary. In patients with abnormal pituitary or ectopic ACTH production, dexamethasone affects ACTH levels as described above. However, dexamethasone does not stimulate ACTH release in any setting.

**(Choice D)** The fall in cortisol seen in dexamethasone suppression tests is due to feedback suppression causing decreased ACTH release. A fall in cortisol would not be seen without a corresponding fall in ACTH.

**Educational objective:**
Cushing syndrome caused by a pituitary adenoma or ectopic (paraneoplastic) ACTH secretion is associated with elevated ACTH levels. High-dose dexamethasone suppresses ACTH and cortisol secretion when Cushing syndrome is caused by a pituitary adenoma (Cushing disease) but not when it is caused by ectopic ACTH secretion (eg, small cell lung cancer).

**References**

- Ectopic Cushing's syndrome in light of modern diagnostic techniques and treatment options.

| Pathology | Endocrine, Diabetes & Metabolism | Cushing syndrome |
|---|---|---|
| Subject | System | Topic |

Copyright © UWorld. All rights reserved.

1
2
3
4
5
6
7
8
9
10
11
12
13
14
15
16
17
18
19
20
21
22
23
24
25
26
27
28
29
30
31

A 46-year-old woman comes to the office with a painful rash involving her groin and legs that has been worsening over the last 2 weeks. She was diagnosed with diabetes mellitus 6 months ago but has no other medical problems other than occasional loose stools. Physical examination shows coalescing erythematous plaques with crusting and scaling at the borders and central areas of brownish induration. Biopsy of the lesions reveals superficial necrolysis. Which of the following laboratory abnormalities is most likely to be present in this patient?

A. Elevated amino acids
B. Elevated gastrin
C. Elevated glucagon
D. Elevated somatostatin
E. Elevated vasoactive intestinal polypeptide
F. Low insulin
G. Low zinc

Submit

A 46-year-old woman comes to the office with a painful rash involving her groin and legs that has been worsening over the last 2 weeks. She was diagnosed with diabetes mellitus 6 months ago but has no other medical problems other than occasional loose stools. Physical examination shows coalescing erythematous plaques with crusting and scaling at the borders and central areas of brownish induration. Biopsy of the lesions reveals superficial necrolysis. Which of the following laboratory abnormalities is most likely to be present in this patient?

- A. Elevated amino acids (3%)
- B. Elevated gastrin (2%)
- ✓ C. Elevated glucagon (30%)
- D. Elevated somatostatin (4%)
- E. Elevated vasoactive intestinal polypeptide (9%)
- F. Low insulin (10%)
- G. Low zinc (38%)

Omitted
Correct answer
C

30%
Answered correctly

02 secs
Time Spent

03/06/2020
Last Updated

Explanation

| Features of glucagonoma | |
|---|---|
| | • Necrolytic migratory erythema |

Explanation

| Features of glucagonoma | |
|---|---|
| **Clinical presentation** | • **Necrolytic migratory erythema**<br>• Erythematous papules/plaques on face, perineum & extremities<br>• Lesions enlarge & coalesce, leaving a central indurated area with peripheral blistering & scaling<br>• **Diabetes mellitus**/hyperglycemia<br>• Gastrointestinal symptoms (diarrhea, anorexia, abdominal pain) |
| **Diagnosis** | • Markedly elevated glucagon levels |

This patient most likely has a **glucagonoma**, a rare tumor arising from the **alpha cells** of the pancreatic islets of Langerhans. Glucagonomas secrete large quantities of glucagon, so affected patients often have **hyperglycemia** or overt **diabetes mellitus**. A characteristic skin finding is **necrolytic migratory erythema**, an elevated painful and pruritic rash typically affecting the face, groin, and extremities. Over time, small erythematous papules coalesce to form large, indurated plaques with a central clearing that often appears brown or bronze-colored. Diagnosis is made by detecting elevated levels of **glucagon** in the serum.

**(Choice A)** Glucagon acts on the liver to promote amino acid oxidation and gluconeogenesis from amino acids. Circulating levels of amino acids are low in glucagonoma and thought to contribute to development of necrolytic migratory erythema.

**(Choice B)** Elevated gastrin levels in patients with gastrinoma are associated with hypersecretion of gastric acid and resultant gastrointestinal ulceration. The peptic ulcers that occur with gastrinomas are often in unusual areas, such as the jejunum. Patients with gastrinomas can also have diarrhea and abdominal pain.

**(Choice D)** Excess somatostatin secretion from a somatostatinoma typically presents with abdominal pain, gallbladder stones, constipation, hyperglycemia, and steatorrhea. These manifestations result from somatostatin-induced inhibition of insulin, glucagon, gastrin, secretin, and cholecystokinin secretion, and inhibition of gastrointestinal motility.

**(Choice E)** High levels of vasoactive intestinal polypeptide (VIP) are seen in patients with a VIPoma, which typically presents with intractable diarrhea, hypokalemia, and achlorhydria. Patients are usually hypotensive due to dehydration and the vasodilatory effects of VIP.

1
2
3
4
5
6
7
8
9
10
11
12
13
14
15
16
17
18
19
20
21
22
23
24
25
26
27
28
29
30
31

have diarrhea and abdominal pain.

**(Choice D)** Excess somatostatin secretion from a somatostatinoma typically presents with abdominal pain, gallbladder stones, constipation, hyperglycemia, and steatorrhea. These manifestations result from somatostatin-induced inhibition of insulin, glucagon, gastrin, secretin, and cholecystokinin secretion, and inhibition of gastrointestinal motility.

**(Choice E)** High levels of vasoactive intestinal polypeptide (VIP) are seen in patients with a VIPoma, which typically presents with intractable diarrhea, hypokalemia, and achlorhydria. Patients are usually hypotensive due to dehydration and the vasodilatory effects of VIP.

**(Choice F)** Diabetes mellitus is present in the majority of patients with glucagonoma, most likely due to excessive hepatic glucose production. Insulin levels tend to be normal but can be elevated secondary to hyperglycemia and glucagon-induced stimulation of the pancreatic beta cells.

**(Choice G)** Zinc deficiency causes erythematous skin lesions (mainly around body orifices) that are predominantly vesicular and pustular. Other features include hypogonadism, impaired taste and smell, night blindness, and impaired wound healing. Although the skin lesions in zinc deficiency can resemble necrolytic migratory erythema, this patient's lack of additional findings and her recent diabetes mellitus diagnosis make glucagonoma more likely.

**Educational objective:**
Glucagonoma presents with hyperglycemia (often as newly diagnosed diabetes mellitus) and necrolytic migratory erythema (blistering erythematous plaques with central clearing) affecting the groin, face, and extremities. The diagnosis is made by detecting elevated glucagon levels.

**References**

- The glucagonoma syndrome. Clinical and pathologic features in 21 patients.
- Etiology and pathogenesis of necrolytic migratory erythema: review of the literature

| Pathology | Endocrine, Diabetes & Metabolism | Neuroendocrine tumors |
|---|---|---|
| Subject | System | Topic |

Copyright © UWorld. All rights reserved.

mother and sister have hypothyroidism. Blood pressure is 100/70 mm Hg supine and 80/50 mm Hg standing. Laboratory results are as follows:

| | |
|---|---|
| Sodium | 129 mEq/L |
| Potassium | 5.9 mEq/L |
| Chloride | 100 mEq/L |
| Bicarbonate | 21 mEq/L |
| Creatinine | 1.4 mg/dL |
| Blood urea nitrogen | 38 mg/dL |

Which of the following changes in circulating hormone levels are expected in this patient?

| | Cortisol | Aldosterone | Antidiuretic hormone | Norepinephrine |
|---|---|---|---|---|
| A. | ↓ | ↓ | ↑ | ↑ |
| B. | Normal | Normal | ↑ | Normal |
| C. | Normal | ↑ | ↑ | ↑ |
| D. | ↓ | ↑ | ↑ | ↑ |
| E. | ↑ | ↑ | ↑ | ↑ |
| F. | ↑ | ↓ | ↓ | ↓ |

Submit

A 37-year-old woman comes to the office due to a two-month history of abdominal pain, salt craving, and weight loss. She also has dizziness on standing. The patient has no chronic medical conditions and takes no medications. She does not use tobacco, alcohol, or illicit drugs. Her mother and sister have hypothyroidism. Blood pressure is 100/70 mm Hg supine and 80/50 mm Hg standing. Laboratory results are as follows:

| | |
|---|---|
| Sodium | 129 mEq/L |
| Potassium | 5.9 mEq/L |
| Chloride | 100 mEq/L |
| Bicarbonate | 21 mEq/L |
| Creatinine | 1.4 mg/dL |
| Blood urea nitrogen | 38 mg/dL |

Which of the following changes in circulating hormone levels are expected in this patient?

| | Cortisol | Aldosterone | Antidiuretic hormone | Norepinephrine |
|---|---|---|---|---|
| A. | ↓ | ↓ | ↑ | ↑ |
| B. | Normal | Normal | ↑ | Normal |
| C. | Normal | ↑ | ↑ | ↑ |
| D. | ↓ | ↑ | ↑ | ↑ |
| E. | ↑ | ↑ | ↑ | ↑ |
| F. | ↑ | ↓ | ↓ | ↓ |

mother and sister have hypothyroidism. Blood pressure is 100/70 mm Hg supine and 80/50 mm Hg standing. Laboratory results are as follows:

| | |
|---|---|
| Sodium | 129 mEq/L |
| Potassium | 5.9 mEq/L |
| Chloride | 100 mEq/L |
| Bicarbonate | 21 mEq/L |
| Creatinine | 1.4 mg/dL |
| Blood urea nitrogen | 38 mg/dL |

Which of the following changes in circulating hormone levels are expected in this patient?

| | Cortisol | Aldosterone | Antidiuretic hormone | Norepinephrine |
|---|---|---|---|---|
| ✓ A. (66%) | ↓ | ↓ | ↑ | ↑ |
| B. (2%) | Normal | Normal | ↑ | Normal |
| C. (5%) | Normal | ↑ | ↑ | ↑ |
| D. (6%) | ↓ | ↑ | ↑ | ↑ |
| E. (7%) | ↑ | ↑ | ↑ | ↑ |
| F. (12%) | ↑ | ↓ | ↓ | ↓ |

This patient has multiple signs and symptoms of **primary adrenal insufficiency** (PAI) (also known as Addison disease), including abdominal pain, weight loss, salt craving, orthostasis (dizziness on standing), and electrolyte disturbance. PAI usually results from autoimmune destruction of the bilateral adrenal cortex and is more likely to occur in patients with a personal or family **history of autoimmune disease** (eg, Hashimoto thyroiditis). Because all 3 layers of the adrenal cortex are affected, clinical manifestations result from a reduction in circulating mineralocorticoids, glucocorticoids, and androgens.

**Reduced aldosterone**, the principal mineralocorticoid in the body, leads to markedly decreased sodium absorption by the renal collecting tubule principal cells with consequent retention of potassium (leading to **hyperkalemia**). The decrease in total body sodium results in **hypovolemia** and **hypotension** that may lead to renal insufficiency. The hypovolemia provides nonosmotic stimulus for **antidiuretic hormone (ADH) secretion**, which stimulates water retention and leads to **hyponatremia**.

Cortisol, the main glucocorticoid in the body, normally inhibits ADH secretion; therefore, **reduced cortisol** further contributes to hyponatremia. Cortisol is also necessary for the synthesis of epinephrine in the adrenal medulla; the consequent reduction in circulating epinephrine leads to a compensatory **increase in norepinephrine** to increase vascular tone in an effort to maintain blood pressure.

**(Choice B)** Increased ADH and normal levels of cortisol, aldosterone, and norepinephrine occur in the syndrome of inappropriate ADH secretion (SIADH). SIADH presents with hyponatremia, but it does not explain this patient's hyperkalemia, salt craving, and orthostatic symptoms.

**(Choices C, D, and E)** Elevations in aldosterone, ADH, and norepinephrine occur in conditions that decrease effective arterial blood volume and renal perfusion (eg, heart failure, cirrhosis, dehydration). Cortisol levels are often elevated in dehydration and heart failure; total cortisol is low in cirrhosis due to reduced cortisol-binding protein levels.

**(Choice F)** Increased cortisol with reduced levels of aldosterone, ADH, and norepinephrine can occur with ectopic ACTH production (eg, due to small cell lung cancer). Aldosterone synthesis is mostly independent of ACTH and is suppressed because cortisol and other glucocorticoids have some mineralocorticoid activity. Levels of ADH and norepinephrine are also generally suppressed.

**Educational objective:**
Primary adrenal insufficiency usually involves autoimmune destruction of the bilateral adrenal cortex. Reduced aldosterone production leads to renal salt wasting with hypovolemia, hypotension, and hyperkalemia. The hypovolemia and reduced cortisol-induced inhibition of antidiuretic hormone lead to water retention and hyponatremia. Reduced cortisol also causes decreased circulating epinephrine with a compensatory increase in norepinephrine.

This patient has multiple signs and symptoms of **primary adrenal insufficiency** (PAI) (also known as Addison disease), including abdominal pain

**Exhibit Display**

## Adrenal cortical structure & function

| Principal stimulatory hormone | Adrenal layer | Principal secreted hormone | Physiologic effect |
|---|---|---|---|
| Angiotensin II | Zona glomerulosa | Aldosterone | ↑ Blood volume |
| ACTH | Zona fasciculata | Cortisol | ↑ Vascular tone<br>↑ Blood glucose |
| ACTH | Zona reticularis | Androgens | Libido & pubic hair in women |
| | Medulla | | |

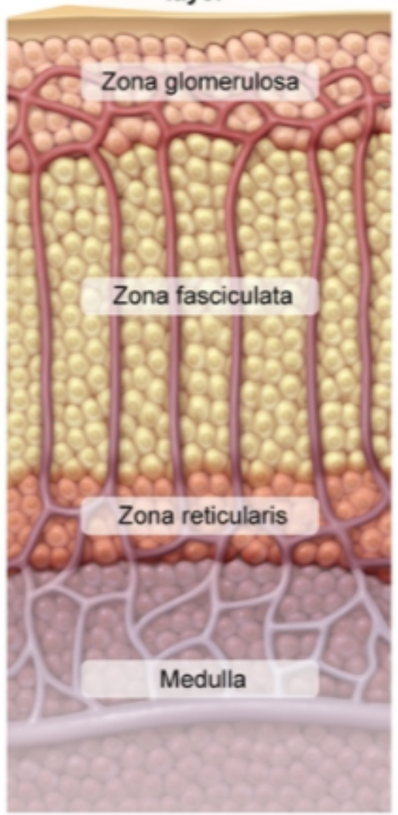

©UWorld

Zoom In Zoom Out Reset Add To Flash Card

increase in norepinephrine.

This patient has multiple signs and symptoms of **primary adrenal insufficiency** (PAI) (also known as Addison disease), including abdominal pain

**Exhibit Display**

**Action of aldosterone in the collecting duct of the nephron**

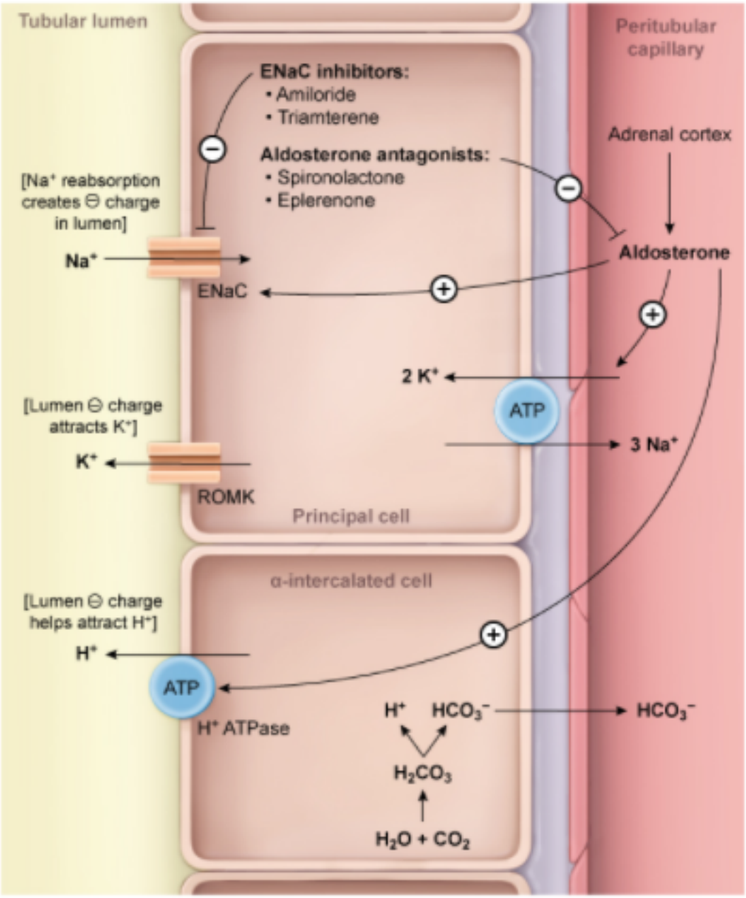


Zoom In Zoom Out Reset Add To Flash Card

increase in norepinephrine.

**Reduced aldosterone**, the principal mineralocorticoid in the body, leads to markedly decreased sodium absorption by the renal collecting tubule principal cells with consequent retention of potassium (leading to **hyperkalemia**). The decrease in total body sodium results in **hypovolemia** and **hypotension** that may lead to renal insufficiency. The hypovolemia provides nonosmotic stimulus for **antidiuretic hormone (ADH) secretion**, which stimulates water retention and leads to **hyponatremia**.

Cortisol, the main glucocorticoid in the body, normally inhibits ADH secretion; therefore, **reduced cortisol** further contributes to hyponatremia. Cortisol is also necessary for the synthesis of epinephrine in the adrenal medulla; the consequent reduction in circulating epinephrine leads to a compensatory **increase in norepinephrine** to increase vascular tone in an effort to maintain blood pressure.

**(Choice B)** Increased ADH and normal levels of cortisol, aldosterone, and norepinephrine occur in the syndrome of inappropriate ADH secretion (SIADH). SIADH presents with hyponatremia, but it does not explain this patient's hyperkalemia, salt craving, and orthostatic symptoms.

**(Choices C, D, and E)** Elevations in aldosterone, ADH, and norepinephrine occur in conditions that decrease effective arterial blood volume and renal perfusion (eg, heart failure, cirrhosis, dehydration). Cortisol levels are often elevated in dehydration and heart failure; total cortisol is low in cirrhosis due to reduced cortisol-binding protein levels.

**(Choice F)** Increased cortisol with reduced levels of aldosterone, ADH, and norepinephrine can occur with ectopic ACTH production (eg, due to small cell lung cancer). Aldosterone synthesis is mostly independent of ACTH and is suppressed because cortisol and other glucocorticoids have some mineralocorticoid activity. Levels of ADH and norepinephrine are also generally suppressed.

**Educational objective:**
Primary adrenal insufficiency usually involves autoimmune destruction of the bilateral adrenal cortex. Reduced aldosterone production leads to renal salt wasting with hypovolemia, hypotension, and hyperkalemia. The hypovolemia and reduced cortisol-induced inhibition of antidiuretic hormone lead to water retention and hyponatremia. Reduced cortisol also causes decreased circulating epinephrine with a compensatory increase in norepinephrine.

| Pathology | Endocrine, Diabetes & Metabolism | Adrenal insufficiency |
|---|---|---|
| Subject | System | Topic |

Copyright © UWorld. All rights reserved.

1
2
3
4
5
6
7
8
9
10
11
12
13
14
15
16
17
18
19
20
21
22
23
24
25
26
27
28
29
30
31

A 30-year-old man comes to the office with a neck lump. The patient is otherwise asymptomatic and discovered the nodule incidentally while showering. His medical history is significant for a recently diagnosed pheochromocytoma, which was successfully removed. The patient's father died of thyroid cancer in his 30s. An ultrasound reveals a hypoechoic 3-cm nodule in the right lobe of the thyroid gland. Fine-needle biopsy of the nodule is consistent with a subtype of thyroid cancer. The patient undergoes total thyroidectomy with central neck dissection. Which of the following is the most likely histological finding?

A. Branching structures with interspersed calcified bodies

B. Follicular hyperplasia with tall cells forming intrafollicular projections

C. Nests of polygonal cells with Congo red-positive deposits

D. Pleomorphic giant cell nests with occasional multinucleated cells

E. Sheets of uniform cells forming small follicles

Submit

1
2
3
4
5
6
7
8
9
10
11
12
13
14
15
16
17
18
19
20
21
22
23
24
25
26
27
28
29
30
31

A 30-year-old man comes to the office with a neck lump. The patient is otherwise asymptomatic and discovered the nodule incidentally while showering. His medical history is significant for a recently diagnosed pheochromocytoma, which was successfully removed. The patient's father died of thyroid cancer in his 30s. An ultrasound reveals a hypoechoic 3-cm nodule in the right lobe of the thyroid gland. Fine-needle biopsy of the nodule is consistent with a subtype of thyroid cancer. The patient undergoes total thyroidectomy with central neck dissection. Which of the following is the most likely histological finding?

A. Branching structures with interspersed calcified bodies (14%)

B. Follicular hyperplasia with tall cells forming intrafollicular projections (12%)

✓ C. Nests of polygonal cells with Congo red-positive deposits (54%)

D. Pleomorphic giant cell nests with occasional multinucleated cells (6%)

E. Sheets of uniform cells forming small follicles (10%)

Omitted
Correct answer
C

54%
Answered correctly

03 secs
Time Spent

03/27/2020
Last Updated

Explanation

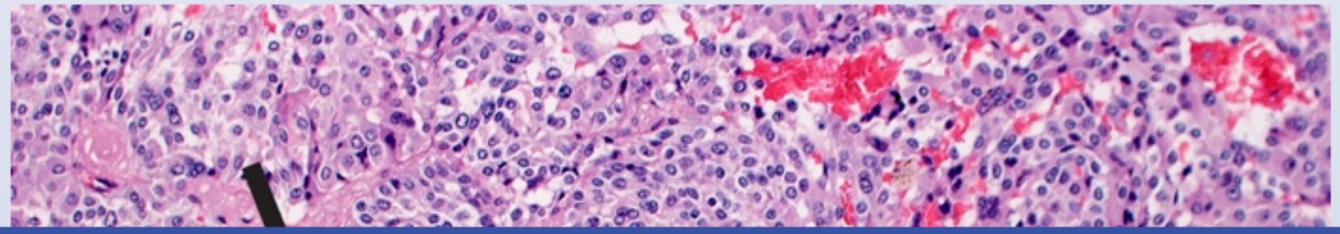

1
2
3
4
5
6
7
8
9
10
11
12
13
14
15
16
17
18
19
20
21
22
23
24
25
26
27
28
29
30
31

Explanation

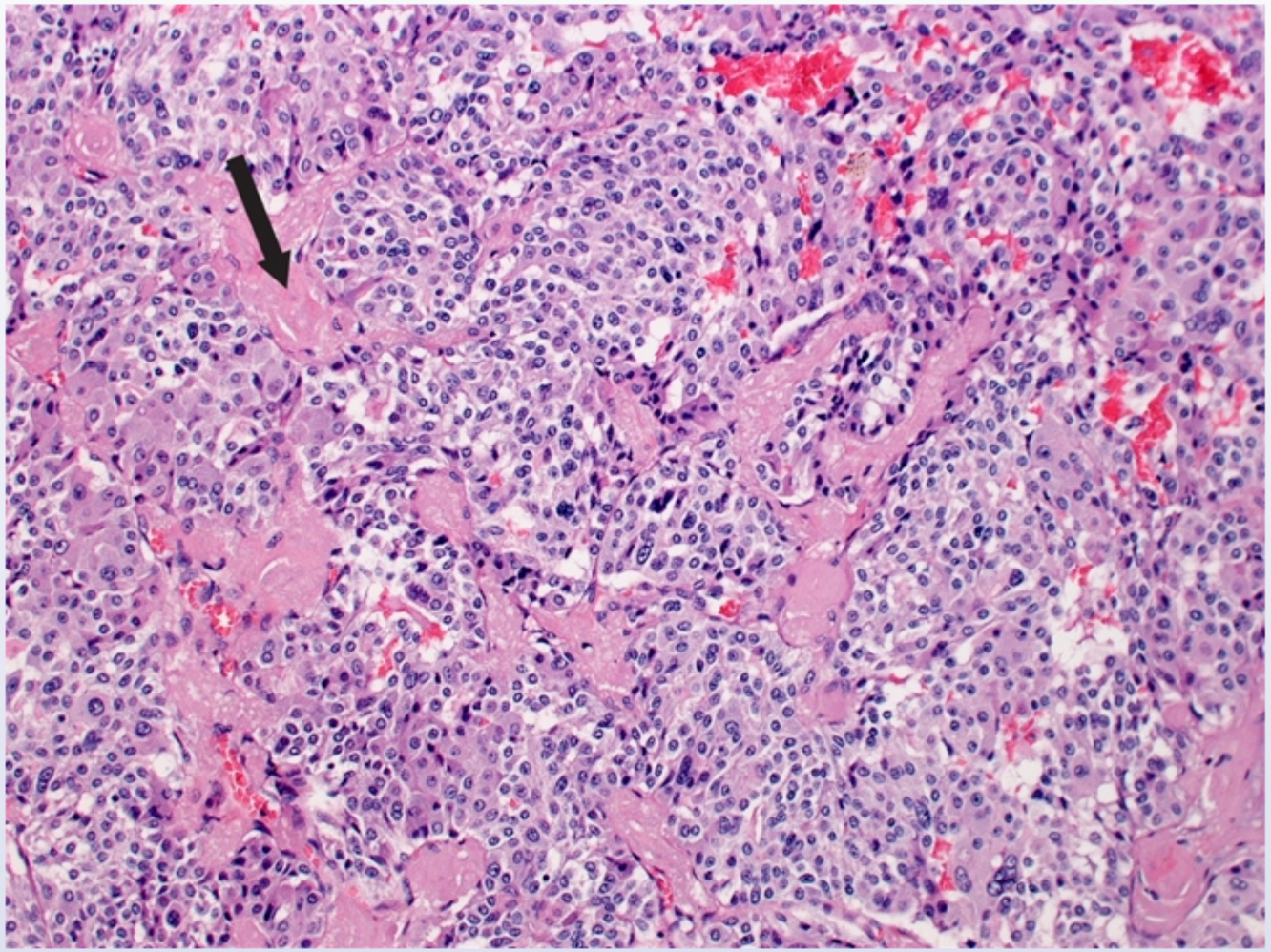

This patient has a personal history of pheochromocytoma and a family history of thyroid cancer. His new thyroid malignancy therefore raises suspicion for **multiple endocrine neoplasia type 2** (MEN2), which is characterized by:

1
2
3
4
5
6
7
8
9
10
11
12
13
14
15
16
17
18
19
20
21
22
23
24
25
26
27
28
29
30
31

This patient has a personal history of pheochromocytoma and a family history of thyroid cancer. His new thyroid malignancy therefore raises suspicion for **multiple endocrine neoplasia type 2** (MEN2), which is characterized by:

- **Medullary thyroid cancer**
- Pheochromocytoma
- Either parathyroid hyperplasia (type 2A) or marfanoid habitus and mucosal neuromas (type 2B)

Approximately 20% of medullary thyroid cancers are familial, occurring as part of MEN2 or familial medullary thyroid cancer syndrome due to germ-line mutations of the RET proto-oncogene. Medullary thyroid cancer is a neuroendocrine tumor that arises from **parafollicular calcitonin-secreting C cells**. Nests or sheets of polygonal or spindle-shaped cells with extracellular amyloid deposits are seen microscopically. These amyloid deposits (black arrow in the image above) are derived from calcitonin secreted by the neoplastic C cells and stain with Congo red. Despite overproduction of calcitonin, hypocalcemia is not a prominent feature.

**(Choice A)** Gross inspection of papillary thyroid cancer may reveal formation of visible papillae. Microscopic inspection of papillae shows a fibrovascular core, often with laminar calcifications (psammoma bodies). The cells contain pale nuclei with finely dispersed chromatin, giving them an empty or ground-glass appearance (Orphan Annie eye nuclei). Intranuclear inclusions and grooves can be seen due to invagination of the nuclear membrane.

**(Choice B)** The tall cell variant of papillary thyroid cancer is characterized by follicular hyperplasia lined by tall epithelial cells; this variant is seen in older individuals and carries a relatively worse prognosis. Tall, crowded cells can also be seen in Graves disease, often with hyperactive resorption of colloid leading to scalloping of the colloid edges.

**(Choice D)** Anaplastic thyroid cancer is an aggressive tumor with a very poor prognosis. It is most common in older patients (age >60). Cytologic features include markedly pleomorphic cells, including irregular giant cells and biphasic spindle cells.

**(Choice E)** The presence of colloid-containing microfollicles suggests a benign follicular adenoma. Well-differentiated follicular adenocarcinoma can also contain small follicles but will often show vascular invasion.

**Educational objective:**
Medullary thyroid cancer is a neuroendocrine tumor that arises from parafollicular calcitonin-secreting C cells. It is characterized by nests or sheets of polygonal or spindle-shaped cells with extracellular amyloid deposits derived from calcitonin.

1
2
3
4
5
6
7
8
9
10
11
12
13
14
15
16
17
18
19
20
21
22
23
24
25
26
27
28
29
30
31

Exhibit Display

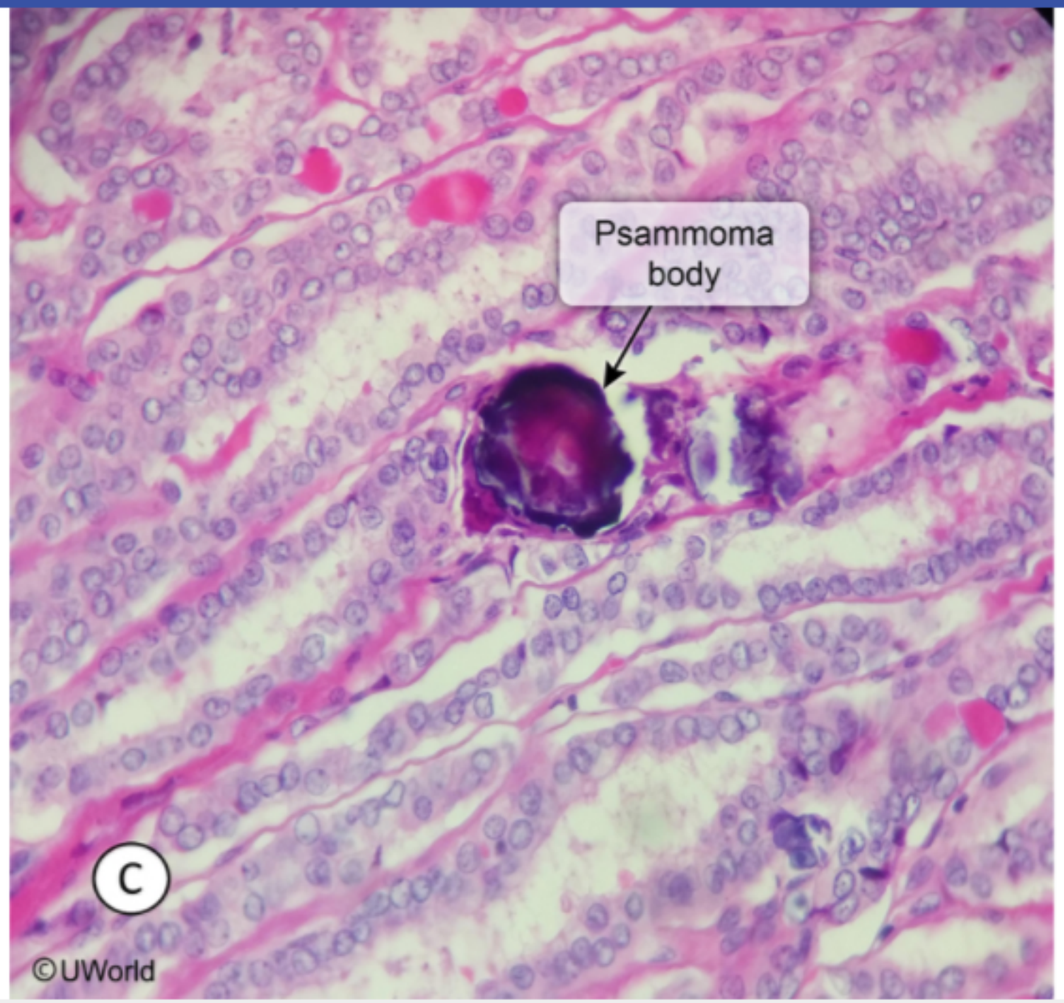


Zoom In | Zoom Out | Reset | Add To New Card | Existing Card

sheets of polygonal or spindle-shaped cells with extracellular amyloid deposits derived from calcitonin.

1
2
3
4
5
6
7
8
9
10
11
12
13
14
15
16
17
18
19
20
21
22
23
24
25
26
27
28
29
30
31

Exhibit Display

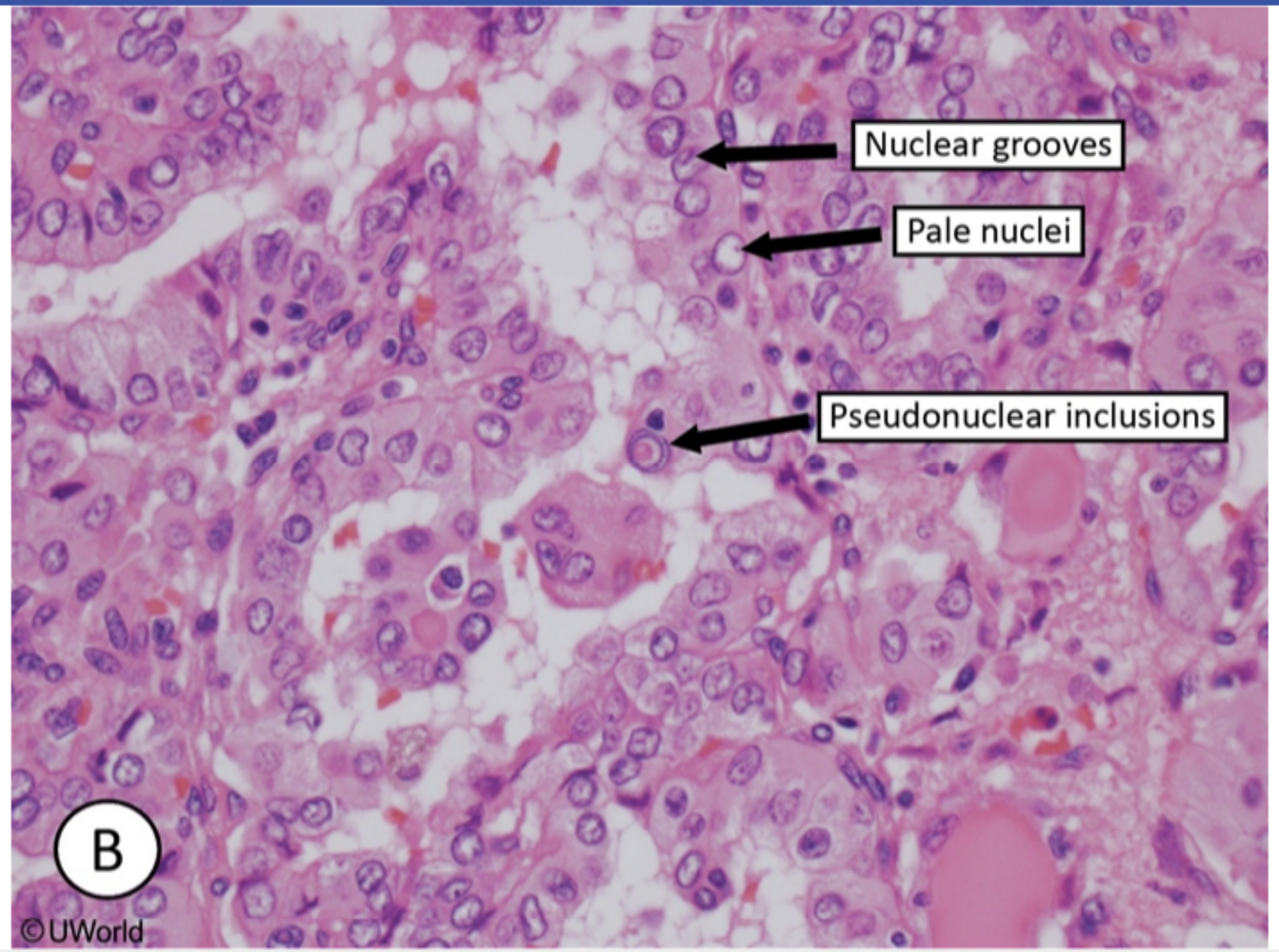


Zoom In | Zoom Out | Reset | Add To New Card | Existing Card

sheets of polygonal or spindle-shaped cells with extracellular amyloid deposits derived from calcitonin.

1
2
3
4
5
6
7
8
9
10
11
12
13
14
15
16
17
18
19
20
21
22
23
24
25
26
27
28
29
30
31

Exhibit Display

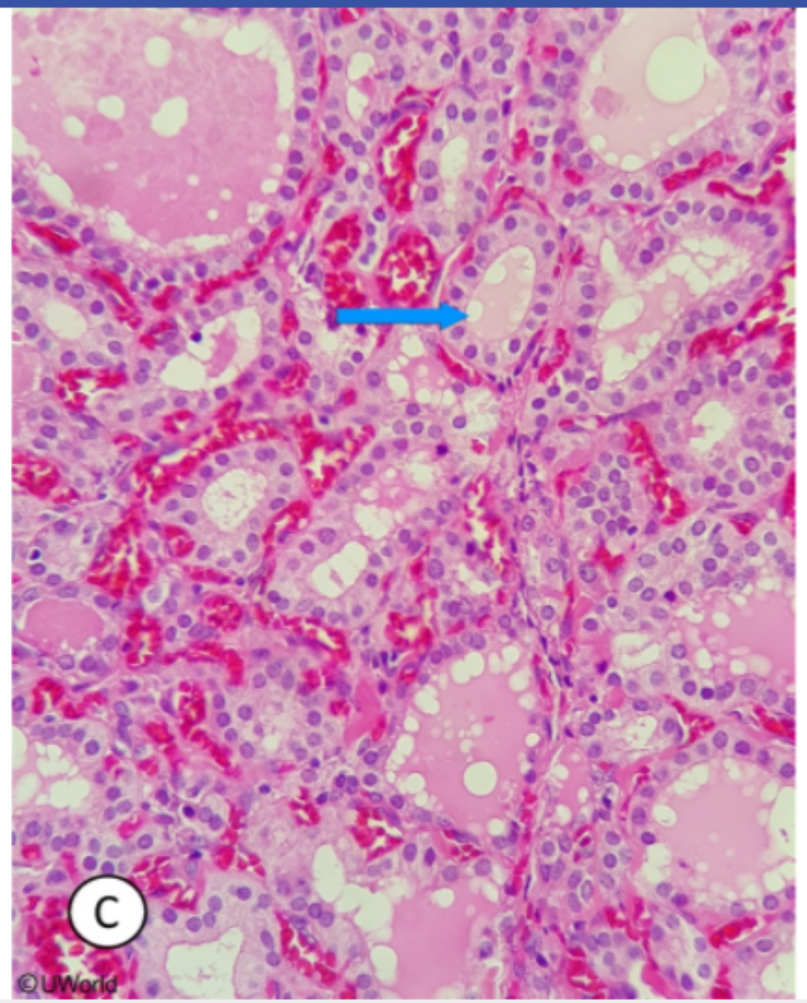


Zoom In | Zoom Out | Reset | Add To New Card | Existing Card

sheets of polygonal or spindle-shaped cells with extracellular amyloid deposits derived from calcitonin.

1
2
3
4
5
6
7
8
9
10
11
12
13
14
15
16
17
18
19
20
21
22
23
24
25
26
27
28
29
30
31

Exhibit Display

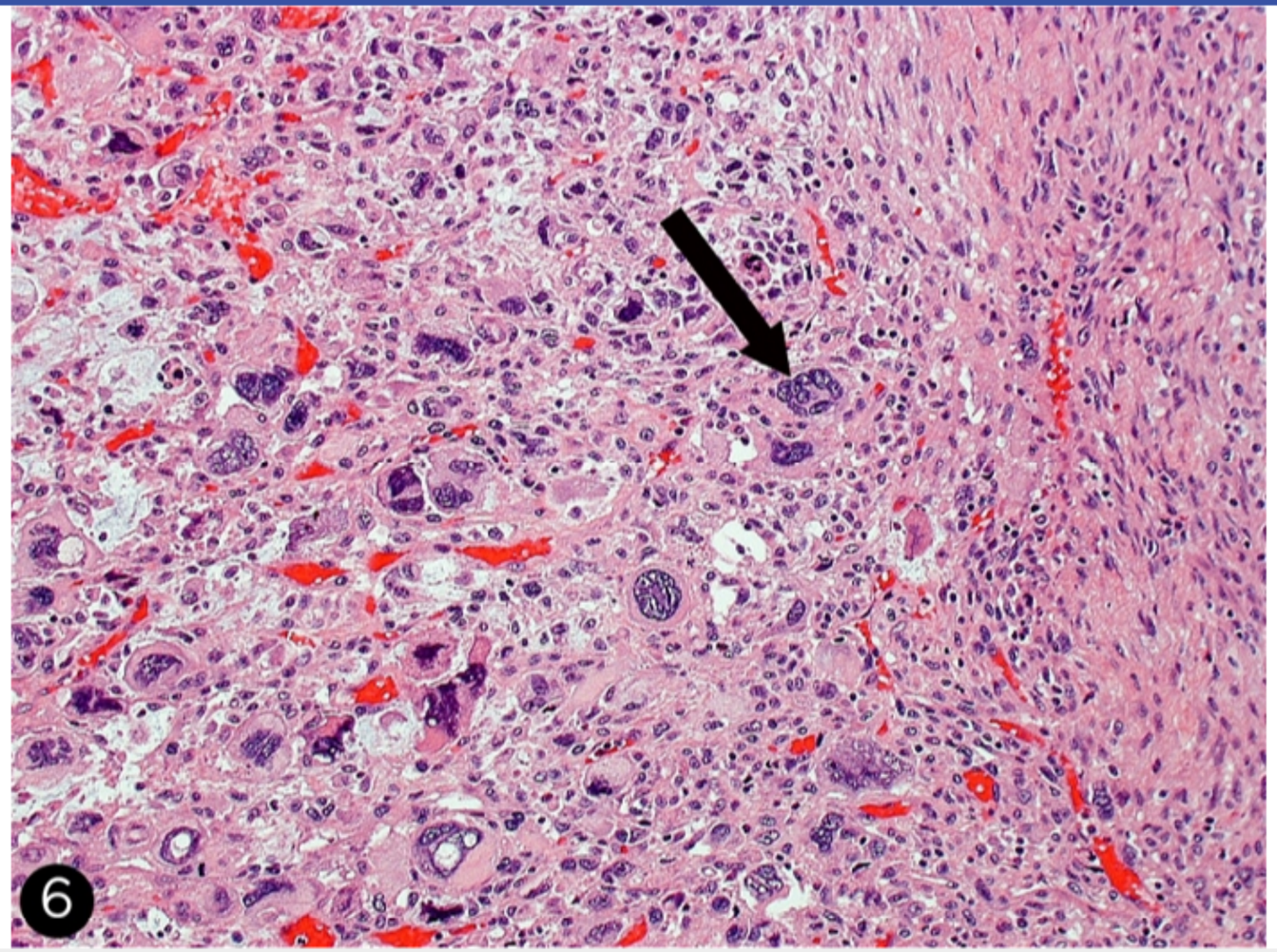


Zoom In Zoom Out Reset Add To New Card | Existing Card

sheets of polygonal or spindle-shaped cells with extracellular amyloid deposits derived from calcitonin.

1
2
3
4
5
6
7
8
9
10
11
12
13
14
15
16
17
18
19
20
21
22
23
24
25
26
27
28
29
30
31

Exhibit Display

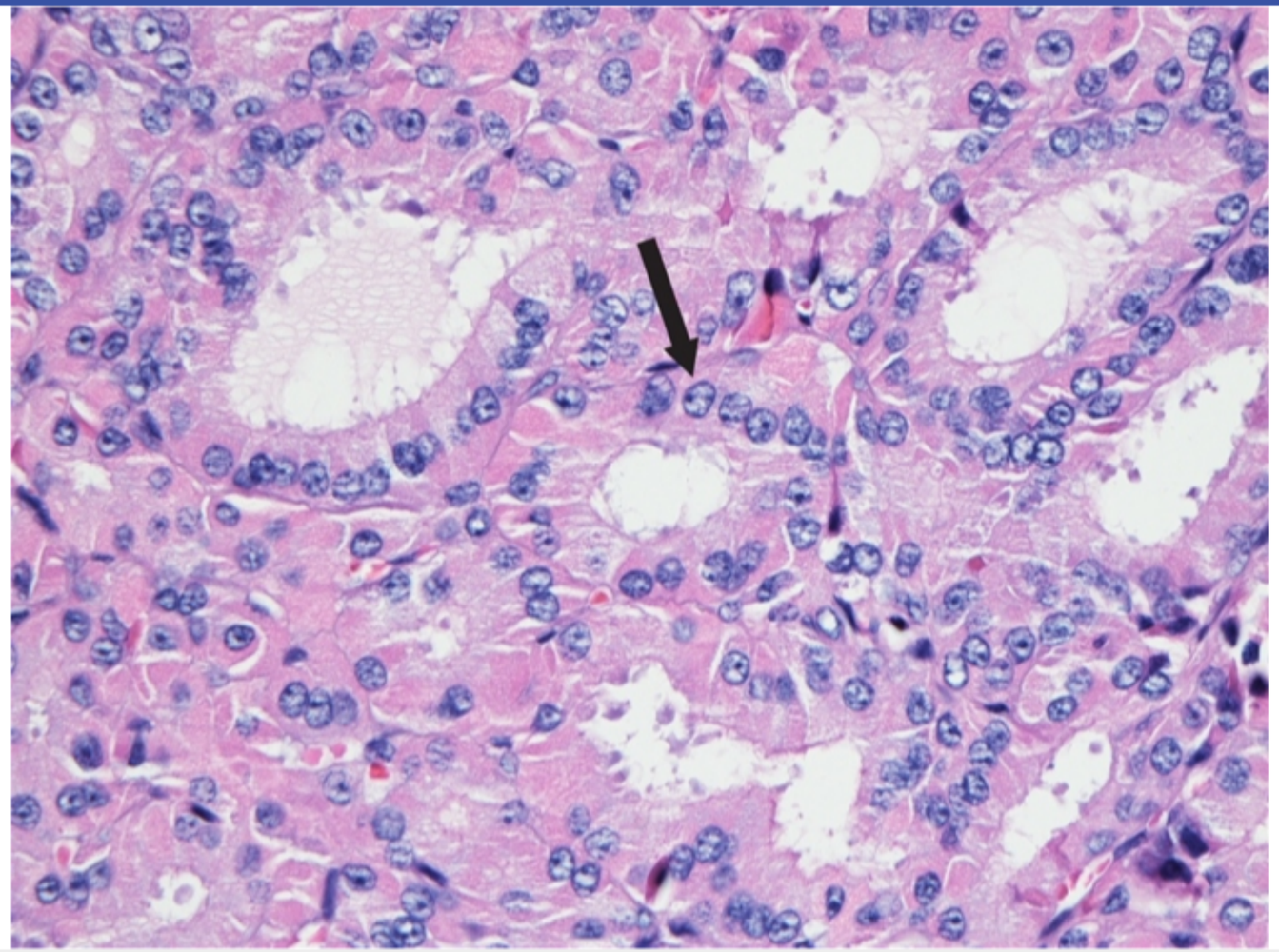

Zoom In | Zoom Out | Reset | Add To New Card | Existing Card

sheets of polygonal or spindle-shaped cells with extracellular amyloid deposits derived from calcitonin.

1 2 3 4 5 6 7 8 9 10 11 12 13 14 15 16 17 18 19 20 21 22 23 24 25 26 27 28 29 30 31

germ-line mutations of the RET proto-oncogene. Medullary thyroid cancer is a neuroendocrine tumor that arises from **parafollicular calcitonin-secreting C cells**. Nests or sheets of polygonal or spindle-shaped cells with extracellular amyloid deposits are seen microscopically. These amyloid deposits (black arrow in the image above) are derived from calcitonin secreted by the neoplastic C cells and stain with Congo red. Despite overproduction of calcitonin, hypocalcemia is not a prominent feature.

**(Choice A)** Gross inspection of papillary thyroid cancer may reveal formation of visible papillae. Microscopic inspection of papillae shows a fibrovascular core, often with laminar calcifications (psammoma bodies). The cells contain pale nuclei with finely dispersed chromatin, giving them an empty or ground-glass appearance (Orphan Annie eye nuclei). Intranuclear inclusions and grooves can be seen due to invagination of the nuclear membrane.

**(Choice B)** The tall cell variant of papillary thyroid cancer is characterized by follicular hyperplasia lined by tall epithelial cells; this variant is seen in older individuals and carries a relatively worse prognosis. Tall, crowded cells can also be seen in Graves disease, often with hyperactive resorption of colloid leading to scalloping of the colloid edges.

**(Choice D)** Anaplastic thyroid cancer is an aggressive tumor with a very poor prognosis. It is most common in older patients (age >60). Cytologic features include markedly pleomorphic cells, including irregular giant cells and biphasic spindle cells.

**(Choice E)** The presence of colloid-containing microfollicles suggests a benign follicular adenoma. Well-differentiated follicular adenocarcinoma can also contain small follicles but will often show vascular invasion.

**Educational objective:**
Medullary thyroid cancer is a neuroendocrine tumor that arises from parafollicular calcitonin-secreting C cells. It is characterized by nests or sheets of polygonal or spindle-shaped cells with extracellular amyloid deposits derived from calcitonin.

**References**

- Update on the cytologic and molecular features of medullary thyroid carcinoma.

| Pathology | Endocrine, Diabetes & Metabolism | Thyroid cancer |
|---|---|---|
| Subject | System | Topic |

Copyright © UWorld. All rights reserved.

1
2
3
4
5
6
7
8
9
10
11
12
13
14
15
16
17
18
19
20
21
22
23
24
25
26
27
28
29
30
31

A 40-year-old man comes to the office due to recurrent epigastric abdominal pain, nausea, and watery diarrhea for the past several months. The patient has had similar burning pain previously and was treated for peptic ulcer disease. He has been taking over-the-counter antacids but with no significant symptom relief. The patient does not use tobacco, alcohol, or illicit drugs. Vital signs are within normal limits. Abdominal examination shows mild epigastric tenderness and increased bowel sounds. Testing for stool occult blood is positive, and laboratory studies show microcytic hypochromic anemia. Serum gastrin level is markedly elevated. Upper gastrointestinal endoscopy reveals prominent gastric folds and multiple ulcers in the duodenum and proximal jejunum. Given these findings, this patient should be assessed for a personal or family history of which of the following conditions?

A. Cerebellar hemangioblastomas

B. Mucosal neuromas

C. Plexiform neurofibromas

D. Recurrent nephrolithiasis

E. Thyroid malignancy

Submit

A 40-year-old man comes to the office due to recurrent epigastric abdominal pain, nausea, and watery diarrhea for the past several months. The patient has had similar burning pain previously and was treated for peptic ulcer disease. He has been taking over-the-counter antacids but with no significant symptom relief. The patient does not use tobacco, alcohol, or illicit drugs. Vital signs are within normal limits. Abdominal examination shows mild epigastric tenderness and increased bowel sounds. Testing for stool occult blood is positive, and laboratory studies show microcytic hypochromic anemia. Serum gastrin level is markedly elevated. Upper gastrointestinal endoscopy reveals prominent gastric folds and multiple ulcers in the duodenum and proximal jejunum. Given these findings, this patient should be assessed for a personal or family history of which of the following conditions?

- A. Cerebellar hemangioblastomas (5%)
- B. Mucosal neuromas (16%)
- C. Plexiform neurofibromas (7%)
- ✓ D. Recurrent nephrolithiasis (37%)
- E. Thyroid malignancy (33%)

Omitted
Correct answer
D

37%
Answered correctly

03 secs
Time Spent

02/26/2020
Last Updated

Explanation

| Classification of multiple endocrine neoplasia | |
|---|---|
| | • **Primary hyperparathyroidism** (parathyroid adenomas or |

| Classification of multiple endocrine neoplasia | |
|---|---|
| **Type 1** | • **Primary hyperparathyroidism** (parathyroid adenomas or hyperplasia)<br>• Pituitary tumors (prolactin, visual defects)<br>• Pancreatic tumors (especially gastrinomas) |
| **Type 2A** | • **Medullary thyroid cancer** (calcitonin)<br>• Pheochromocytoma<br>• Primary hyperparathyroidism (parathyroid hyperplasia) |
| **Type 2B** | • **Medullary thyroid cancer** (calcitonin)<br>• Pheochromocytoma<br>• Mucosal neuromas/marfanoid habitus |

This patient's recurrent peptic ulcer disease, associated with chronic blood loss (iron deficiency) anemia and an elevated gastrin level, is likely due to a gastrin-secreting pancreatic tumor (**Zollinger-Ellison syndrome**). Although most gastrinomas are sporadic, 20%-30% occur in association with **multiple endocrine neoplasia type 1** (MEN1). This autosomal dominant disorder is most often due to mutations of the *MEN1* gene (menin protein) and is characterized by **p**arathyroid adenomas, **p**ituitary tumors, and **p**ancreatic endocrine tumors (the **3 Ps**).

Patients with Zollinger-Ellison syndrome or other pancreatic neuroendocrine tumors should be assessed for symptoms or family history of other MEN1 manifestations. Potential associated conditions include **primary hyperparathyroidism** (eg, hypercalcemia, constipation, **kidney stones**) and pituitary adenomas (eg, headaches, visual field defects).

**(Choices A and C)** Von Hippel-Lindau disease (VHL) is an autosomal dominant disorder characterized by multiple tumors, including hemangioblastomas, pheochromocytoma, and renal cell carcinoma. Plexiform neurofibromas are large aggregates of neuronal cells, supporting cells, and connective tissue that are seen in approximately 30% of patients with neurofibromatosis type 1 (NF1). Although an increased incidence of pancreatic endocrine tumors has been reported in both VHL and NF1, these associations are much less frequent than in MEN1.

**(Choices B and E)** MEN2A consists of medullary thyroid cancer, pheochromocytoma, and primary hyperparathyroidism. MEN2B (also known as MEN3) is associated with medullary thyroid cancer, pheochromocytoma, mucosal neuromas, and a marfanoid habitus. The MEN2 syndromes are

| | |
|---|---|
| | • Mucosal neuromas/marfanoid habitus |

This patient's recurrent peptic ulcer disease, associated with chronic blood loss (iron deficiency) anemia and an elevated gastrin level, is likely due to a gastrin-secreting pancreatic tumor (**Zollinger-Ellison syndrome**). Although most gastrinomas are sporadic, 20%-30% occur in association with **multiple endocrine neoplasia type 1** (MEN1). This autosomal dominant disorder is most often due to mutations of the *MEN1* gene (menin protein) and is characterized by **p**arathyroid adenomas, **p**ituitary tumors, and **p**ancreatic endocrine tumors (the **3 Ps**).

Patients with Zollinger-Ellison syndrome or other pancreatic neuroendocrine tumors should be assessed for symptoms or family history of other MEN1 manifestations. Potential associated conditions include **primary hyperparathyroidism** (eg, hypercalcemia, constipation, **kidney stones**) and pituitary adenomas (eg, headaches, visual field defects).

**(Choices A and C)** Von Hippel-Lindau disease (VHL) is an autosomal dominant disorder characterized by multiple tumors, including hemangioblastomas, pheochromocytoma, and renal cell carcinoma. Plexiform neurofibromas are large aggregates of neuronal cells, supporting cells, and connective tissue that are seen in approximately 30% of patients with neurofibromatosis type 1 (NF1). Although an increased incidence of pancreatic endocrine tumors has been reported in both VHL and NF1, these associations are much less frequent than in MEN1.

**(Choices B and E)** MEN2A consists of medullary thyroid cancer, pheochromocytoma, and primary hyperparathyroidism. MEN2B (also known as MEN3) is associated with medullary thyroid cancer, pheochromocytoma, mucosal neuromas, and a marfanoid habitus. The MEN2 syndromes are not associated with pancreatic endocrine tumors.

**Educational objective:**
Multiple endocrine neoplasia type 1 consists of hyperparathyroidism (eg, hypercalcemia, constipation, kidney stones), pituitary tumors, and pancreatic endocrine tumors (eg, gastrinoma). The genetic defect involves mutations of the *MEN1* gene.

**References**

- Clinical practice guidelines for multiple endocrine neoplasia type 1 (MEN1).

| Pathology | Endocrine, Diabetes & Metabolism | Multiple endocrine neoplasia |
|---|---|---|
| Subject | System | Topic |

Copyright © UWorld. All rights reserved.



1 2 3 4 5 6 7 8 9 10 11 12 13 14 15 16 17 18 19 20 21 22 23 24 25 26 27 28 29 30 31

A 43-year-old woman comes to the office due to episodic confusion, blurred vision, tremors, and sweating. The episodes have increased in intensity in the past few months and seem to occur any time during the day. Her symptoms are relieved by drinking orange juice. During a recent episode, the patient's blood glucose level was 32 mg/dL as measured by her husband's home glucose meter. Medical history includes major depression and irritable bowel syndrome. Laboratory studies performed during the next episode of symptoms show the following results:

| | | |
|---|---|---|
| Glucose | 35 mg/dL | |
| Insulin | 18 μU/mL | (normal: <3 μU/mL) |
| C-peptide | 4.01 ng/mL | (normal: <0.6ng/mL) |

Which of the following is the most likely cause of this patient's symptoms?

A. Alpha cell tumor
B. Insulin administration
C. Somatostatinoma
D. Sulfonylurea use
E. VIP-secreting tumor

Submit

1
2
3
4
5
6
7
8
9
10
11
12
13
14
15
16
17
18
19
20
21
22
23
24
25
26
27
28
29
30
31

A 43-year-old woman comes to the office due to episodic confusion, blurred vision, tremors, and sweating. The episodes have increased in intensity in the past few months and seem to occur any time during the day. Her symptoms are relieved by drinking orange juice. During a recent episode, the patient's blood glucose level was 32 mg/dL as measured by her husband's home glucose meter. Medical history includes major depression and irritable bowel syndrome. Laboratory studies performed during the next episode of symptoms show the following results:

| | | |
|---|---|---|
| Glucose | 35 mg/dL | |
| Insulin | 18 μU/mL | (normal: <3 μU/mL) |
| C-peptide | 4.01 ng/mL | (normal: <0.6ng/mL) |

Which of the following is the most likely cause of this patient's symptoms?

A. Alpha cell tumor (5%)
B. Insulin administration (7%)
C. Somatostatinoma (5%)
✓ D. Sulfonylurea use (72%)
E. VIP-secreting tumor (8%)

Omitted
Correct answer
D

72%
Answered correctly

02 secs
Time Spent

05/04/2020
Last Updated

Explanation

Explanation

| Evaluation of hypoglycemia | | | |
|---|---|---|---|
| | **Serum insulin** | **C-peptide** | **Hypoglycemic drug assay** |
| Exogenous insulin | Normal/increased | **Low** | Negative |
| Oral hypoglycemic agents | Normal/increased | Normal/elevated | **Positive** |
| Insulinoma | Normal/increased | Normal/elevated | Negative |

This patient has symptomatic **hypoglycemia**, confirmed by the **Whipple triad**:

- Symptoms consistent with hypoglycemia (eg, tremor, diaphoresis, confusion)
- Low blood glucose level
- Relief of hypoglycemic symptoms when the blood glucose level is corrected

Insulin is initially synthesized as preproinsulin, after which the signal peptide is removed, yielding proinsulin. In the secretory granules, proinsulin is cleaved into **insulin** and **C-peptide**, which are then released together in equimolar amounts. Normally, as blood glucose falls, endogenous insulin secretion is suppressed, and serum levels of both insulin and C-peptide drop.

Hypoglycemia due to excessive **endogenous insulin production** is associated with **elevated levels of C-peptide**. This can occur due to autonomous insulin-producing tumors (insulinomas) or intake of insulin secretagogues (eg, **sulfonylureas**). Self-induced hypoglycemia via oral hypoglycemics is often a manifestation of a factitious disorder and is typically seen in health care workers and family members of patients with diabetes using these medications (which is likely in this patient whose husband has home glucose-testing supplies). Sulfonylurea abuse can be confirmed by testing the urine or blood for specific hypoglycemic agents.

**(Choice A)** Glucagonoma is a rare tumor of pancreatic alpha cells that secretes excessive amounts of glucagon. This results in hyperglycemia, weight loss, anemia, and necrolytic migratory erythema (a raised, erythematous rash affecting the face, groin, and extremities).

**(Choice B)** Hypoglycemia due to exogenous insulin injection, which does not contain C-peptide, is associated with an elevated serum insulin level but an undetectable C-peptide level.

1
2
3
4
5
6
7
8
9
10
11
12
13
14
15
16
17
18
19
20
21
22
23
24
25
26
27
28
29
30
31

Insulin is initially synthesized as preproinsulin, after which the signal peptide is removed, yielding proinsulin. In the secretory granules, proinsulin is cleaved into **insulin** and **C-peptide**, which are then released together in equimolar amounts. Normally, as blood glucose falls, endogenous insulin secretion is suppressed, and serum levels of both insulin and C-peptide drop.

Hypoglycemia due to excessive **endogenous insulin production** is associated with **elevated levels of C-peptide**. This can occur due to autonomous insulin-producing tumors (insulinomas) or intake of insulin secretagogues (eg, **sulfonylureas**). Self-induced hypoglycemia via oral hypoglycemics is often a manifestation of a factitious disorder and is typically seen in health care workers and family members of patients with diabetes using these medications (which is likely in this patient whose husband has home glucose-testing supplies). Sulfonylurea abuse can be confirmed by testing the urine or blood for specific hypoglycemic agents.

**(Choice A)** Glucagonoma is a rare tumor of pancreatic alpha cells that secretes excessive amounts of glucagon. This results in hyperglycemia, weight loss, anemia, and necrolytic migratory erythema (a raised, erythematous rash affecting the face, groin, and extremities).

**(Choice B)** Hypoglycemia due to exogenous insulin injection, which does not contain C-peptide, is associated with an elevated serum insulin level but an undetectable C-peptide level.

**(Choice C)** Somatostatinoma is a rare tumor of pancreatic delta cells that is associated with hyperglycemia, weight loss, abdominal pain, steatorrhea, cholelithiasis, and hypochlorhydria. These manifestations are due to somatostatin-induced inhibition of insulin, gastrin, secretin, and cholecystokinin secretion, as well as decreased gastrointestinal motility.

**(Choice E)** VIPomas are non–beta cell pancreatic islet cell tumors that hypersecrete vasoactive intestinal polypeptide (VIP). Features include watery diarrhea, hypokalemia, and impaired gastric acid secretion.

**Educational objective:**
Hypoglycemia is characterized by tremor, diaphoresis, and confusion in association with a low blood glucose level and resolution of symptoms when the blood glucose level is corrected. Hypoglycemia with elevated insulin and low C-peptide levels suggests exogenous insulin injection, whereas elevated C-peptide suggests an insulin secretagogue or insulin-secreting tumor.

**References**

- Approach to the patient with spontaneous hypoglycemia.

1
2
3
4
5
6
7
8
9
10
11
12
13
14
15
16
17
18
19
20
21
22
23
24
25
26
27
28
29
30
31

Relief of hypoglycemic symptoms when the blood glucose level is corrected

## Exhibit Display

### Insulin synthesis and secretion

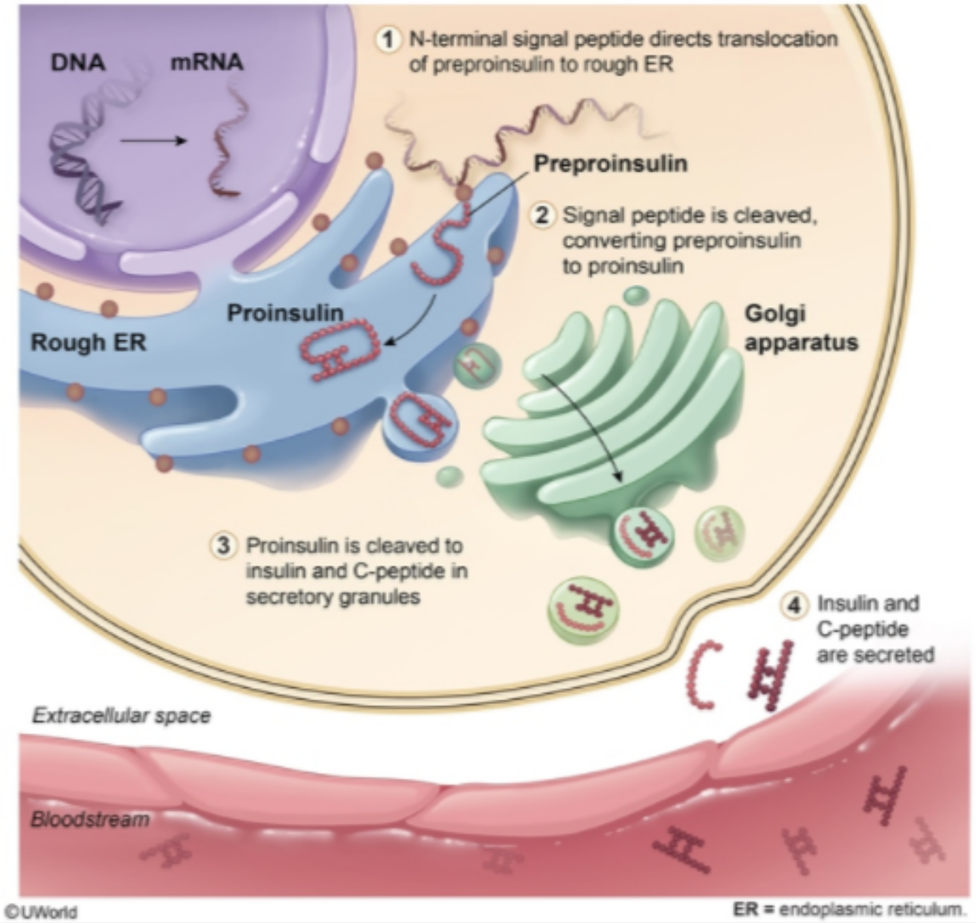


Zoom In | Zoom Out | Reset | Add To New Card | Existing Card

1
2
3
4
5
6
7
8
9
10
11
12
13
14
15
16
17
18
19
20
21
22
23
24
25
26
27
28
29
30
31

A 19-year-old woman comes to the office for evaluation of amenorrhea. Onset of menarche was at age 12, and the patient then had menses regularly every 25-28 days. However, for the last year her menstrual periods have been irregular, and her last period was 3 months ago. The patient has no significant past medical history, eats mainly fruits and vegetables, and exercises regularly at a local gym. She does not use tobacco or alcohol. On further questioning, the patient expresses concern about being overweight and asks for suggestions on cutting down her caloric intake. On physical examination, BMI is 18 kg/m$^2$. The patient is thin and has dry skin covered by fine, downy hair. A pregnancy test is negative. Which of the following patterns of serum hormone levels is most likely in this patient?

| | LH | FSH | Estradiol |
|---|---|---|---|
| A. | Increased | Increased | Decreased |
| B. | Increased | Decreased | Decreased |
| C. | Decreased | Normal | Normal |
| D. | Decreased | Decreased | Decreased |
| E. | Normal | Normal | Decreased |

Submit

A 19-year-old woman comes to the office for evaluation of amenorrhea. Onset of menarche was at age 12, and the patient then had menses regularly every 25-28 days. However, for the last year her menstrual periods have been irregular, and her last period was 3 months ago. The patient has no significant past medical history, eats mainly fruits and vegetables, and exercises regularly at a local gym. She does not use tobacco or alcohol. On further questioning, the patient expresses concern about being overweight and asks for suggestions on cutting down her caloric intake. On physical examination, BMI is 18 kg/m$^2$. The patient is thin and has dry skin covered by fine, downy hair. A pregnancy test is negative. Which of the following patterns of serum hormone levels is most likely in this patient?

| | LH | FSH | Estradiol |
|---|---|---|---|
| A. (16%) | Increased | Increased | Decreased |
| B. (4%) | Increased | Decreased | Decreased |
| C. (2%) | Decreased | Normal | Normal |
| ✓ D. (74%) | Decreased | Decreased | Decreased |
| E. (2%) | Normal | Normal | Decreased |

Omitted
Correct answer
D

74%
Answered correctly

02 secs
Time Spent

05/20/2020
Last Updated

Explanation

1
2
3
4
5
6
7
8
9
10
11
12
13
14
15
16
17
18
19
20
21
22
23
24
25
26
27
28
29
30
31

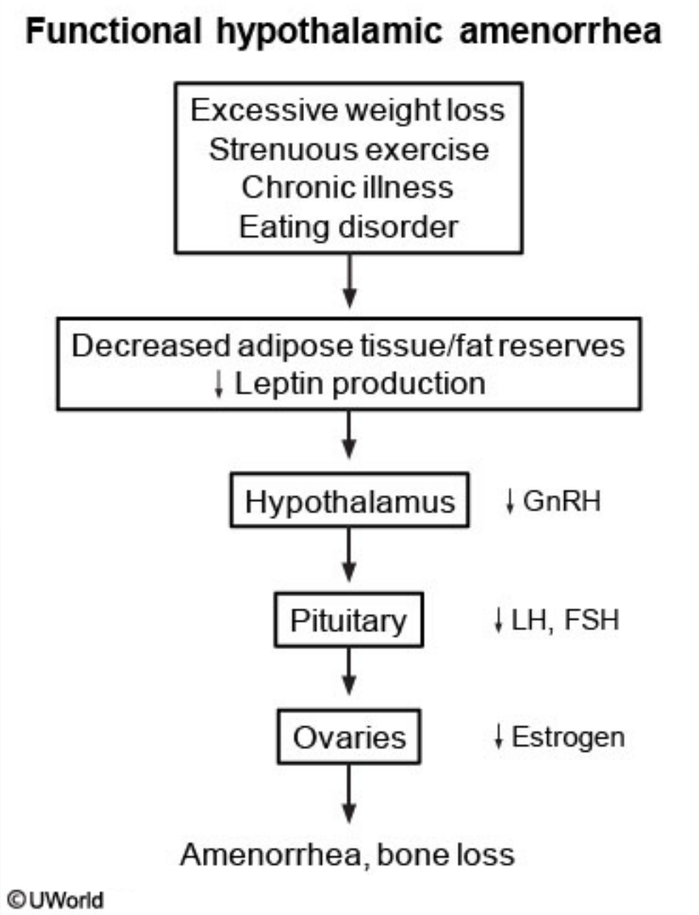


Amenorrhea can be categorized as primary (failure of menarche by age 15) or secondary (cessation of menstruation in premenopausal women who have previously had menses). Secondary amenorrhea can be due to hypothalamic, pituitary, ovarian, uterine, or other endocrine (eg, thyroid) disorders.

This patient's distorted body image, restricted diet, exercise regimen, and physical examination findings (dry skin, lanugo hair) suggest anorexia nervosa with **functional hypothalamic amenorrhea** (FHA). The underlying pathophysiology of FHA appears to involve reduced circulating leptin levels as a result of diminished adipose tissue stores. The decrease in leptin inhibits pulsatile **gonadotropin-releasing hormone (GnRH)** release

1
2
3
4
5
6
7
8
9
10
11
12
13
14
15
16
17
18
19
20
21
22
23
24
25
26
27
28
29
30
31

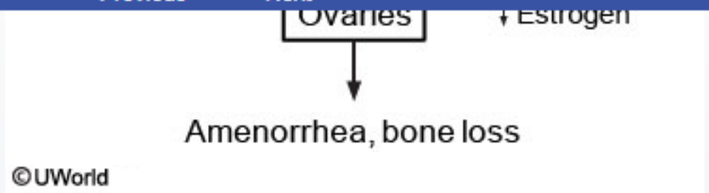


Amenorrhea can be categorized as primary (failure of menarche by age 15) or secondary (cessation of menstruation in premenopausal women who have previously had menses). Secondary amenorrhea can be due to hypothalamic, pituitary, ovarian, uterine, or other endocrine (eg, thyroid) disorders.

This patient's distorted body image, restricted diet, exercise regimen, and physical examination findings (dry skin, lanugo hair) suggest anorexia nervosa with **functional hypothalamic amenorrhea** (FHA). The underlying pathophysiology of FHA appears to involve reduced circulating leptin levels as a result of diminished adipose tissue stores. The decrease in leptin inhibits pulsatile **gonadotropin-releasing hormone (GnRH)** release from the hypothalamus, causing decreased pituitary **LH and FSH** secretion, low circulating **estrogen** levels, and amenorrhea.

In addition to anorexia, FHA can also occur when caloric expenditure is out of proportion to intake, as in thin female athletes (eg, distance runners, dancers) or patients with chronic illness. Potential complications of FHA in young women include reduced peak bone mass, which may lead to early-onset osteoporosis.

**Educational objective:**
Distorted body image, inadequate diet, dry skin, and lanugo hair in a female suggest anorexia nervosa. Anorexic females commonly have impaired gonadotropin-releasing hormone release from the hypothalamus, leading to low levels of LH, FSH, and estrogen (functional hypothalamic amenorrhea).

**References**

- Functional hypothalamic amenorrhea: current view on neuroendocrine aberrations.

| Pathology | Endocrine, Diabetes & Metabolism | Anorexia nervosa |
|---|---|---|
| Subject | System | Topic |

Copyright © UWorld. All rights reserved.